

# Erectile Dysfunction Revealing A Primary Empty Sella: A Case Report And Literature Review

Abderrahman Tadlaoui<sup>1, &</sup>, Mohamed Malad<sup>1</sup>, Mamadou Togo<sup>1</sup>,  
Ahmed Anas Guerboub<sup>1</sup>

<sup>1</sup>departement Of Endocrinology, Mohamed V Military Training Hospital, Rabat-Morocco

---

## Abstract

Primary empty sella or primary intrasellar arachnoidocele is a relatively rare condition. It occurs in a healthy pituitary gland which flattens against the sellar floor, giving the appearance of an empty sella turcica. Diagnosis is based on magnetic resonance imaging of the hypothalamic-pituitary region. Although frequently asymptomatic, it may manifest as a tumour syndrome or endocrine dysfunction. It is therefore essential to evaluate the various pituitary axes at the time of diagnosis and during follow-up to detect any new endocrine disorders that may appear during the course of the disease. This article illustrates the case of a patient with erectile dysfunction who was diagnosed with a primary empty sella.

**Keywords:** Primary empty sella, erectile dysfunction, central hypogonadism, adrenal insufficiency, case repor

---

Date of Submission: 07-05-2024

Date of Acceptance: 17-05-2024

---

## I. Introduction

Primary empty sella or primary intrasellar arachnoidocele is a relatively rare condition, particularly in men, but its incidence has increased in recent decades due to the performance and increased use of magnetic resonance neuroimaging [1-2]. It occurs in a normal pituitary gland, which flattens to varying degrees under the effect of the mass of cerebrospinal fluid [3], apart from trauma, radiotherapy or pharmacological or surgical treatment of the hypothalamo-hypophyseal region, resulting in an empty sella turcica appearance.

### Clinical case

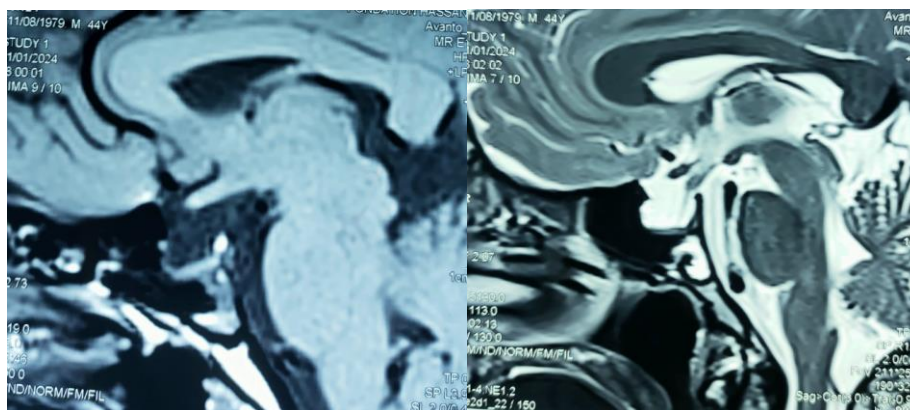
We report the case of a 44-year-old patient with no previous pathological history. He had been suffering from erectile dysfunction for 3 years. The history revealed a decrease in shaving frequency, a drop in libido and an absence of morning erections. The somatic examination was without abnormalities.

A testosterone level was taken, which fell to 0.05 ng/ml, supplemented by gonadotropin levels, which were low, indicating hypogonadotropic hypogonadism (LH<0.12 IU/l-FSH=0.27 mU/ml). The rest of the hypophysiogram showed thyroid insufficiency (TSH=0.43 uU/ml, FT4=0.60 ng/dl), and moderate hyperprolactinaemia (33 ng/ml), while cortisolaemia was comfortable and IGF1 was within the normal range for age. The metabolic panel showed hypercholesterolaemia (total cholesterol: 2.38 g/l, LDL-C: 1.65 g/l).

The hypothalamic-pituitary MRI showed a harmonious intrasellar arachnoidocele pressing the pituitary parenchyma against the sellar floor (Figure 1). An assessment of the repercussions of hypogonadism revealed osteopenia. Thyroid hormone and testosterone replacement therapy (after a pre-therapeutic work-up with no abnormalities) was initiated.

During the follow-up (3 months later), the patient showed asthenia that increased during the day, associated with malaise occurring when moving to a standing position. On clinical examination, the patient was pale and had orthostatic hypotension. Biological tests revealed a natraemia at the low limit of normal (135 mmol/l) and a low cortisol level of 43 ng/l, supplemented by adrenocorticotrophic hormone (ACTH), which was also low at 9 pg/ml, indicating corticotropic insufficiency. The patient was treated with hydrocortisone 15 mg daily in two doses, with therapeutic education dedicated to patients with adrenal insufficiency.

The outcome was favourable, with normalisation of erectile function and disappearance of malaise and asthenia.



**Figure 1: Sagittal section in T1 (Image A) and T2 (Image B) showing the intrasellar arachnoidocele in our patient.**

## II. Discussion

Primary empty sella is a herniation of the subarachnoid space through the sellar diaphragm, pushing the pituitary gland against the floor of the sella turcica (ST), either partially (<50% cerebrospinal fluid in the ST) or completely (>50% cerebrospinal fluid in the ST) [4].

The etiopathogenesis of this condition is not clearly elucidated, but it may be due to incompetence or total or partial absence of the sellar diaphragm. Also, chronic intracranial hypertension and the variation in pituitary volume from hypertrophy that may occur during pregnancy and breastfeeding to involution during the menopause may create a space within the ST allowing the development of intrasellar subarachnoid hernia [5].

Primary empty sella is often asymptomatic and may be discovered incidentally, but may manifest as headache, visual disturbances, neurological disorders or endocrine dysfunction [4-5]. In our case, erectile dysfunction secondary to central hypogonadism was the main clinical manifestation.

According to the studies, pituitary involvement varies widely, ranging from 19 to 68% of cases, with somatotrophic insufficiency and central hypogonadism being the most common, followed by corticotrophic and thyrotrophic insufficiency. Hyperprolactinaemia comes last (median prolactinaemia level 31 ng/ml), after diabetes insipidus, which remains very rare [5-6].

Primary empty sella has been associated with an increased cardiovascular risk, irrespective of body mass index. This is thought to be due to dyslipidaemia and dysglycaemia caused by secondary hypothyroidism, as well as hypogonadism [7]. Both of these conditions were present in our patient at the time of diagnosis. Correcting them would help reduce this cardiovascular risk.

It is also important to understand that this disease can spread to other pituitary axes that were not affected at the time of diagnosis, but this appears to be uncommon (3% of cases). It should also be emphasised that it is possible to recover from one or more pituitary insufficiencies, as demonstrated by the multicenter cohort research carried out by Giulia and colleagues [6].

## III. Conclusion

The diagnosis of a primary empty sella requires careful exploration of the various pituitary axes, as well as regular monitoring to detect the appearance of any pituitary insufficiency not initially considered at the time of diagnosis. Particular attention should also be paid to the increased cardiovascular risk associated with this pathological situation.

### Competing interests

The authors declare no competing interest.

### Authors' contributions

All the authors contributed to this work.

### Tables and figures

Figure 1: Sagittal section in T1 (Image A) and T2 (Image B) showing the intrasellar arachnoidocele in our patient.

### References :

- [1] Debnath J, Ravkumar R, Sharma V, Et Al. 'Empty Sella' On Routine Mri Studies : An Incidental Finding Or Otherwise ? Med J Armed Forces India. 2016;72:33-37.

- [2] Foresti M, Guidali A, Susanna P. (Primary Empty Sella. Incidence In 500 Asymptomatic Subjects Examined With Magnetic Resonance). *La Radiol Med* (1991) 81:803–7.
- [3] Sage Mr, Blumbergs Pc. Primary Empty Sella Turcica: A Radiological-Anatomical Correlation. *Australas Radiol* (2000) 44:341–8.
- [4] Miljic D, Pekic S, Popovic V. Empty Sella. *Endotext* [Internet]. Mdtex.Com, Inc.; South Dartmouth (Ma): Aug 1, 2021.
- [5] Chiloiro S, Giampietro A, Bianchi A, Et Al. Diagnosis Of Endocrine Disease: Primary Empty Sella: A Comprehensive Review. *Eur J Endocrinol*. 2017 Dec;177(6):R275-R285.
- [6] Carosi G, Brunetti A, Mangone A, Et L. A Multicenter Cohort Study In Patients With Primary Empty Sella: Hormonal And Neuroradiological Features Over A Long Follow-Up. *Front Endocrinol (Lausanne)*. 2022;13:925378.
- [7] Colao A, Cotta Or, Ferone D, Et Al. Role Of Pituitary Dysfunction On Cardiovascular Risk In Primary Empty Sella Patients. *Clin Endocrinol* (2013) 79:211–6.