

# Anesthesia For Uncorrected Tetralogy Of Fallot For Major Surgery? A Case Report

K. Bendjoudi, K. Guebouli, N. Ouguenoune, K. Meskouri

Department Of Anesthesia, Mustapha University Hospital, Algiers, Algeria

Department Of Cardiovascular Thoracic Surgery And Organ Transplantation, Mustapha University Hospital, Algiers, Algeria

---

## **Abstract:**

### **Introduction:**

Congenital cyanogenic heart disease (CCHD) accounts for 10% of all heart malformations, with Tetralogy of Fallot (TOF) representing 82.7%, characterized by a right-to-left shunt. Anesthesia before surgical correction of the shunt carries significant risks. We report the anesthetic management of uncorrected cyanogenic heart disease in a 4-year-old girl undergoing thoracic surgery.

### **Material/Patient:**

The 4-year-old child, M. Soumia, with TOF, was referred from Bousmail Hospital to the thoracic surgery department in 2022 for management of a left para-pharyngeal cystic lymphangioma. Preoperatively, the child experienced hypercyanotic spells due to crying, necessitating immediate intervention. The most important monitoring included SpO<sub>2</sub> and arterial blood pressure. Anesthetic agent selection was based on their hemodynamic properties on systemic vascular resistance. Anesthesia maintenance aimed to maintain normothermia and correct anemia.

### **Results - Discussion:**

After anesthetic induction, the child experienced pulmonary arterial hypertension crisis, for which norepinephrine was used. Vascular filling used 9‰ saline solution. Postoperative complications included esophageal fistula, pneumonia, convulsions, and renal dysfunction. In patients with CCHD, the risk of mortality is 5 times higher for major surgery compared to minor surgery.

### **Conclusion:**

Perioperative management of uncorrected TOF for major surgery is challenging, requiring advanced technical resources and high human competence. Specific perioperative complications encountered include rhythm disturbances, hypoxia, pulmonary arterial hypertension, heart failure, and infective endocarditis.

**Keywords:** congenital heart diseases, anesthesia, pulmonary arterial hypertension crisis.

---

Date of Submission: 29-04-2024

Date of Acceptance: 09-05-2024

---

## **I. Introduction:**

Tetralogy of Fallot is the most common cyanotic congenital heart disease, accounting for approximately 82.2% of all cyanotic congenital heart diseases. Its incidence is estimated to be between 0.4 and 0.8 births per 1000. Tetralogy of Fallot is characterized by four features: a large ventricular septal defect, obstruction of the right ventricular outflow tract with pulmonary valve stenosis, right ventricular hypertrophy, and an overriding aorta that straddles both ventricles (above the ventricular septal defect).

The anesthetic management of patients with congenital heart disease can be a source of concern, particularly in non-cardiac surgeries. It is essential to understand the types of heart disease, their potential long-term sequelae, and their impact on anesthetic risk. The main long-term sequelae of major perioperative risk include myocardial dysfunction (including heart failure and cardiomyopathy), arrhythmia (including permanent pacing), cyanosis, and pulmonary hypertension.<sup>1,2,3</sup>

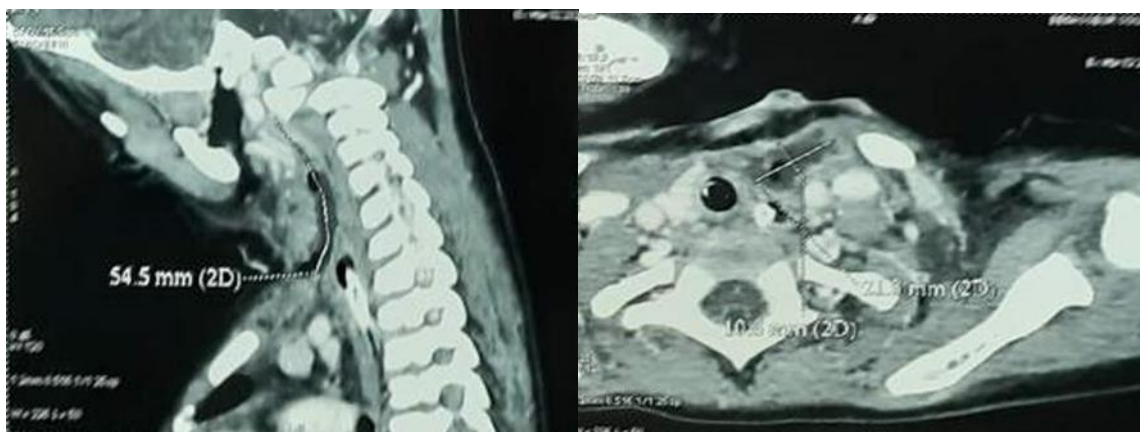
This tutorial is based on the review article by Raviraj et al., using a case-based discussion to demonstrate how establishing a physiological framework and risk assessment are fundamental to the anesthetic management of a child with congenital heart disease (CHD) presenting for non-cardiac surgery.<sup>4,5</sup>

## **Observation:**

The child, Miss Soumia, aged 4 years, diagnosed with tetralogy of Fallot, was referred from Bousmail Hospital specializing in pediatric cardiac surgery to our thoracic surgery department at CHU Mustapha for the management of a para-pharyngeal cystic lymphangioma (Fig 1). Prior to the correction of her cardiac condition, the cyst presents a contraindication to cardiopulmonary bypass (CPB). Observation:

---

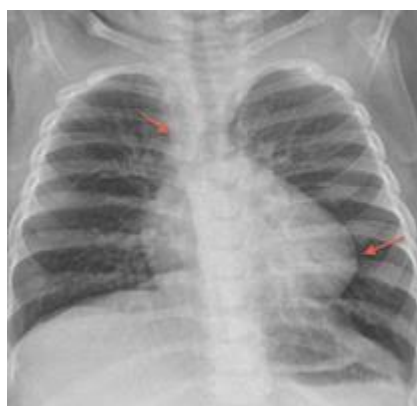The child, Miss Soumia, aged 4 years, diagnosed with Tetralogy of Fallot, was referred from Bousmail Hospital, specialized in pediatric cardiac surgery, to our thoracic surgery department at Mustapha University Hospital for management of a para-pharyngeal cystic lymphangioma (Fig 1). Prior to correction of her cardiac condition, the cyst posed a contraindication to cardiopulmonary bypass(CPB).



**Fig( 1) Cervical CT scan demonstrating the left para-pharyngeal cystic lymphangioma collection.**

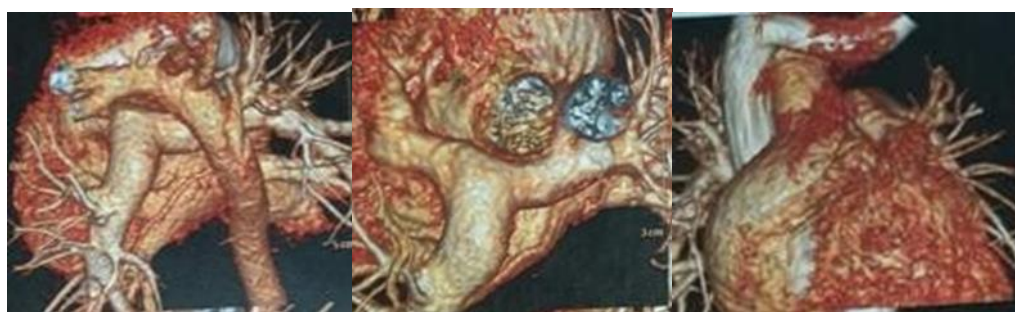Clinical examination reveals: Cyanosis with ambient air SaO<sub>2</sub> of 84% Pronounced systolic murmur at the upper left sternal border with a single second heart sound (S<sub>2</sub>) Sinus tachycardia on ECG Chest X-ray showing a boot-shaped heart (Fig 2) Cardiacultrasound reveals the following cardiac malformations:

- Large, subaortic, and solitary conalventricular septal defect (VSD)
- Tight pulmonary valve and subvalvularstenosis
- Aorta overriding the ventricular septum
- Right ventricular hypertrophy (RVH)
- Normal coronary arteries, no pulmonarytrunk hypoplasia



**Fig 2 : Preoperative Chest X-Ray.**

coronary scanner (Fig 3) Preoperative chest X-ray also shows the cardiac malformation.

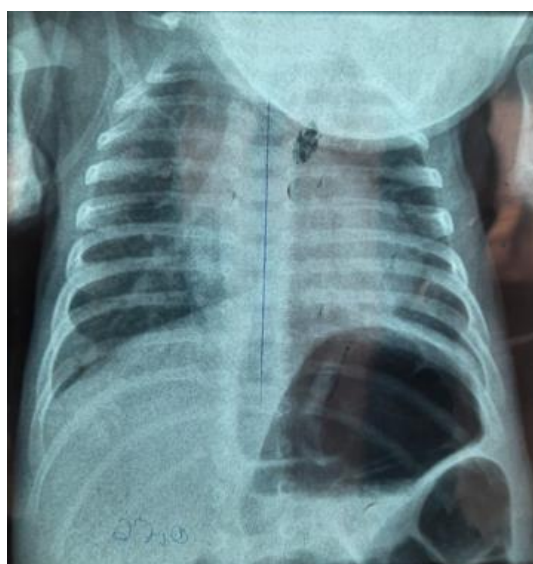

**Fig 3: Coronary Scanner**

Preoperatively, the child experienced hypercyanotic spells due to crying, necessitating immediate intervention. Therefore, the choice of anesthetic technique was guided by the pathology and the patient's condition, as well as the surgery for which she was referred. The most important monitoring parameter was oxygen saturation (SpO<sub>2</sub>). The selection of anesthetic agents was based on their hemodynamic properties on systemic vascular resistance. Anesthesia maintenance aimed to maintain normothermia and correct anemia.

## **II. Results:**

Following anesthetic induction with Midazolam, Sufentanil, and Rocuronium, and invasive arterial pressure monitoring, the child experienced pulmonary hypertensive crisis requiring intraoperative resuscitation. Norepinephrine was used as the vasopressor. Vascular filling was achieved with 9‰ saline solution. Particularly, efforts were made to avoid pulmonary hyperperfusion at induction of general anesthesia induced by 100% preoxygenation and hyperventilation, while controlling the shunt by increasing systemic vascular resistance and reducing pulmonary vascular resistance. The average duration of the intervention was 1 hour and 45 minutes, with awakening on the operating table and the child extubated while asleep. Postoperatively, multimodal analgesia consisted of Morphine and Paracetamol. Postoperative complications included hypercyanotic spells with convulsions, requiring reintubation, and pneumonia (Fig 4) due to esotracheal fistula.



**(Fig 4) Postoperative pneumonia.**

The child was extubated on the fifth day, once the pulmonary infection was controlled. The nasogastric feeding tube remained in place for three weeks until the closure of the fistula, which was monitored by esophagogastroduodenoscopy (EGD). At one month, the child's progress was good, and she was discharged with a referral letter for cardiac surgery. She underwent corrective surgery for her heart condition two months after leaving our service and is alive to this day.

## **III. Discussion:**

Hypercyanotic spells are serious complications associated with high mortality rates. In this case, the management of these spells aimed to prevent cardiac decompensation<sup>1</sup>.

This anomaly alone leads to the four characteristic features of the malformation<sup>2</sup>:

1. Obstruction of the right ventricular outflow tract (RVOT), often muscular in nature and sometimes associated with valvular obstruction or obstruction in the pulmonary branches;
2. Ventricular septal defect (VSD) due to malalignment;
3. Aorta overriding the ventricular septum (AO) with the aortic orifice "riding" over the VSD;
4. Right ventricular hypertrophy (RVH).

Increased pulmonary blood flow leads to heart failure, pulmonary congestion, and respiratory infections.

The risk of mortality in patients with congenital heart disease is 5 times higher for major surgeries than for minor ones<sup>2</sup>. The presence of any of the following elements places our patient's surgery in the category of major surgery:

Intrathoracic surgery:

- Intra-abdominal surgery
- Vascular reconstructive surgery
- Orthopedic and neurosurgical interventions, with a significant risk of bleeding.
- Emergency surgery

Patients with congenital heart disease presenting with sequelae such as heart failure, arrhythmia, cyanosis, and pulmonary hypertension have a high perioperative risk. In patients with congenital heart disease<sup>4</sup>, the risk of mortality for major surgery is 5 times higher compared to minor surgery. Available research does not recommend a specific technique or medication. When designing the anesthesia plan, proceed with your preferred anesthesia technique for the specific procedure. Consider how this technique would affect the hemodynamic goals of your patient. The patient should be able to maintain adequate cardiac output and oxygen delivery according to this plan<sup>5,6,7</sup>.

Preoperative assessment of patients with heart disease should begin with physiological classification and risk evaluation, as outlined above. Insufficient cardiac output during the intervention is best treated initially with volume expansion, vasoconstrictors, and inotropes<sup>1,2</sup>.

#### **IV. Conclusion:**

The perioperative management of uncorrected Tetralogy of Fallot for major surgery is very challenging, requiring advanced technical capabilities and high human competence. The specific perioperative complications encountered are primarily rhythm disturbances, hypoxia, pulmonary hypertension, heart failure, and infective endocarditis.

#### **Bibliography:**

- [1] Brown MI, Dinardo Ja, Nasr Vg. Anesthesia In Pediatric Patients With Congenital Heart Disease Undergoing Non-Cardiac Surgery: Defining The Risk. *Journal Of Cardiothoracic And Vascular Anesthesia*. 2020; 34:470-8.
- [2] White Mc, Peyton Jm. Anesthetic Management Of Children With Congenital Heart Disease For Non-Cardiac Surgery. *Continuing Education In Anaesthesia, Critical Care & Pain*. 2012;12:17-22.
- [3] Miller-Hance Wc. Chapter 23: Anesthesia For Non-Cardiac Surgery In Children With Congenital Heart Disease. In: Cote Cj, Lerman J, Anderson Bj, Eds. *A Practice Of Anesthesia For Infants And Children*. 6th Ed. Elsevier; 2019:534-59.
- [4] Beerman Lb, Md, Children's Hospital Of Pittsburgh Of Upmc, University Of Pittsburgh School Of Medicine, December 2020, High Mortality.
- [5] European Society Of Cardiology, Vahanian A, Baumgartner H, Bax J, Butchart E, Dion R, Et Al. Guidelines On The Management Of Valvular Heart Disease. The Task Force.
- [6] Mcewan A, Rolo Vl. Chapter 17: Anesthesia For Children Undergoing Cardiac Surgery. In: Cote Cj, Lerman J, Anderson Bj, Eds. *A Practice Of Anesthesia For Infants And Children*. 6th Ed. Elsevier; 2019:393-423.
- [7] Walker I. Anesthesia For Non-Cardiac Surgery In Children With Congenital Heart Disease. *Update In Anaesthesia*. 2008; Link.
- [8] Miller-Hance Wc, Gertler R. Chapter 16: Fundamentals Of Cardiology. In: Cote Cj, Lerman J, Anderson Bj, Eds. *A Practice Of Anesthesia For Infants And Children*. 6th Ed. Elsevier; 2019:355-92.