

Rare Encounter: Surgical Management Of A Large Mesenteric Cyst: A Clinical Acumen

Dr Mahesh Gupta¹, Dr Roshin Mathew Philip², Dr R Vinod Kumar³, Dr Nitesh Kumar⁴, Dr Pooja Gupta⁵, Dr Anu Susan Philip⁶

¹MS, DMAS, FMAS, FIAGES, Professor and Head Department of General Surgery

Rama Medical College Hospital and Research Centre, Kanpur, U.P. Pin:209217

²MBBS, Post Graduate Department of General Surgery

Rama Medical College Hospital and Research Centre, Kanpur, U.P. Pin:209217

³MBBS, Post Graduate Department of General Surgery

Rama Medical College Hospital and Research Centre, Kanpur, U.P. Pin:209217

⁴MBBS, Post Graduate Department of General Surgery

Rama Medical College Hospital and Research Centre, Kanpur, U.P. Pin:209217

⁵MD MEDICINE, SGL Charitable Hospital Jalandhar

⁶MBBS, Amala Medical College Hospital, Thrissur, Kerala.

Corresponding Author: Dr Roshin Mathew Philip

Abstract

Mesenteric cyst being one of the rare forms of abdominal cyst are usually asymptomatic and occur at a mean age of 25 years. Ultrasonography of the abdomen helps in the diagnosis and complete excision is the treatment of choice. This case report discusses a case of a large mesenteric cyst that was successfully managed by laparotomy and complete excision of the cyst.

Keywords: Mesenteric cyst, Enterogenous, Chylolympatic, Enucleation.

Date of Submission: 27-04-2024

Date of Acceptance: 07-05-2024

I. Introduction

Mesenteric cyst are rare tumors that occur both in men and women with a mean age of presentation at 25 years and an incidence of 1/100,000-250,000 [1]. They are usually asymptomatic and detected incidentally on clinical examination or imaging. Most of the patients present with abdominal pain, nausea, vomiting, anorexia, and changes in bowel habits [2]. Laparoscopy or laparotomy is done to deal with these tumors and enucleation or excision of a part of the gut is the preferred method for this pathology [3]. We report one such case of a large mesenteric cyst presenting in a male who was surgically managed by complete enucleation.

II. Case Report

28 yrs male presented with palpable intrabdominal mass in the right lumbar region extending to periumbilical and right iliac fossa. It was 15x12 cm in size, soft in consistency, and freely mobile from side to side (Figure 1). He had a history of abdominal tuberculosis 6 months back and was on treatment for the same. Ultrasonography of the whole abdomen demonstrated a large well-defined cystic lesion in the lower abdomen

with multiple thin septations and dense internal echoes. CT scan of the abdomen demonstrated a large thin-walled unilocular cystic lesion of size 9.0 (AP)x12.8 (TR)x15.4(CC) cm in the right lower abdomen at the level of L3 to L5 vertebra (Figure-2). The lesion was abutting the right psoas muscle and right common iliac artery with maintained fat plane posteriorly and with mild bulge and displacing the bowel loops in the right lower quadrant anteriorly. Blood parameters were within normal range. Considering the size and the extend of the mass laparotomy was planned followed by complete excision of the cyst for which he consented. The patient underwent enucleation of the mesenteric cyst under general anesthesia (Figure 3,4). Histopathological examination revealed a single large well-circumscribed cystic mass with a congested external surface and the lining epithelium of the cyst wall showed fibrous tissue densely infiltrated by chronic inflammatory cells which was consistent with mesenteric cyst.

III. Discussion

Mesenteric cysts are rare abdominal tumors that are classified as chyle-lymphatic, simple (mesothelial), enterogenous, urogenital remnant, and dermoid (teratomatous cyst) [4]. These usually originate in the small bowel mesentery (60%), in the large bowel mesentery(24%), and in the retroperitoneum(14.5%) [6]. The cyst may present with abdominal pain, nausea, vomiting, anorexia, and changes in bowel habits. However, mostly they are asymptomatic and detected incidentally on physical examination or imaging. These cysts are benign and sometimes lead to complications such as intestinal obstruction, volvulus, torsion, or even hemorrhagic shock secondary to bleeding or rupture [2], in our study, the patient presented with palpable intrabdominal mass which was asymptomatic. Ultrasonography can be used as a primary imaging modality. CT and MRI can be done for anatomical localization and guidance for cyst aspiration. Enucleation of the cyst in case of independent blood supply irrespective of size is successful whereas enterogenous cyst requires bowel resection and anastomosis [5]. A retroperitoneal mesenteric cyst calls for a complete excision rather than partial or simple drainage as this may increase the probability of recurrence [6].

IV. Legends

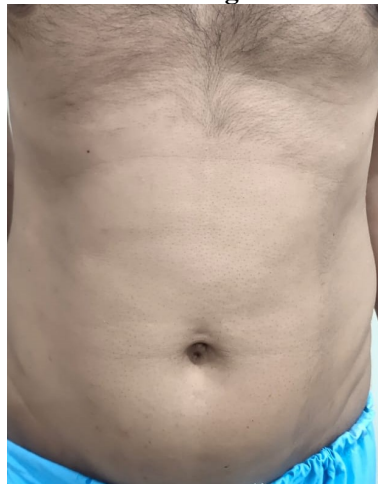

Figure-1 Pre-operative picture showing large mesenteric cyst

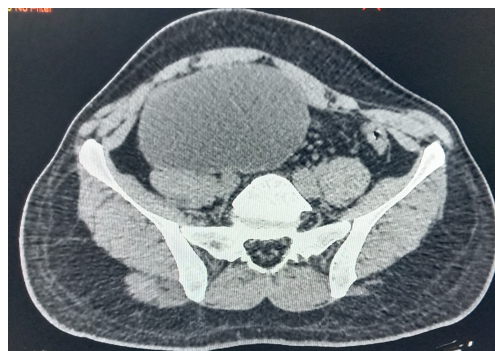


Figure-2 CT Abdomen showing the presence of mesenteric cyst

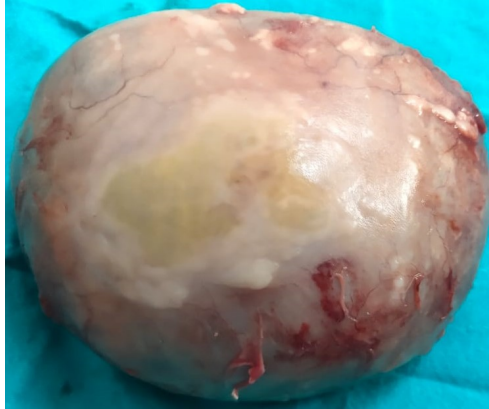


Figure-3 Intra-operative picture of anterior surface of mesenteric cyst

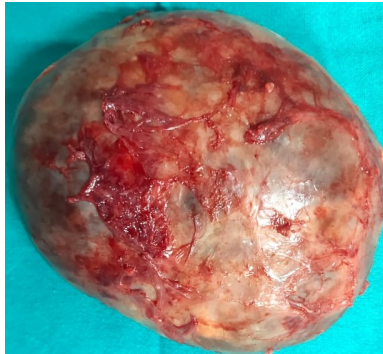


Figure-4 Intra-operative picture of posterior surface of mesenteric cyst

References

- [1] Ferreira Mav, Monteiro C, Monteiro C Et Al. A Large Mesenteric Cyst. *Int J Case Rep Images*. 2018;9:100974z01mf2018.
- [2] Asgharnia M, Rahbar T, Dalil Heirati Sf. Mesenteric Cysts: A Rare Case. *Clin J Obstet Gynecol*. 2019;2: 067-070.
- [3] Casarotto A, Cerofolini A, Denitto F Et Al. Cisti Mesenteriale: Case Report E Revisione Della Letteratura [Mesenteric Cyst: Case Report And Review Of The Literature].2010 May;31(5):239-42.
- [4] Abiyere Oh, Rosiji Ob, Osho Ai Et Al. Huge Mesenteric Cyst :Case Report. *Int J Surg Res Pract* 8:128.
- [5] Blooq Ay, Hussain S S, Elmy M. Giant Chylolymphatic Mesenteric Cyst And Its Successful Enucleation : A Case Report. *International Journal Of Surgery Case Reports*.2014;5(8):469-470.
- [6] Kurtz Rj, Heimann Tm, Holt J Et Al. Mesenteric And Retroperitoneal Cysts. *Ann Surg*. 1986;203(1):109-112.