

# A Rare Recurrence Of Adenoid Ameloblastoma In Autogenous Iliac Bone Graft After 3 Years: Case Report

Col (Dr.) Vivek Saxena<sup>1</sup>  
MDS, DNB, Prof, Sr Spl,

Lt Col (Dr.) V Gopalakrishnan<sup>2</sup>  
MDS, Asst Prof, Cl Spl

Lt Col (Dr.) Rangarajan H<sup>3</sup>  
MDS, Asst Prof, Cl Spl

Maj (Dr.) Hitendra Nath Deva<sup>4</sup>  
BDS, Pg Resident

Lt Col (Dr.) Aditya Ashok Mahendraker<sup>5</sup>  
BDS, Pg Resident

(MDC Ahmednagar, Maharashtra)<sup>1</sup>

(Department Of Oral & Maxillofacial Surgery, Army Dental Centre Research & Referral, New Delhi-110010)<sup>2,3,4,5</sup>

---

## Abstract

**Introduction:** Ameloblastoma ranks as the second most prevalent neoplasm arising from odontogenic epithelial tissues within the maxillofacial region, marked by a notable propensity for local recurrence following excision. Recurrences often manifest within the mandible, soft tissues, and even in various reconstructive materials employed. However, instances of ameloblastoma recurrence within autogenous iliac bone grafts remain scarcely documented in the literature.

**Case report:** This case report delineates a unique instance of recurrent adenoid ameloblastoma exhibiting clinical and radiographic signs of recurrence within an autogenous iliac bone graft, three years subsequent to the initial surgical intervention (segmental resection of the mandible after the bony reconstruction utilizing a right iliac crest bone graft). A comprehensive review of existing literature underscores the novelty of this case, as it represents the first reported recurrence of adenoid ameloblastoma within an iliac bone graft.

**Discussion:** The significance of extensive bone resection coupled with adjacent soft tissue excision and vigilant long-term follow-up cannot be overstated. Notably, recurrences predominantly emanate from soft tissues, particularly the adjacent periosteum, underscoring the imperative for meticulous surgical technique and thorough surveillance.

The recurrence of ameloblastoma post-adequate resection poses a formidable surgical challenge, necessitating a nuanced and comprehensive management approach. This case underscores the critical importance of meticulous surgical planning, vigilant postoperative monitoring, and the imperative for ongoing research to refine therapeutic strategies and optimize patient outcomes in the face of this intricate pathology.

**Keywords** - Ameloblastoma, Recurrence, Autograft, Iliac graft, Bone graft, Adenoid ameloblastoma

---

Date of Submission: 24-04-2024

Date of Acceptance: 04-05-2024

---

## I. Introduction

Ameloblastoma stands out as a prevalent benign odontogenic tumor originating from epithelial tissues within the oral cavity. Its inception traces back to its recognition by Cusack in 1827, with subsequent nomenclature refinement by Ivy and Churchill in 1930<sup>1</sup>. The World Health Organization (WHO), in its 2005 classification, delineated benign ameloblastoma into four distinct types: solid or multicystic, unicystic, desmoplastic, and extraosseous/peripheral<sup>1</sup>. Histopathologically, the tumor manifests across six subtypes: plexiform, follicular, acanthomatous, basal, desmoplastic, and unicystic ameloblastoma<sup>2</sup>. In the WHO's 2017 classification of head and neck tumors, amendments were made to the terminology and categorization of

ameloblastoma, reflecting a refined understanding of its pathological characteristics<sup>1</sup>. Management strategies for ameloblastoma hinge upon factors such as its location, size, intrinsic nature, and the patient's age. Tailored approaches may encompass conservative or radical interventions.

According to Almaida et al.'s comprehensive review, the follicular subtype bears a 50% recurrence likelihood, a risk mitigated substantially by adopting a radical treatment paradigm<sup>3</sup>. Despite advancements, instances of local recurrence persist, including within soft tissues, albeit occurrences within bone grafts remain exceedingly rare.

Herein, we present a case study involving a 64-year-old male patient who experienced recurrence within a non-vascularized free iliac bone graft in the mandible, three years post-initial surgery, underscoring the rarity and clinical nuances of such events. This case is contextualized within the broader landscape of ameloblastoma recurrence, as elucidated through pertinent literature reviews.

## II. Case Report

A 61-year-old male was referred to the Department of Oral and Maxillofacial Surgery at a tertiary care maxillofacial facility with a chief complaint of swelling of the lower left side of jaw and occasional pain. The swelling had increased in size gradually over 3 months. The swelling also caused a gross facial asymmetry, which also extended intra-orally creating a shift in mandibular midline. Past history revealed that he was operated for ameloblastoma and reconstruction of the defect was done using left iliac crest graft as a single stage procedure in Mar 2020. The computed tomogram and orthopantomograph of the mandible showed an expansile, well-circumscribed, round radiolucency extending 35 to 38 (Figure 1a, 1b).

An aspiration of the lesion was carried out which revealed serosanguinous fluid. Computed tomogram of mandible showed an expansile, well-circumscribed, unilocular radiolucent lesion occupying the whole grafted bone abutting the angle and the inferior border. The images showed minimal artifacts due the implants in situ (Figure 2a,2b).

Histopathological examination was suggestive of ameloblastoma. This prompted us to diagnose the case as a recurrence of ameloblastoma in the iliac crest graft. Plan for surgical resection of the lesion with removal hardware via existing extra-oral scar, which was supported with a stereolithographic model (Figure 3a,3b). Post surgical histopathology of the specimen (Figure 4,5a,5b) revealed proliferation of odontogenic epithelial cells in sheets and follicular islands with plexiform and cribriform arrangement. The basilar cuboidal cells along with juxta epithelial eosinophilic dentinoid material was seen, which were suggestive of adenoid ameloblastoma. Post-op recovery was uneventful. Patient is on periodic recall visits and planned for definitive reconstruction after a prolonged follow up owing to recurrent nature of lesion.

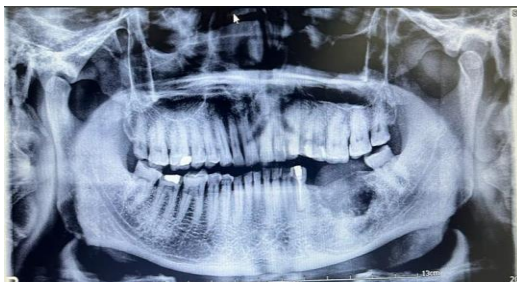

Figure-1a Preoperative Orthopantomogram

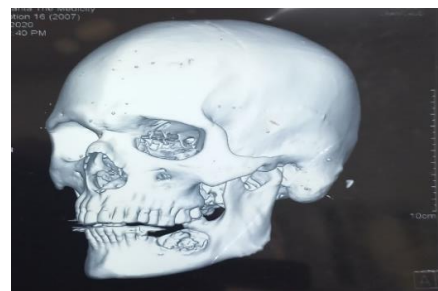

Figure-1b Preoperative 3D reconstructed CT

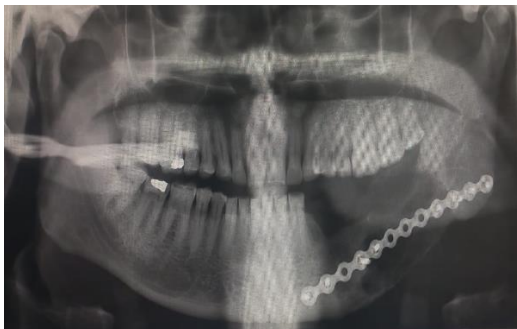

Figure-2a Postoperative orthopantomogram with implant insitu

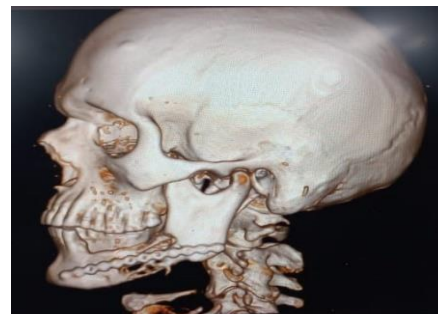

Figure-2b Postoperative 3D reconstructed CT with implant insitu

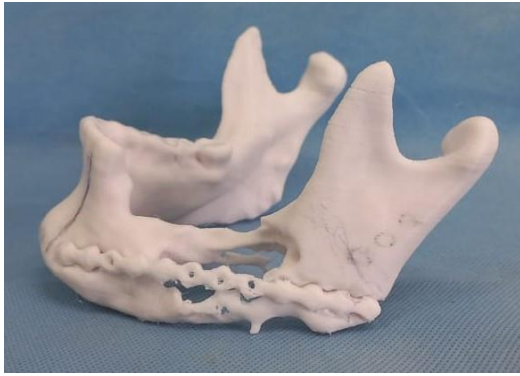

Figure-3a Stereolithographic model left lateral view

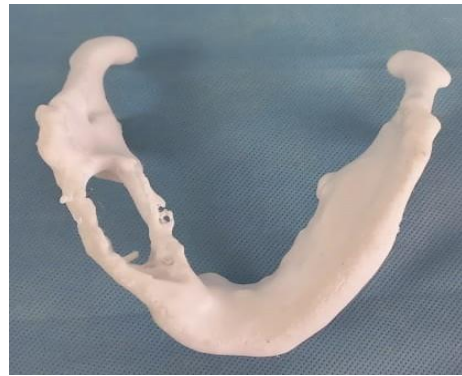

Figure-3b Stereolithographic model axial view

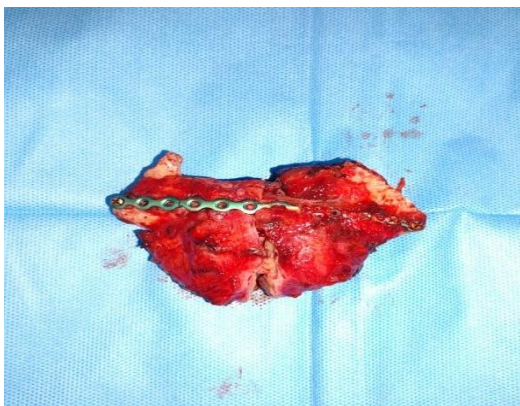

Figure-4 Resected specimen

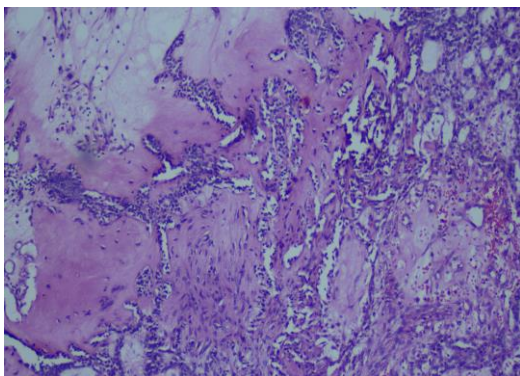


Figure-5a 40 X Histopathologic examination (HPE) showing duct like structures lined with cuboidal cells

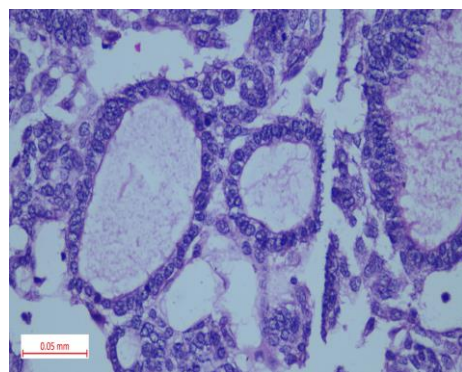


Figure-5b 100 X HPE at showing eosinophilic material and dentinoid formation

### III. Discussion:

The recurrence dynamics of ameloblastoma represent a complex interplay of various pathogenic factors, each contributing to the persistence or resurgence of the tumor. Firstly, incomplete excision of the primary tumor remains a cornerstone in the etiology of recurrence. Even seemingly thorough surgeries may inadvertently leave behind microscopic foci of neoplastic tissue within the cancellous bone margins or introduce tumor cells into surrounding tissues during enucleation procedures. These residual elements serve as niduses for regrowth, necessitating meticulous attention to surgical margins and comprehensive removal techniques 4. Secondly, the involvement of soft tissues in the recurrence process adds another layer of complexity. The overlying mucosa, intimately connected with the osseous structures affected by ameloblastoma, can harbor residual tumor cells. This

is particularly pertinent when the tumor extends beyond the confines of bone, necessitating thorough resection encompassing both osseous and soft tissue components to minimize the risk of recurrence 5. Thirdly, the phenomenon of tumor seeding during surgical manipulation is a crucial consideration in understanding graft-related recurrences. Despite meticulous surgical techniques, inadvertent dissemination of tumor cells into surrounding tissues or graft sites can occur, laying the foundation for subsequent recurrence 6. This dictates the importance of not only precise surgical execution but also rigorous debridement to mitigate the risk of seeding. The intricate pathogenesis of recurrent ameloblastoma within bone grafts presents a conundrum for clinicians and researchers alike. While the initial microscopic subtype of the tumour may not always correlate with recurrence propensity, the mechanisms underlying recurrence after short versus prolonged intervals remain elusive 7.

Exploring these challenges requires comprehensive research efforts aimed at deciphering the molecular and cellular pathways involved in tumor persistence and regrowth. Such insights are essential for refining surgical strategies, optimizing patient outcomes, and advancing our understanding of this enigmatic pathology.

#### **IV. Conclusion**

Ameloblastoma indeed reigns as the most prevalent odontogenic epithelial tumor, its clinical course often marked by challenges related to recurrence. Our recent case report illustrates this phenomenon vividly, documenting the recurrence of adenoid ameloblastoma within an iliac bone graft after a three-year interval. This case underscores the critical importance of implementing wide local excision with adequate safety margins, a cornerstone strategy aimed at minimizing the likelihood of recurrence. The recurrence of ameloblastoma, as evidenced in our case, presents a formidable clinical challenge. However, adhering to established treatment protocols, such as wide local excision, offers a promising avenue for mitigating recurrence risk. By ensuring comprehensive removal of tumor tissue with sufficient safety margins, clinicians can effectively reduce the potential for residual disease and subsequent regrowth.

#### **References**

- [1] Angadi Pv. Head And Neck: Odontogenic Tumor: Ameloblastoma. *Atlas Genet Cytogenet Oncol Haematol.* 2011;15(2):223-9.
- [2] Barnes L. World Health Organization Classification Of Tumours. *Pathology And Genetics Of Head And Neck Tumours.* 2005;232-5.
- [3] De Ac Almeida R, Andrade Ed, Barbalho Jc, Vajgel A, Vasconcelos Bd. Recurrence Rate Following Treatment For Primary Multicystic Ameloblastoma: Systematic Review And Meta-Analysis. *International Journal Of Oral And Maxillofacial Surgery.* 2016 Mar 1;45(3):359-67.
- [4] Gold L. Biologic Behavior Of Ameloblastoma. *Oral Maxillofac Surg North Am* 1991;3:21-5.
- [5] Adekeye Eo, Mccallum Lavery K. Recurrent Ameloblastoma Of The Maxillo-Facial Region. *Clinical Features And Treatment. J Maxillofac Surg* 1986;14:153-8.
- [6] Zachariades N. Recurrence Of Ameloblastoma In Bone Grafts: Report Of 4 Cases. *Int J Oral Maxillofac Surg* 1988;17:316-9.
- [7] 7.Silvio D, Franco T, Fausto P. Ameloblastoma Of The Mandible Involving An Autogenous Bone Graft. *J Oral Maxillofac Surg* 1998; 56:1187–91.