

Cyanoacrylate Glue Versus Subcuticular Sutures In The Closure Of Thyroidectomy Wound

Dr. Nedunuri Srujan,

Junior Resident, Department Of General Surgery, Mnr Medical College, Sangareddy

Dr. Lubna Tarannum,

Senior Resident, Department Of General Surgery, Mnr Medical College, Sangareddy

Dr. Rita Singh, Professor,

Department Of General Surgery, Mnr Medical College, Sangareddy

Date of Submission: 28-03-2024

Date of Acceptance: 08-04-2024

I. Introduction:

Thyroid surgical procedures are frequently conducted by general surgeons. Surgery in this area also presents notable cosmetic challenges due to its high visibility to others, making it highly relevant. These surgeries typically involve making incisions in the front of the neck, which may lead to unfavorable visual outcomes if the scars do not develop as anticipated. The topic of early and easy wound healing has garnered significant attention throughout history. An appropriate approach to incision closure should possess characteristics such as simplicity, safety, speed, cost-effectiveness, painlessness, antibacterial properties, and the ability to achieve an optimal cosmetic outcome for the scar (1). There are three main groups of wound closure biomaterials: suture materials, staples, and tissue adhesives. Octyl-cyanoacrylate adhesives have been widely employed in several applications, including tissue adhesion, hemostasis, wound closure, closure of cerebrospinal fluid (CSF) leakage, vascular embolization, and the application of skin grafts (2). This study aimed to assess the effectiveness of OCTYL-CYANOACRYLATE and subcuticular sutures in closing the skin after thyroidectomy, taking into consideration the evolving aesthetic demands of patients.

II. Aims And Objectives:

The aim of this study is to evaluate the effectiveness of Cyanoacrylate glue compared to commonly used subcuticular sutures in closing thyroidectomy wounds

Objectives:

In light of the following factors, a comparative analysis is conducted between cyanoacrylate glue and subcuticular sutures to close thyroidectomy wounds.

- Duration of wound closure during surgery.
- Postoperative wound infection and dehiscence.
- Scar cosmesis

III. Materials And Methods:

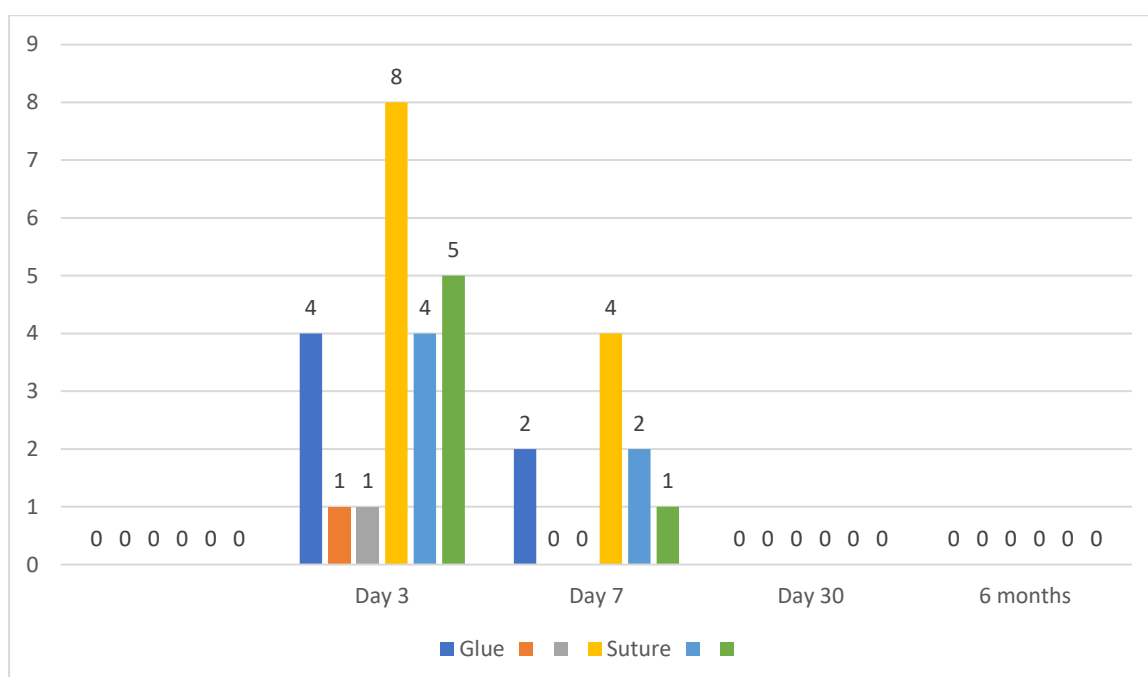
This is a prospective comparative study conducted over 50 patients who have been operated for thyroid surgery at our hospital from 2023 January to 2024 January for a period of 1 year. The age range spans from 17 to 70 years, all individuals who are undergoing thyroidectomy procedures, encompassing both total and hemithyroidectomy surgeries, all patients seeking a follow-up period of up to 6 months were included in the study. The study excluded patients who had diabetes mellitus, HIV, immunocompromised status, did not provide consent for inclusion, had a history of allergic disorders, had previous thyroid surgeries, had incisions that needed to be closed under tension, were undergoing thyroidectomy for malignancy with neck dissection or recurrence, or had a known personal history of scar hypertrophy or keloid formation. Statistical analysis has been done using Microsoft Excel 2019. This study abides by the guidelines laid by the declaration of Helsinki.

IV. Results:

The mean age of the study population was 34.2 ± 5.5 years. 46 were females and 4 were males. In each group, 23 females and 2 were included. The difference between age between both the groups is not significant at $p=0.3$. The mean time duration between suture group and glue group is 8.1 minutes and 1.2 minutes respectively. The difference between both the groups is statistically significant at $p < 0.05$. The mean modified Hollander scores of suture group and glue group were 3.9 and 3.7 respectively and the difference is significant at $p < 0.01$.

SSI grade	Glue			Suture			p-value
	1a	1c	2b	1a	1c	2b	
Day 3	4	1	1	8	4	5	0.0001
Day 7	2	0	0	4	2	1	0.02
Day 30	0	0	0	0	0	0	
6 months	0	0	0	0	0	0	

The difference between both the groups in terms of wound infection on Day 3 is statistically significant at $p < 0.0001$.



V. Discussion:

Thyroidectomy is a surgical procedure that is often conducted throughout the nation, at both high-volume medical facilities and smaller healthcare institutions. Over time, the incision employed in thyroid surgery has undergone a reduction in length, transitioning from the traditional Kocher incision of 10 cm to the shortest 15 mm access attained using minimally invasive video-assisted thyroidectomy. The primary objective is to attain a favourable cosmetic result while minimising the occurrence of postoperative morbidity. Given the comprehensive description and standardisation of this surgical procedure, our study was conducted with the aim of minimising inter-operative variability. Orthopaedic sutures (OCA) possess several advantages in comparison to traditional sutures. These advantages include their expeditious and painless application, rapid setting, resulting in reduced overall operating time, and their antibacterial qualities (3). OCA functions as a waterproof dressing and aids in minimising the need for subsequent visits. By eliminating the necessity for needles, the occurrence of unintentional needle stick injuries is effectively mitigated. Nevertheless, OCA does have significant drawbacks such as reduced tensile strength and the potential for adhesive seepage if edges are not accurately approximated. Several research have demonstrated that tissue adhesives yield better results in comparison to skin sutures. Nevertheless, it is crucial to bear in mind that platysmal suture support remains necessary, and it is imperative to maintain skin cohesion when applying the adhesive to avoid the accumulation of the cyanoacrylate polymer in the wound, which could potentially impede or hinder the healing process (4). In a study conducted by Bernard and colleagues, they compared the effectiveness of octyl cyanoacrylate tissue adhesive and suture in closing excisional wounds in children and adolescents. They found that the cosmetic outcome of wounds closed with standard suturing after cutaneous excisional surgery was better than that of wounds closed with OCA. This finding

is consistent with the study conducted by Handschel and colleagues on facial wound closures. Our investigation revealed that there was no notable disparity in the visual aspects of the wound when comparing wounds sealed with cyanoacrylate glue against those closed with sutures. In their investigation, David Greene and his colleagues observed no disparities in wound problems, healing length, inflammation, or final incision appearance when comparing the use of glue and suture. In the present investigation, a notable disparity was observed between the two methodologies in the initial POD 3 and POD 7. The wound exhibited improved cosmetic appearance and reduced indications of inflammation when closed using cyanoacrylate glue as opposed to subcuticular sutures. The utilisation of OCA during the early postoperative days resulted in a slight improvement in scar appearance among patients. One of our patients experienced wound collection, for which OCA was employed. However, the collection diminished during aspiration, potentially because to a flawed method. The cost of OCA is frequently cited as a contributing factor. Research has indicated that wounds that are closed with tissue adhesives are more expensive, but they may be favoured by patients who are hesitant about traditional suturing and are unwilling to undergo follow-up for suture removal. However, the performed investigation demonstrated that there was minimal disparity between OCA and subcuticular sutures. Furthermore, a notable distinction exists in the time of administration between OCA and subcuticular prolene sutures. Consequently, this leads to an extended period of anaesthesia, procedure, and theatre duration. The reduction of this additional time can result in financial savings for the patient.

VI. Conclusion:

In the first postoperative days, OCA demonstrates a superior outcome compared to sutures. However, in the long-term 6-month follow-up, OCA exhibits an equivalent cosmetic outcome when compared to the commonly employed subcutaneous prolene sutures. Since the cost of OCA is equal to that of prolene, the cost effectiveness of the procedure will remain unchanged. Furthermore, the antimicrobial and water-sealing properties of OCA reduce the likelihood of surgery site infections.

References:

- [1] Soni A, Narula R, Kumar A, Parmar M, Sahore M, Chandel M. Comparing Cyanoacrylate Tissue Adhesive And Conventional Subcuticular Skin Sutures For Maxillofacial Incisions--A Prospective Randomized Trial Considering Closure Time, Wound Morbidity, And Cosmetic Outcome. *J Oral Maxillofac Surg.* 2013 Dec;71(12):2152.E1-8.
- [2] Mora-Galvan Ja, Reyes-Paredes N, Grosso-Espinosa Jm, Ortiz-Ramirez Ma, Godines-Enriquez Ms, Sepulveda-Rivera Cm. Use Of Cyanoacrylate N-Butyl Versus Subcuticular Suture In The Dermal Closure Following Cesarean Delivery: A Randomized Controlled Trial. *Journal Of Clinical Gynecology And Obstetrics.* 2019 Sep 30;8(3):85-90.
- [3] Wang Ls, Wang Xy, Tu H Tian, Huang Yf, Qi X, Gao Yh. Octyl-2-Cyanoacrylate Tissue Adhesive Without Subcuticular Suture For Wound Closure After Total Hip Arthroplasty: A Prospective Observational Study On Thirty-Two Cases With Controls For 3 Months Follow-Up. *Journal Of Orthopaedic Surgery And Research.* 2020 Oct 10;15(1):467.
- [4] Martin Jg, Hollenbeck St, Janas G, Makar Ra, Pabon-Ramos Wm, Suhocki Pv, Et Al. Randomized Controlled Trial Of Octyl Cyanoacrylate Skin Adhesive Versus Subcuticular Suture For Skin Closure After Implantable Venous Port Placement. *Journal Of Vascular And Interventional Radiology.* 2017 Jan 1;28(1):111-6.