

Bilateral Giant Multilocular Epididymal Cyst In A Middle Aged Patient: A Case Report

Varsha Anna Varghese¹, Tejashree Sonawane², Ananta Kulkarni³,
Yashashri Ganjale⁴, Kshitija Pawar⁵

¹senior Resident, Department Of General Surgery, Bavmc, Pune, ²senior Resident, Department Of General Surgery, Bavmc, Pune, ³professor & Hod, Department Of General Surgery, Bavmc, Pune, ⁴intern, Department Of General Surgery, Bavmc, Pune ⁵intern, , Department Of General Surgery, Bavmc, Pune

Abstract:

Bilateral multilocular large epididymal cysts are a rare entity with few cases reported in the literature. Epididymal cysts are mostly found in middle-aged men with or without symptoms. We present the case of a 40-year-old man with asymptomatic bilateral scrotal swelling, which was clinically diagnosed as bilateral epididymal cyst. On investigations, an ultrasound of the scrotum revealed bilateral epididymal cysts with normal testes. Intraoperatively, it demonstrated bilateral huge epididymal cysts for which the patient underwent excision of bilateral epididymal cysts. Postoperatively, the patient is doing well on follow-up. Thus, it is concluded that when the epididymal cyst is larger than 1-2 cm and does not involute with time or is symptomatic, surgery is indicated.

Key Word: bilateral epididymal cyst, multilocular

Date of Submission: 13-03-2024

Date of Acceptance: 23-03-2024

I. Introduction

Epididymal cysts are collection of serous fluid in a single sac (unilocular) or more than one (multilocular) due to dilatation of efferent epididymal tubules as a result of tubular obstruction^{1,2}. They are benign in nature and mostly unilateral, rarely can be bilateral. An asymptomatic, bilateral, and multilocular giant epididymal cyst is rare. Epididymal cysts and spermatoceles on several occasions have been used reciprocally to describe the same entity². It is commonly seen in middle-aged males. But they can occur at any age, and some authors found that there may be an increase in the proportion of epididymal cysts with age; previous published case reports revealed the condition to be present in about 5% of pediatric patients undergoing scrotal ultrasonography in general³. They commonly arise from the epididymal head. Cysts arising from the epididymal tails are rare. Only few reports are found in the literature^{4,5}. Approximately 30% of men have been diagnosed with small spermatoceles, while fewer have larger spermatoceles. Surgery is indicated if the cysts are larger than 1-2 cm. Otherwise, it is advised to manage conservatively.⁶ Here, we present a rare case report of asymptomatic bilateral giant multilocular epididymal cysts in a middle-aged man.

II. Case Presentations

A 40 year old male presented to the surgical outpatient department with complaints of bilateral scrotal swelling for ten months. The patient had no history of any trauma, pain, fever, urinary symptoms, or comorbidities. Physical examination demonstrated nonreducible, non-tender, and bilateral scrotal swellings (right>left) adjacent to normal testes bilaterally with fluctuation and transillumination tests positive (Figure 1). Both testes were palpable with normal size and location. The cough impulse test was also negative. Differential diagnosis included left-sided secondary hydrocele with right-sided epididymal cysts and bilateral hydroceles of spermatic cord. Figure 1 -clinical presentation of bilateral scrotal swellings.

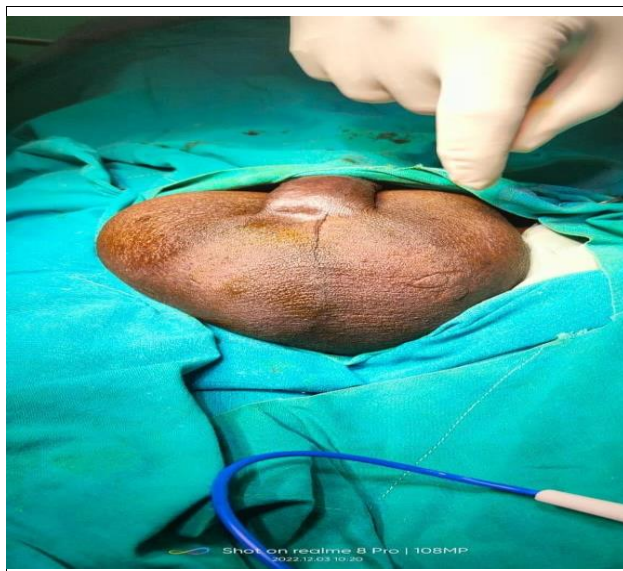

Figure 1 -clinical presentation of bilateral scrotal swellings.

On investigating, scrotal ultrasound showed two large cystic swellings arising from both epididymal heads of size measuring 80X 60 mm on the left and 100 X 70 mm on the right. Both testes appeared normal in size, shape, and echogenicity with the normal color flow in the doppler scan.

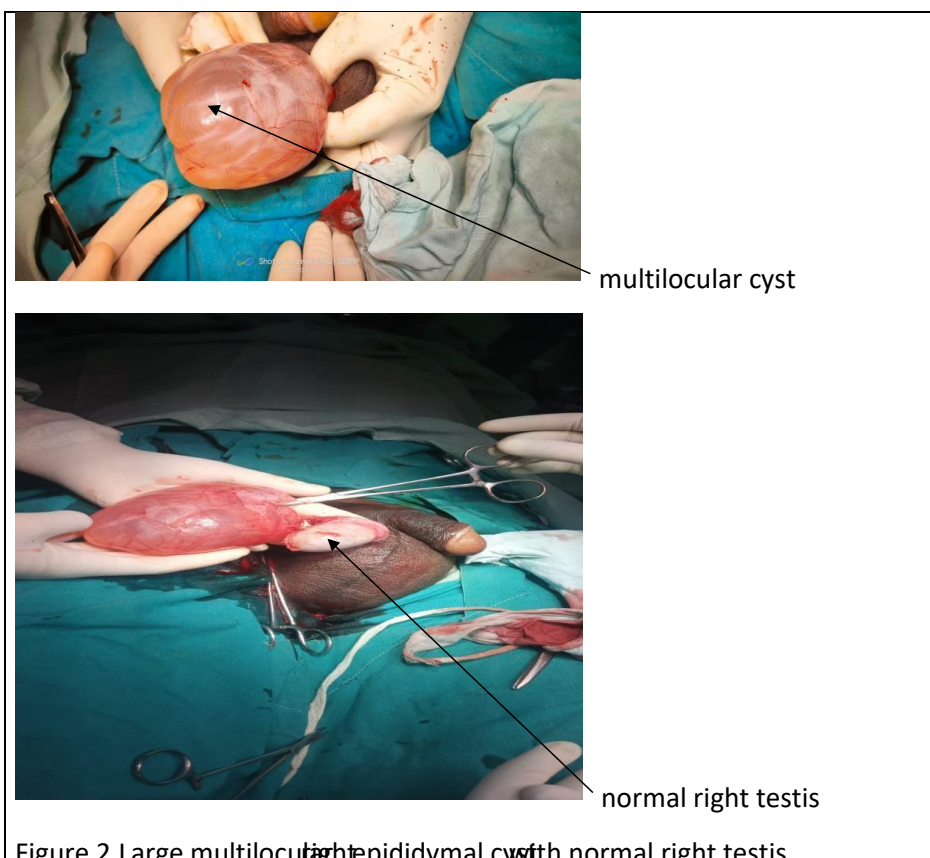
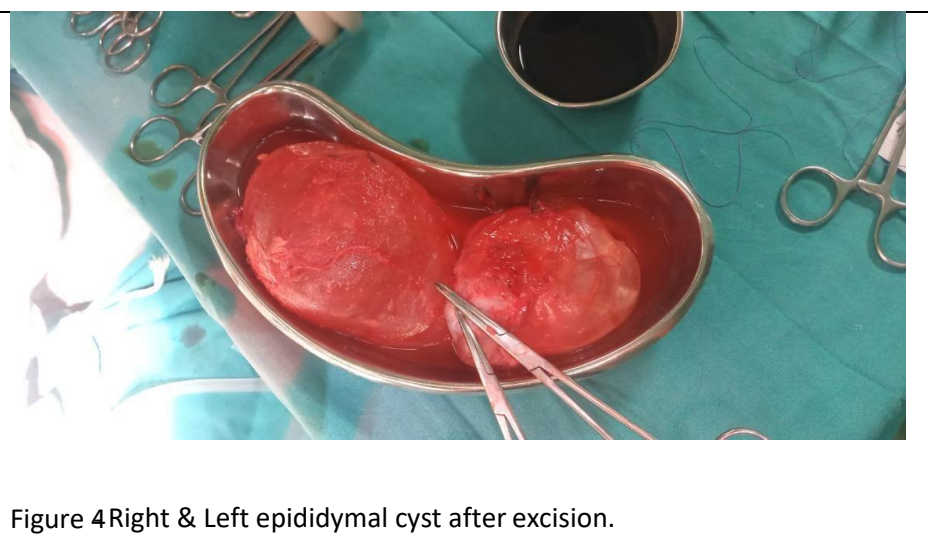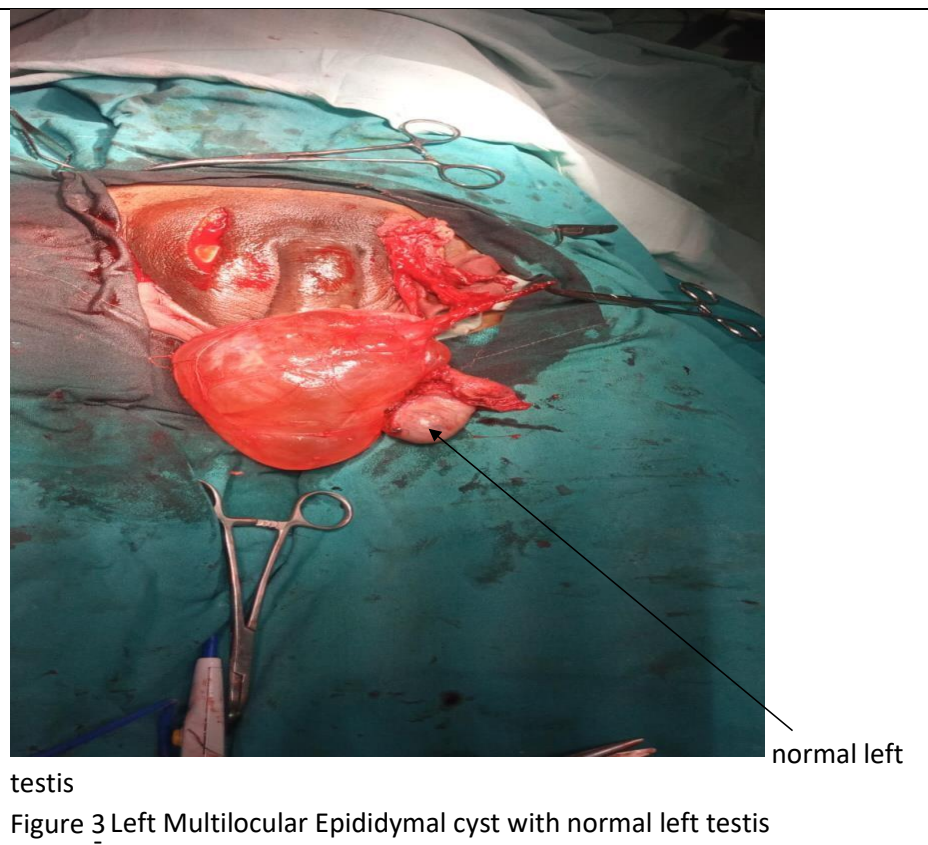


Figure 2 Large multilocular right epididymal cyst with normal right testis

Thus, the patient was taken for elective surgery. After tunica vaginalis exploration, a large thinned out translucent cyst was identified with multilocularity within, of size 10 X 7 X 2.5 cm on the right side (Figure 2) and 8X 6X 2 cm on the left side (Figures 3&4). The connection of the cysts was found to be attached to the heads of epididymis on both sides. Surgery was uneventful. The patient was discharged two days after the surgery and was advised to follow up for suture removal after seven days and maintain local hygiene over the suture site.



III. Discussion

An epididymal cyst is a fluid collection in either a single (unilocular) or more than one sac (multilocular) due to efferent epididymal tubules dilatation as a result of tubular obstruction^{1,2}. They usually are unilateral and are found commonly amongst adult men. The incidence of either hydrocele or spermatocele diagnosed is approximately 100 per 100,000 men⁷. Bilateral epididymal cysts are significantly less frequent⁴. Multilocularity of epididymal cysts is rarer and rarely reported in the literature. Ushida H et al.⁴ had reported multilocular bilateral synchronous epididymal cysts to date. Similar findings were noted in our case too, wherein a 40-year-old middle-aged gentleman had asymptomatic bilateral giant epididymal cysts with multilocularity arising from epididymal heads on both sides. Epididymal cysts can be symptomatic and can present with variable clinical presentations. A patient may narrate scrotal swellings as a third testicle. They may also present with testicular pain⁸. On clinical examination, the epididymal cyst is palpated as an extra testicular mass, usually smooth, round, and characteristically located adjacent to the testis⁵. These epididymal cysts are translucent in appearance since they

contain clear fluid in them, but in some cases, it appears to be turbid due to the presence of spermatozoa within them¹. In our patient, the size of the cyst was found to be larger and bilateral. In this case, the patient did not have any symptoms like scrotal pain. It was only scrotal swelling that bothered the patient to undergo an ultrasound examination to confirm the diagnosis. Ultrasound helps determine the location, site of origin, the content of the cyst, size, shape, and vascularity of the testes. The head of the epididymis is identified as the most common site of origin of the cyst, while the body and tail of the epididymis are rare sites¹. Cystic tumors like epidermoid cyst (monodermal teratoma) of the testes and the adenomatoid tumor of epididymis could be considered a differential diagnosis⁹. Treatment options for epididymal cysts depend on the patient's presentation, symptoms, and clinical findings. Most of the epididymal cysts involute with time⁹. Conservative management, sclerotherapy, aspiration of the cyst, and excision of the cyst could be various management or treatment options for epididymal cysts. The surgical modality is used when the patient presents with acute symptoms like acute scrotal pain or huge scrotal swelling. Surgical excision of cyst is done in such situations¹⁰. Surgery is indicated when the cyst is larger than 10 mm or 1 cm and does not involute with time⁶. Our patient had an asymptomatic giant bilateral multilocular epididymal cyst. He underwent excision of cysts bilaterally and was discharged after two days, and he was doing well on his follow-up.

IV. Conclusion

Conservative management still remains the initial choice of treatment for asymptomatic epididymal cyst with a size measuring < 1 -2cm, while surgical modality is the only mainstay of treatment for patients with acute symptomatology like intractable scrotal pain and large swelling and also when the size of the cyst does not regress on its own instead increases with time. From this rare case presentation, we would like to conclude that the cases of small-to- medium scrotal swelling or small hydrocele, epididymal cysts should always be kept into consideration as a differential diagnosis.

References

- [1] Arora Bk, Arora R, Arora A. A Randomised Study Of Management Modalities In Epididymal Cyst. *Int Surg J*. 2019;6(2):340-344.
- [2] Fernández-Ibieta M, Villalon-Ferrero F, Ramos-García JI. Benign Scrotal Tumor In A Pediatric Patient: Epididymal Cyst. *Case Rep Urol*. 2018; 2018:1-3.
- [3] Posey Zq, Ahn Hj, Junewick J, Chen Jj, Steinhardt Gf. Rate And Associations Of Epididymal Cysts On Pediatric Scrotal Ultrasound. *J Urol*. 2010;184(4):1739-1742.
- [4] Ushida H, Hayashida H, Kim Cj, Park Ki, Okada Y: Bilateral Synchronous Multilocular Epididymal Cysts: A Case Report. *Jpn J Urol*. 1999, 90:692-695. 10.5980/Jpnjurol1989.90.692.5. Akin Y, Sarac M, Basara I, Yucel S, Kazez A: Bilateral Epididymal Cyst In 14-Year-Old Boy: A Case Report. *J Health Sci*. 2014, 4:68-71. 10.17532/Jhsci.2014.150
- [5] Boscarelli A, Bellini T: Epididymal Cyst In Children. *Eur J Pediatr*. 2021, 180:2723-2729.
- [6] 10.1007/S00431-021-04080-5
- [7] Lundström Kj, Söderström L, Jernow H, Stattin P, Nordin P: Epidemiology Of Hydrocele And Spermatocele; Incidence, Treatment And Complications. *Scand J Urol*. 2019, 53:134-138. 10.1080/21681805.2019.1600582
- [8] Mukendi Am: Bilateral Epididymal Cyst With Spontaneous Resolution. *Clin Case Rep*. 2020, 8:2689-2691.
- [9] Bleve C, Conighi Ml, Bucci V, Costa L, Chiarenza Sf: Torsion Of Huge Epididymal Cyst In A 16-Year-Old Boy: Case Report And Review Of The Literature. *Pediatr Medchir*. 2018, 40:10. 4081/Pmc.2018.162
- [10] Eriki V, Hoşgör M, Aksoy N, Et Al.: Management Of Epididymal Cysts In Childhood. *J Pediatr Surg*. 2013,48:2153-2156. 10.1016/J.jpedsurg.2013.01.058