

A Case Of Small Cell Carcinoma Of Lung Presenting As Large Anterior Mediastinal Mass

Dr. Samba Siva Rao.G¹, Dr. M Chiranjeevi Reddy², Dr. Gouthami. U³,

1.Professor And Hod 2. Post Graduate 3. Senior Resident; Department Of Pulmonology, Gimsr Hospital, Visakhapatnam

Abstract:

small cell lung cancer (sclc) is a subtype of bronchogenic carcinoma separated from non-small cell lung cancer (nsccl) as it has a unique presentation, imaging appearances, treatment and prognosis. Sclc are neuroendocrine tumors of the lung that rapidly grow, highly malignant, widely metastasize, and despite showing an initial response to chemotherapy and radiotherapy, they have a poor prognosis and are usually unresectable.

Key words: immunohistochemistry (ihc), neuroendocrine tumour (net), Nsccl, sclc

Date of Submission: 17-02-2024

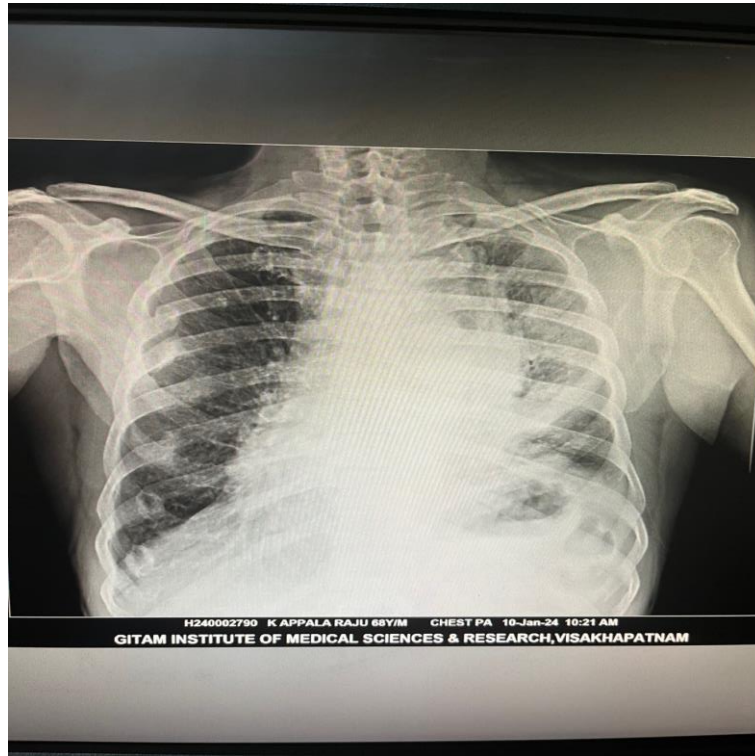Date of Acceptance: 27-02-2024

I. Introduction

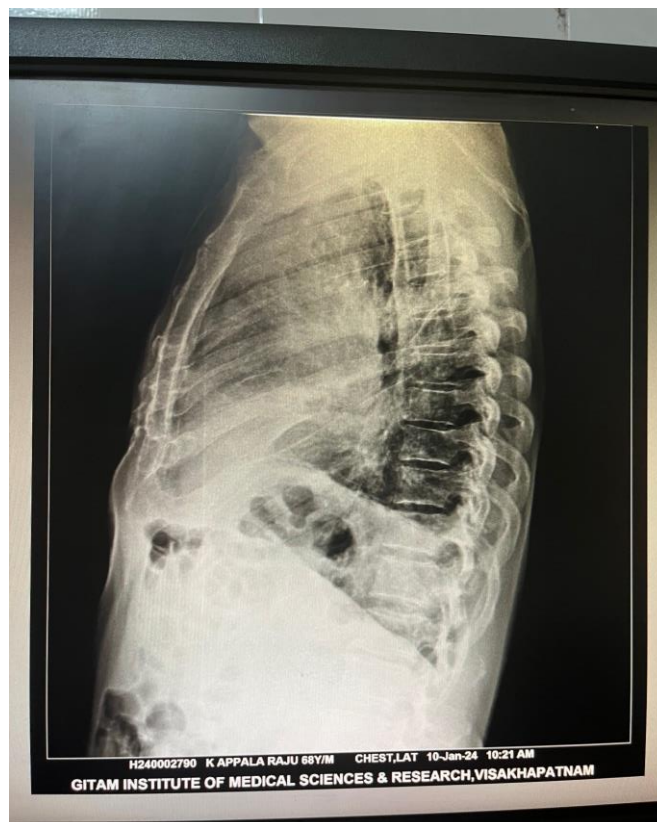Globally lung cancer remains the leading cause of cancer related mortality¹. Tobacco smoking is still the leading cause of the lung cancer, conferring 20-fold increase in risk and accounting for approximately 90% of all the cases³. Sclc is more strongly associated with smoking than any other histological subtypes of lung cancer with only 2% of cases occurring in never smokers. 2021 WHO classification identifies 3 major types of neuroendocrine tumors (net) – carcinoid tumors, small cell carcinoma and large cell carcinoma. Incidence is about 25% of all primary pulmonary carcinomas, with small-cell carcinoma being the most common (nearly 80% of neuroendocrine tumours)².

II. Case report

A 68-year-old male patient truck driver by occupation, presented to respiratory medicine outpatient department in GITAM Institute of Medical Sciences and Research Hospital, Visakhapatnam on 7/1/24 with chief complaints of difficulty in breathing for 30 days and productive cough for 30 days. Patient was apparently normal 1 month back, later he presented with complaints of difficulty in breathing, insidious onset, gradually progressive from mMRC grade 1 to grade 3 over 30 days. Aggravated on lying in supine position, relieved on sitting position. Mucoïd expectoration not associated with any hemoptysis. History of loss of appetite with 4 kgs weight loss in a month. There is no relevant past history. Patient is a hypertensive and type 2 diabetes controlled by medication. Significant cigarette smoking history with 20 pack years and smoking index of 400. General examination revealed grade 3 digital clubbing of fingers. Patient is tachypneic with rate of 26/minute. Chest examination revealed contralateral tracheal shift with decreased movements on the left infraclavicular and mammary areas. Correlating the same there is decreased tactile vocal fremitus and direct sternal percussion revealed dull note, indirect percussion revealed dull note in left infraclavicular and left mammary areas. Auscultation revealed diminished breath sounds in the entire left hemithorax with localized wheeze in the left mammary area.



Chest x-ray pa revealed superior mediastinal widening with tracheal shift to right with volume loss on left hemithorax with elevated left hemidiaphragm with enlarged cardiac silhouette



Cbp-leucocytosis 11400/mm³ with neutrophilia (79%)

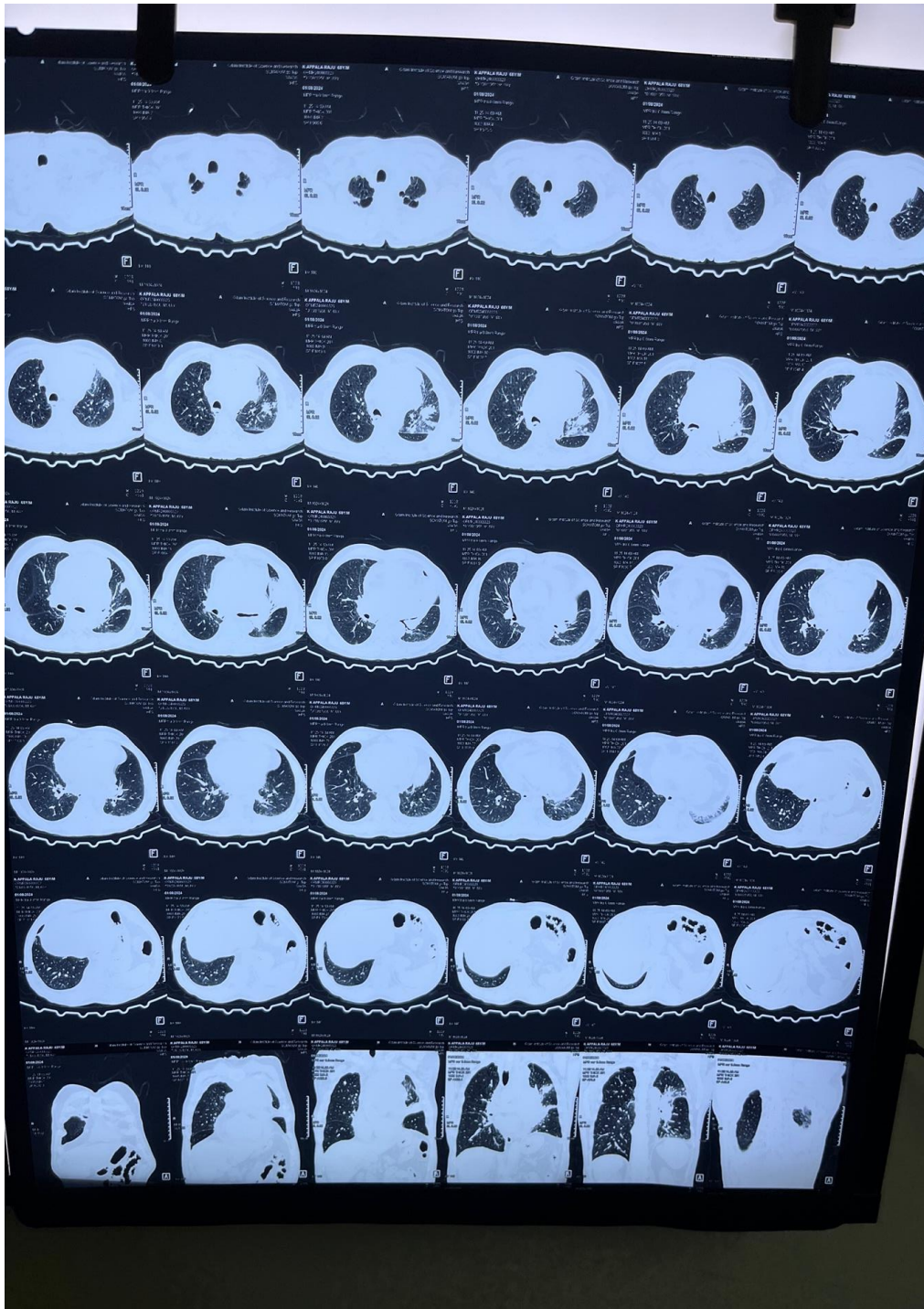
Lft and rft – normal range

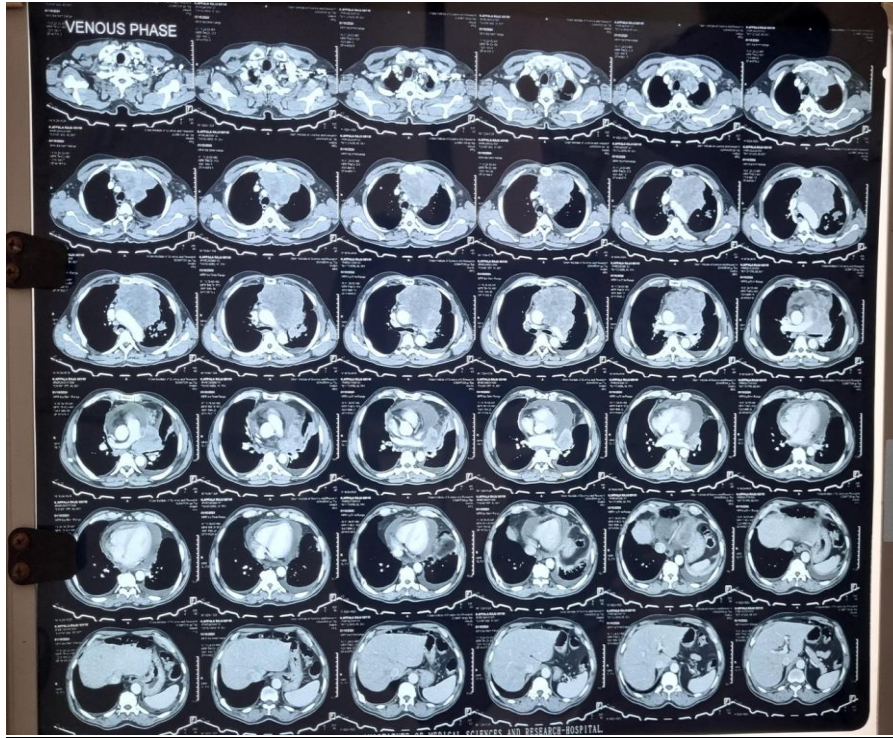
Serum electrolytes – normal range

Usg abdomen – grade 1 fatty liver

Cect chest revealed a large soft tissue density lesion with lobulated margins with its epicentre in the visceral compartment extending into pre vascular compartment of mediastinum . The lesion is measuring approx. 10.8*9.0*10.9 cm and showing heterogenous contrast enhancement .the lesion is seen abutting and encasing the great vessels .mass effect is seen in the form of deviation of trachea to right , displacement of arch of aorta and its branches , main pulmonary artery and left pulmonary artery posteriorly. Pericardial effusion noted .spiculated mass lesion measuring 3.2*1.9*2.8cm noted in left upper lobe ,pulmonary nodules noted along the oblique fissure on the left upper lobe with adjacent lingula collapse . Emphysematous changes noted bilaterally . Elevated left hemidiaphragm .left mild pleural effusion. A note is made of pre-tracheal, subcarinal and paratracheal lymph nodes

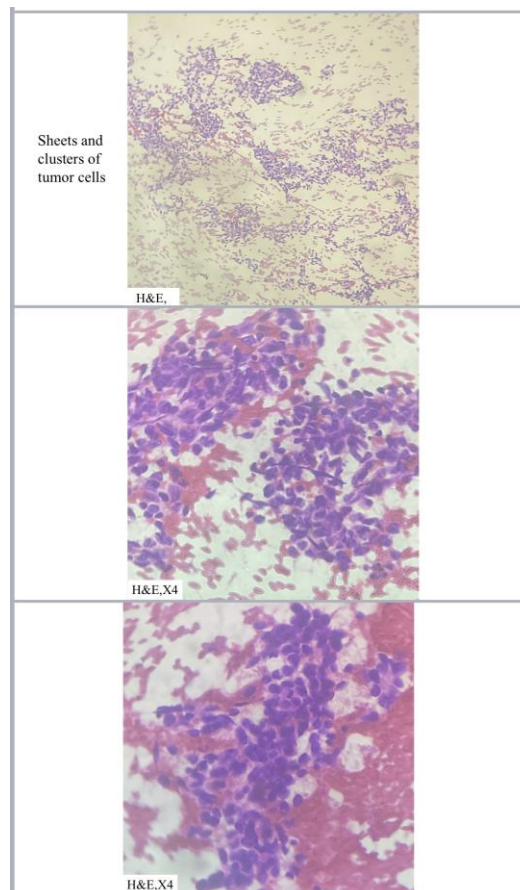
Differential diagnosis includes thymic neoplasia,lymphoma ,non-teratomatous germ cell tumour, small cell carcinoma

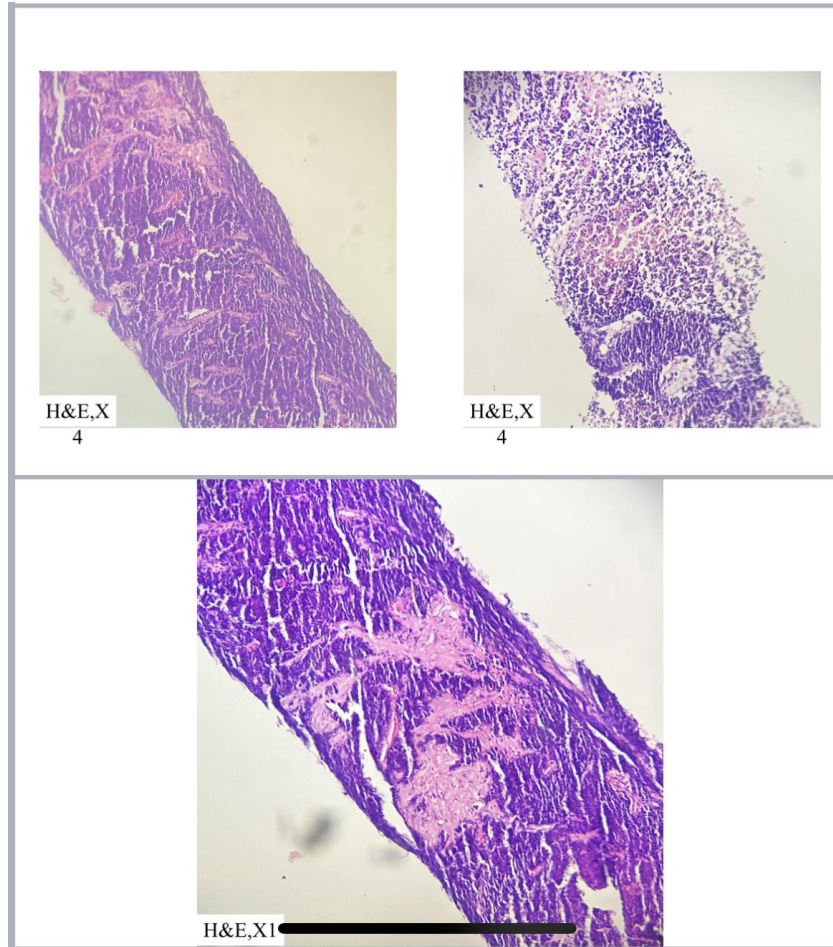




Usg guided core needle biopsy

Cytopathology report shows sheets and nests of small round cells with fine chromatin, inconspicuous nucleolus and scant cytoplasm. Areas of necrosis are seen suggestive of neoplastic lesion, probably small cell carcinoma.





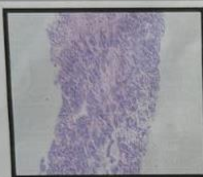



Ihc- tumour cells are positive for ck(dot like), ttf-1, synaptophysin ,cd56 and negative for p40, cd5 ,and ki-67 index 80%


Final diagnosis- small cell carcinoma

IMMUNOHISTOCHEMISTRY STUDIES

The tumor cells are positive for CK (dot like), TTF-1, Synaptophysin, CD56 and negative for P40, CD5
Ki67~80%

IMMUNOHISTOCHEMISTRY STUDIES

			
H&E	CK (AE1/AE3)	TTF- 1 (8G7G3/1)	SYNAPTOPHYSIN (SYPP)

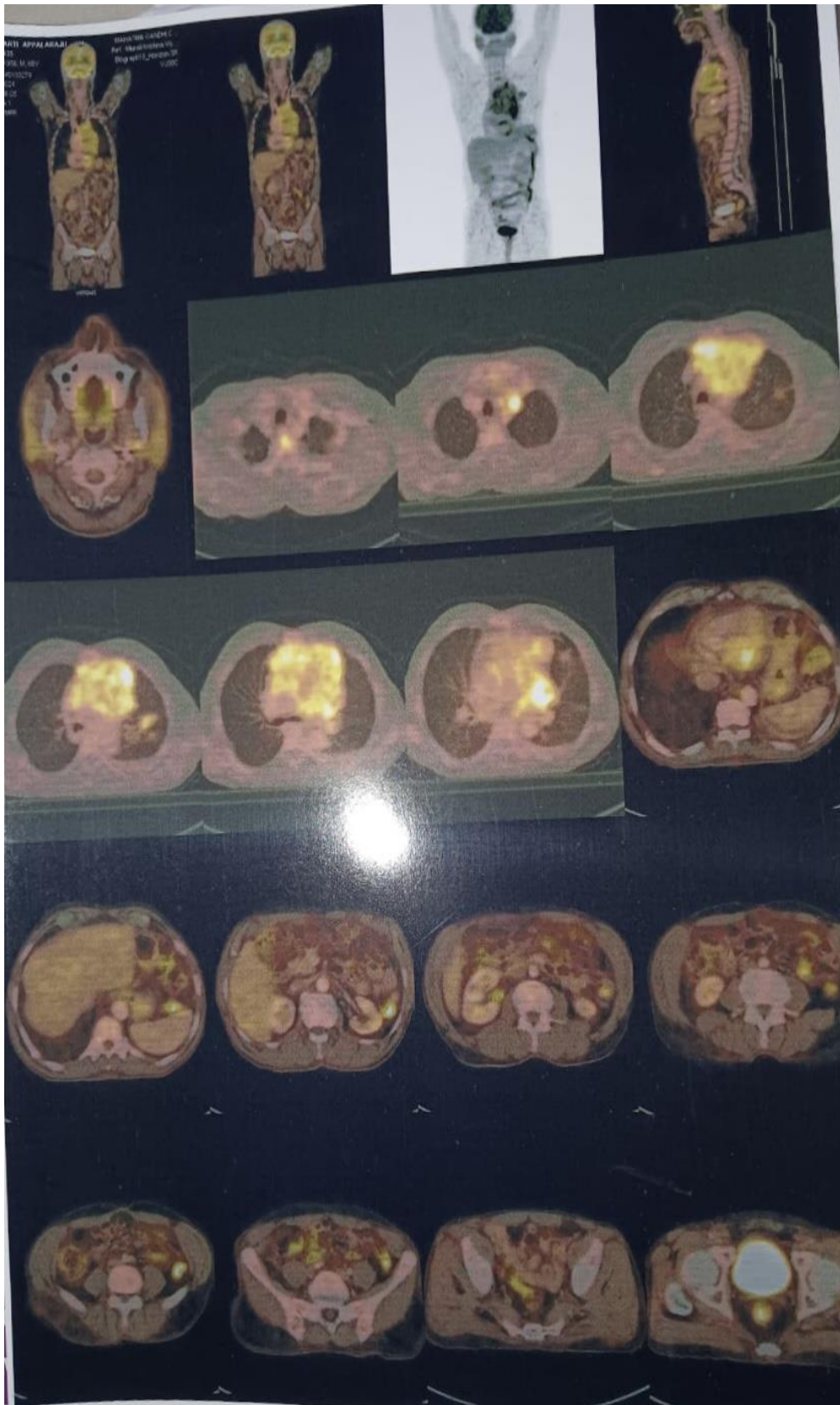

CD56 (123C3)

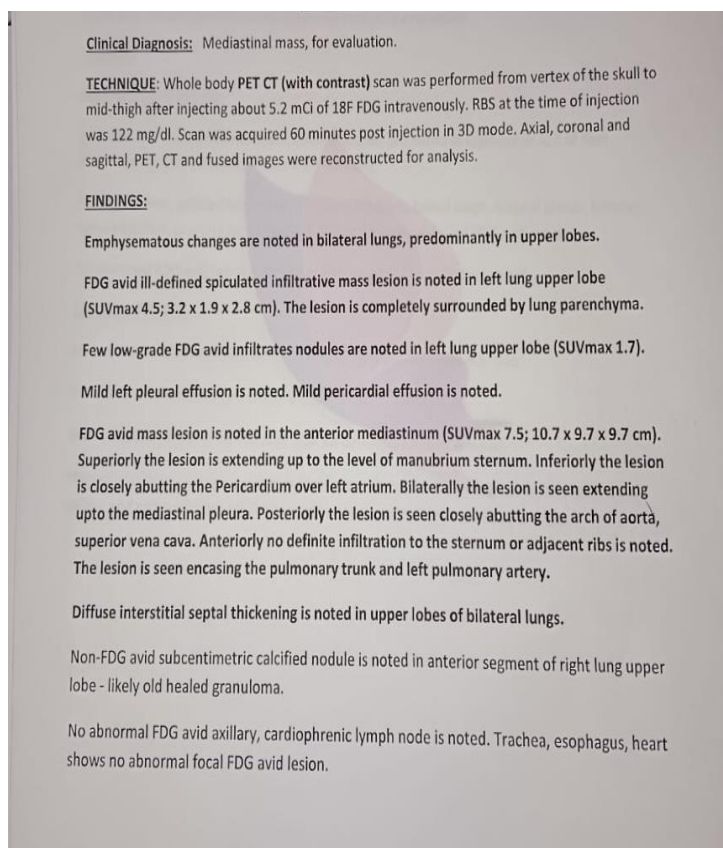
TECHNICAL NOTE

All immunohistochemistry markers have been evaluated in the context of appropriate positive and negative controls. A result is considered uninterpretable as a result of the type of fixative used (non 10% neutral buffered formalin), time to fixation (> 1 hour), duration of fixation (> 6 hr or <72 hour), strong decalcification, or inappropriate staining of normal internal or external assay controls. An alternative sample for retesting is then usually recommended. These assays have not been validated on decalcified specimens.

A Case Of Small Cell Carcinoma Of Lung Presenting As Large Anterior Mediastinal Mass

After final diagnosis has been made , **18-fdg pet-ct scan** revealed – metabolically active lesions were reported in left upper lobe likely primary neoplastic lesion and metabolically active mass lesion noted in mediastinum with sclerotic lesions in d1,d2 vertebrae suggestive of metastases. Currently patient received two cycles of cisplatin and etoposide and is doing well .





III. Discussion

Net's are group of tumours with heterogeneous origin that evolve from neuroendocrine cells , with lung being the second target organ after the git tract. In our report the patient is a male with 68 years based on patient age and shorter duration of symptoms , significant smoking history with clubbing and cect findings hpe was done from the mediastinal mass which suggested small cell carcinoma .bronchoscopy could not be done as patient had severe dyspnoea . Ihc was done and came out to be positive for cd56 which is most sensitive marker for small cell carcinoma of lung and synaptophysin which is specific marker for neuroendocrine tumours.

IV. Conclusion

This is a case of small cell carcinoma of lung with small primary lesion in lung presenting as a large anterior mediastinal mass which is a rare presentation. The classical differential diagnosis of anterior mediastinal mass includes 4t's i.e. Terrible lymphoma, thymoma, thyroid mass and teratoma. This case warrants to think beyond while evaluating an anterior mediastinal mass as metastases are also an important differential diagnosis. Timely diagnosis and staging of such masses helps in early initiation of treatment and alleviating patient symptoms.

References

- [1]. Globocan 2020 Report : Global Cancer Observatory Agency For Research On Cancer
- [2]. Who Classification Of Tumours Editorial Board. Thoracic Tumours . In: Who Classification Of Tumours ,5th Ed, International Agency For Research On Cancer ,Lyon, France .
- [3]. Tumourclassification.larc.Who.Int/Chapters/35
- [4]. Alberg Aj, Brock Mv, Ford Jg, Et Al. Epidemiology Of Lung Cancer: Diagnosis And Management Of Lung Cancer, 3rd Ed:
- [5]. American College Of Chest Physicians Evidence-Based Clinical Practice Guidelines. Chest. 2013;143(5 Suppl):E1s–E29s.
- [6]. 4.Jeon J, Holford Tr, Levy Dt, Et Al. Smoking And Lung Cancer Mortality In The United States From 2015 To 2065: A Comparative Modeling Approach. Ann Intern Med. 2018;169(10):684–693
- [7]. Pesch B, Kendzia B, Gustavsson P, Et Al. Cigarette Smoking And Lung Cancer–Relative Risk Estimates For The Major Histological
- [8]. Types From A Pooled Analysis Of Case–Control Studies. Int J Cancer. 2012;131(5):1210–1219.
- [9]. Dela Cruz Cs, Tanoue Lt, Matthay Ra. Lung Cancer: Epidemiology, Etiology, And Prevention. Clin Chest Med. 2011;32(4):605–644
- [10]. Fushimi H, Kikui M, Morino H, Et Al. Histologic Changes In Small Cell Lung Carcinoma After Treatment.Cancer.1996;77(2):
- [11]. 278–283.
- [12]. Thunnissen E, Borczuk Ac, Flieder Db, Et Al. The Use Of Immunohistochemistry Improves The Diagnosis Of Small Cell Lung Cancer And Its Differential Diagnosis. An International Reproducibility Study In A Demanding Set Of Cases. J Thoracic Oncol. 2017;12(2):334–346.