

# Temporomandibular Joint Ankylosis In True Hemifacial Hyperplasia With Infiltrative Lipomatosis - A Case Report

Dr.Anju S Raj, Dr.Ravindran Nair K S, Dr.Ikram Bin Ismail.P T, Dr.Seeja P, Dr.Ram Mohan R S, Dr.Fasalulla O

(Junior Resident, Dept. Of Oral & Maxillofacial Surgery, Government Dental College, Kozhikode, Kerala, India)  
(Professor & Head, Dept. Of Oral & Maxillofacial Surgery, Government Dental College, Kozhikode, Kerala, India)

(Asst.Professor, Dept. Of Oral & Maxillofacial Surgery, Government Dental College, Kozhikode, Kerala, India)

(Asst Professor, Dept. Of Oral & Maxillofacial Surgery, Government Dental College, Kozhikode, Kerala, India)

(Asst.Professor, Dept. Of Oral & Maxillofacial Surgery, Government Medical College, Wayanad, Kerala, India)

(Asst.Professor, Dept. Of Oral & Maxillofacial Surgery, Government Medical College, Manjeri, Kerala, India)

---

## Abstract:

Congenital infiltrative lipomatosis of the face is a benign condition in which mature adipocytes invade adjacent tissues causing diffuse fatty infiltration into the surrounding soft tissue and hyperplasia of the adjacent bone on the affected side. This case report of a 37-year-old female with congenital facial asymmetry and diffuse swelling on the right side of the face suggests true hemifacial hyperplasia, which is supported by both clinical and radiographic evidence showing severe involvement of underlying bony structures of the temporomandibular joint, sphenoid, temporal, zygoma, right maxilla, mandible, associated dentition and lipomatous enlargement of adjacent soft tissues with right temporomandibular joint ankylosis, reported with multiple etiological factors and marked trismus for which functional rehabilitation was achieved following surgical intervention.

**Keywords:** Temporomandibular joint ankylosis; Hemifacial hyperplasia; Infiltrative lipomatosis

---

Date of Submission: 04-11-2024

Date of Acceptance: 14-11-2024

---

## I. Introduction

Congenital infiltrating lipomatosis of face was first described as a distinct clinical-pathologic condition by Slavin et al. in 1983<sup>1</sup>. Sun et al (2019) considered it to be a subtype of hemifacial hyperplasia<sup>2</sup>. It can penetrate the underlying facial bones, associated soft tissue, and facial muscles, resulting in severe facial asymmetry and dental malformations. Although the entity's genesis and clinical behavior are yet unknown, research indicates that FGFR3 and PIK3CA gene mutations might be the reason<sup>3</sup>. Seldom has infiltrating lipomatosis been implicated in the development of TMJ ankylosis.

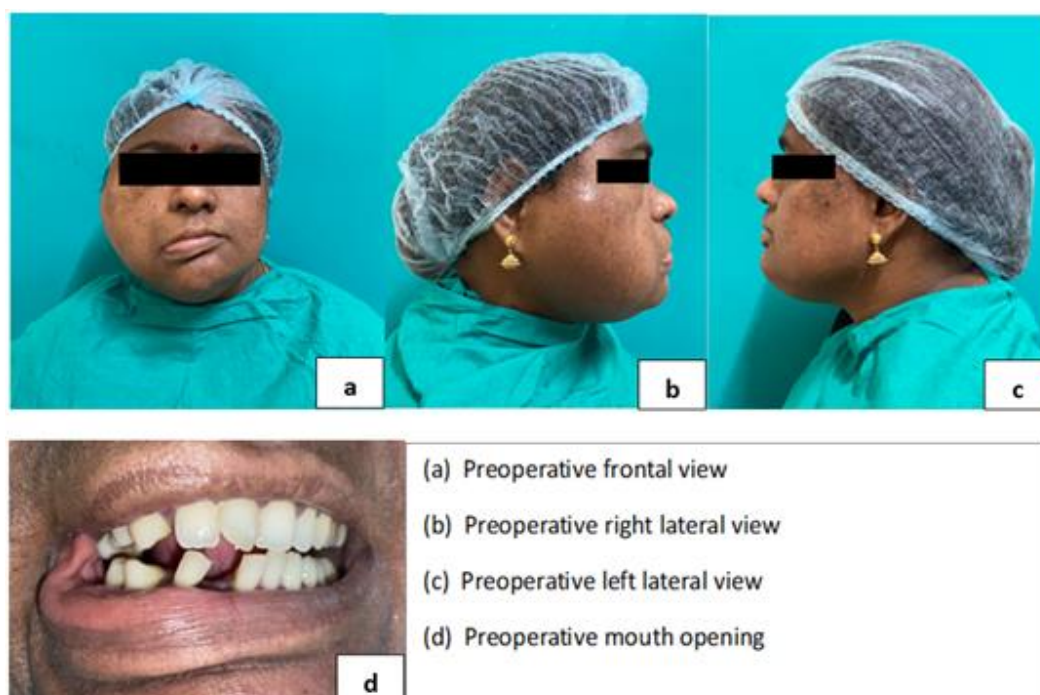## II. Case Report

A 37-year-old female patient who had been referred from a nearby hospital eight months ago presented to our center with complaints of restricted mouth opening. She had right side facial asymmetry since childhood for which she underwent surgery to right side of face at 9 years of age, with history of earache and fluid discharge from right ear at 20 years of age and underwent excision of osteoma over right ear region following which she noticed gradual reduction in mouth opening. She had no history of any known drug allergies, systemic diseases or family history

On general examination, the patient was moderately built and nourished. Face was asymmetrical with fullness on the affected side. A diffuse swelling of size approximately 15cm x 8 cm present on right side of face extending superoinferiorly from right zygoma region to right inferior border of mandible. Antero-posteriorly extending from right corner of lip to preauricular region with nasolabial fold obliteration and dropping of right corner of lip. A vertical scar marking of size ≈5cm was present on anterior aspect of cheek margin. (Figure 1: a, b, c)

On palpation, swelling was variable in consistency, hard towards right zygoma region and soft towards lower 2/3 rd of face with overlying normal skin. Condylar movements were not detected and the mouth opening of the patient was 2 mm. (Figure1: d). The dentition on the right side appeared enlarged with Class II molar relation and class I molar relation on left side. The right buccal mucosa showed a pebbly appearance. Further intraoral examination was not possible due to the restricted mouth opening. There was no associated pain, paresthesia or regional lymphadenopathy.

---



**Figure 1.**

Clinical impression was directed towards multiple etiologies suggestive of post ear infection TMJ ankylosis or post-surgery TMJ ankylosis with congenital hemifacial hyperplasia.

Routine radiographic examination showed features of anatomically deformed right temporomandibular joint showing bony ankylosis. There was apparent overgrowth of maxilla and mandible on right side with inferior displacement and altered trabecular pattern. Other radiological features include inferior alveolar canal enlargement and multiple missing teeth (Figure 2).

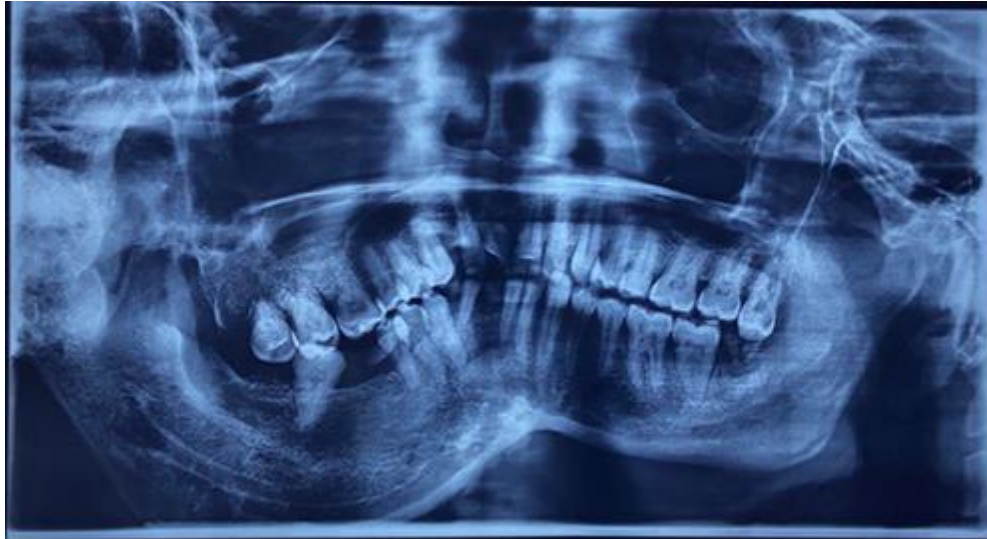CT examination of facial bone revealed enlargement and sclerosis involving greater wing of right sphenoid, temporal bone, right zygoma, right maxilla, zygomatic arch, mandible right hemicondyle ramus and body with enlargement of teeth on right side associated with diffuse lipomatous enlargement of soft tissues suggestive of true hemifacial hyperplasia. (Figure 3: a, b)

MRI was taken which suggested Lipomatous enlargement of soft tissues on the right side of face and CT angiography showed medially distorted position of internal maxillary and superficial temporal artery due to the TMJ mass. (Figure 4: a,b,c)

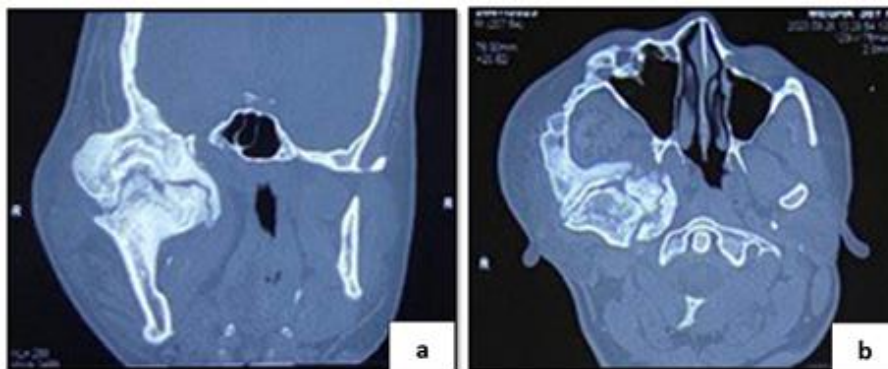
Thus, the radiological diagnosis of the condition was of true congenital hemifacial hyperplasia of face with Sawhney's type 3 TMJ ankylosis on right side.

GA administered through fiberoptic nasotracheal awake intubation. Under external carotid artery control, the ankylotic mass in relation to the right Temporomandibular joint was exposed through preauricular incision with temporal extension. Debulking of zygomatic bone was done by resecting the exophytic bony growth. After marking the upper osteotomy cut, the lower cut was placed 1.5 cm below the zygomatic arch since the normal architecture was not clear. The osteotomy cuts were done using micromotor and handpiece, osteotome and piezosurgery device. The ankylotic mass was resected in multiple segments along with ipsilateral coronoidectomy (figure 5b). The bone in the ankylotic mass was eburnated and was difficult to cut with all the three cutting instruments. The excess skin and subcutaneous fat adjacent to the surgical site was used as interpositional material, thus avoiding a second surgical donor site, which was folded and placed between the bony ends. (Figure 5c). Surgical drain placed and closure was done in layers. After the surgery, early mobilization and aggressive physiotherapy was advised.

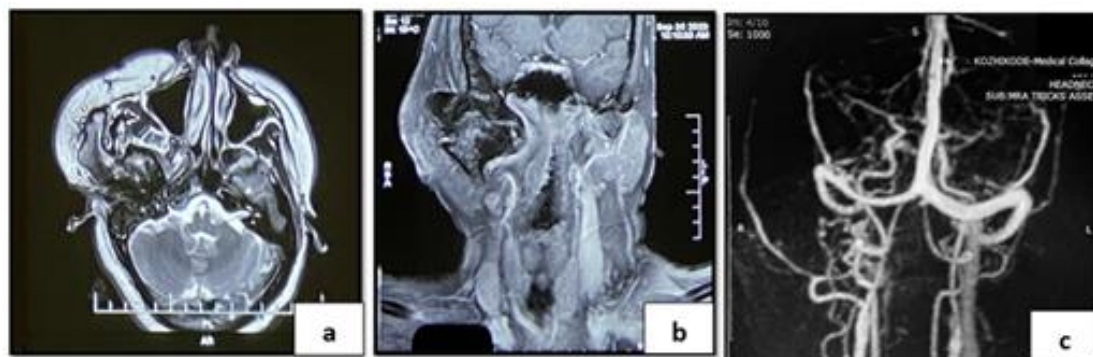Histopathologic examination revealed mature lamellated bone intermingled with adipose tissue with diffuse fatty infiltration into surrounding soft tissues as well. (Figure 6: a, b)



**Figure 2:** OPG-Right Temporomandibular joint with bony ankylosis noted, TMJ space cannot be appreciated. Right side Coronoid process appears irregular and relatively longer. Apparent overgrowth of maxilla and mandible on right side showing inferior displacement with altered trabecular pattern. Right inferior alveolar canal appears enlarged with missing 18,41,46,48.

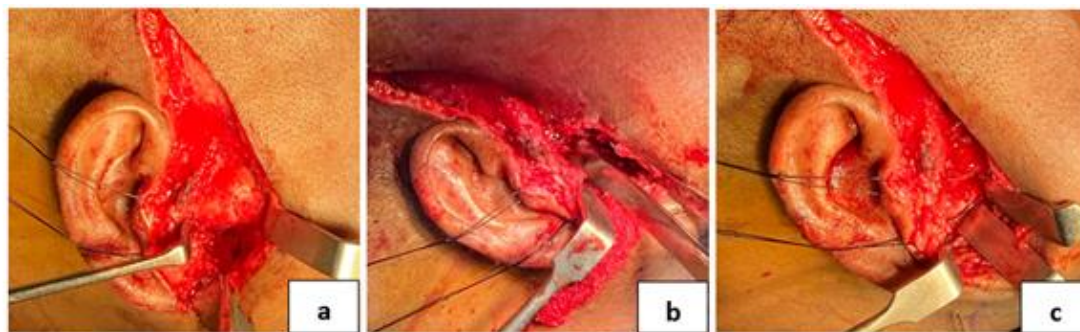


**Figure 3.** CT- facial bones: (a,b) showing Sawhney's type III TMJ ankylosis involving greater wing of right sphenoid, temporal bone, right zygoma, zygomatic arch, maxilla, mandible right hemicondyle ramus and body with diffuse lipomatous enlargement of soft tissues.

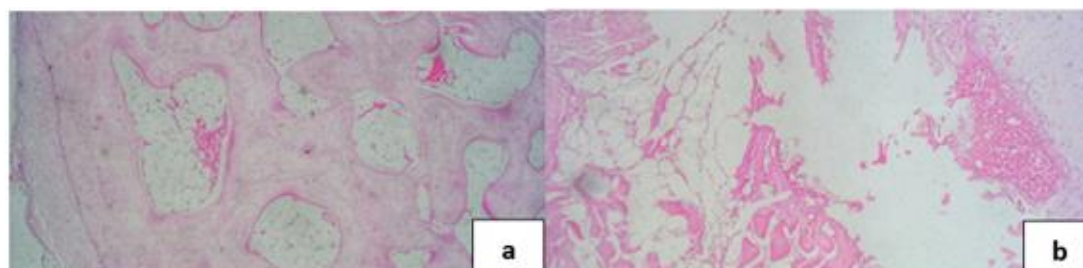


**Figure 4.** - MRI: Figure 4a and 4b: Lipomatous enlargement of soft tissues on the right side of face extending from temporal bone below to level of mandibular ramus involving temporalis muscle, masseter muscle, pterygoid muscles, and muscles of facial expression, right hemi tongue, with gross enlargement of right mandible condyle with degeneration. Figure 4c: MRI angiography showing splaying of internal maxillary and superficial temporal artery in relation to right TMJ region.





**Figure 5:** (a) Intraoperative preauricular approach showing ankylotic mass in relation to right TMJ region. (b) Resection of ankylotic mass using osteotome (c) Interpositional arthroplasty using skin subcutaneous fat graft.



**Figure 6:** (a) Mature lamellated bone intermingled with adipose tissue (b) Diffuse fatty infiltration into surrounding tissue

### III. Discussion

Hemifacial hyperplasia is characterized by unilateral overgrowth of facial tissues, first described by Merkel in 1822. Bou-Haidar et al considered congenital hemifacial lipomatosis to be a subtype of partial hemifacial hyperplasia in which not all included structures were enlarged<sup>4</sup>. This was contradictory to our findings showing involvement of viscerocranium extending from temporal bone to the mandible with associated soft tissues and muscles suggestive of true hemifacial hyperplasia.

The main characteristics of congenital infiltrative lipomatosis of face described by Slavin et al (1983) include non-encapsulated lesion containing mature lipocytes, fat tissue infiltration of adjacent muscles and soft tissue organs, absence of malignant characteristics and lipoblasts, increased number of nerve bundles and vessels with fibrous elements and adjacent bone hypertrophy which was consistent with our findings<sup>1</sup>.

A. Melethil et al (2022) reported a case with clinical and radiological evidence of a 34-year-old female patient who reported with a swelling in the left middle third of the face with exophytic temporomandibular joint (TMJ) ankylosis and eluded the role of infiltrative lipomatosis in the development of TMJ ankylosis considering it as an etiological factor<sup>5</sup>.

The potential for exophytic bone formation and development of ankylosis may result from osseous tissue proliferation either on its own or because of surgical intervention, thus the consideration for multiple etiological factors in this case. Sahai et al also opined about the importance of radiological evidence in recognizing the condition, which was correlated with our study. CT being the primary investigation, soft tissue and bony changes were evident and MRI confirmed the predominantly fatty nature of the condition, with the exclusion of lymphatic or vascular malformations<sup>6</sup>.

Recent research has suggested a more conservative course of action including liposuction and elevation of drooping upper lip, whereas earlier studies supported aggressive surgical treatment<sup>7</sup>. Considering the patient's complaint and need, only functional correction was done. Due to anticipated facial nerve injury and relapses following surgical intervention, soft tissue debulking was not considered in our treatment plan. Literature suggests that targeted chemotherapy using Imatinib and celecoxib in such cases helps prevent disease progression<sup>8</sup>. Other treatment options include multistep surgical approach where initial soft tissue debulking is done, followed by orthognathic surgery to correct the skeletal asymmetry and malocclusion<sup>9</sup>.

### IV. Conclusion

Given the small number of cases that have been documented in the literature, making it a rare occurrence, our report and literature analysis are intended to provide additional recommendations for the diagnosis and management of this condition.

### References

- [1]. Slavin Sa, Baker Dc, Mccarthy Jg, Mufarrij A. Congenital Infiltrating Lipomatosis Of The Face: Clinicopathologic Evaluation And Treatment. *Plast Reconstr Surg*. 1983 Aug;72(2):158-64. Doi: 10.1097/00006534-198308000-00006. Pmid: 6192455.
- [2]. Sun R, Sun L, Li G, Sun Z, Zhao Y, Ma X, Sun C. Congenital Infiltrating Lipomatosis Of The Face: A Subtype Of Hemifacial Hyperplasia. *Int J Pediatr Otorhinolaryngol*. 2019 Oct; 125:107-112. Doi: 10.1016/J.Ijporl.2019.06.032. Epub 2019 Jun 30. Pmid: 31280031.
- [3]. Maclellan Ra, Luks Vl, Vivero Mp, Mulliken Jb, Zurakowski D, Padwa Bl, Warman Ml, Greene Ak, Kurek Kc. Pik3ca Activating Mutations In Facial Infiltrating Lipomatosis. *Plast Reconstr Surg*. 2014 Jan;133(1):12e-19e. Doi: 10.1097/01.Prs.0000436822.26709.7c. Pmid: 24374682.
- [4]. Bou-Haidar P, Taub P, Som P. Hemifacial Lipomatosis, A Possible Subtype Of Partial Hemifacial Hyperplasia: Ct And Mr Imaging Findings. *Ajnr Am J Neuroradiol*. 2010 May;31(5):891-3. Doi: 10.3174/Ajnr.A1857. Epub 2009 Nov 19. Pmid: 19926700; Pmcid: Pmc7964189.
- [5]. Melethil A, Menon S, Sham Me, Kumar V. Infiltrating Lipomatosis, An Etiology For Tmj Ankylosis? *J Oral Maxillofac Pathol*. 2022 Jul-Sep;26(3):404-407. Doi: 10.4103/Jomfp.Jomfp\_147\_21. Epub 2022 Oct 17. Pmid: 36588848; Pmcid: Pmc9802528.
- [6]. Sahai S, Rajan S, Singh N, Arora H. Congenital Infiltrating Lipomatosis Of The Face With Exophytic Temporomandibular Joint Ankylosis: A Case Report And Review Of The Literature. *Dentomaxillofac Radiol*. 2013;42(3):16128745. Doi: 10.1259/Dmfr/16128745. Epub 2012 Jan 12. Pmid: 22241871; Pmcid: Pmc3667539.
- [7]. Gupta R, Mukul Sk, Kumar P, Kumar A. Congenital Infiltrating Lipomatosis Of The Face With Temporomandibular Joint Ankylosis. *Natl J Maxillofac Surg*. 2020 Jan-Jun;11(1):117-120. Doi: 10.4103/Njms.Njms\_59\_17. Epub 2020 Jun 18. Pmid: 33041589; Pmcid: Pmc7518480.
- [8]. Tracy Jc, Klement Gl, Scott Ar. Interdisciplinary Management Of Congenital Infiltrating Lipomatosis. *Int J Pediatr Otorhinolaryngol*. 2013 Dec;77(12):2071-4. Doi: 10.1016/J.Ijporl.2013.08.008. Epub 2013 Aug 22. Pmid: 24035641.
- [9]. Kalantary S, Van De Castele E, Nadjmi N. Congenital Infiltrating Lipomatosis Of The Face: Case Report With Presentation Of A New Multistep Surgical Approach. *J Oral Maxillofac Surg*. 2018 Jun;76(6):1334-1343. Doi: 10.1016/J.Joms.2017.10.015. Epub 2017 Oct 16. Pmid: 29128477.