

## Rare Case Report Of Phyllodes Tumor Of Young Female

Dr Rushikesh Khadse

Intern Bavmc Pune (Mbbs)

Dr. Apurva Satav

Intern Bavmc Pune (Mbbs)

Dr Priti Punde

Intern Bavmc Pune (Mbbs)

Dr. Tejashree Sonawane

Senior Resident

Dept. Of General Surgery

Bavmc Pune

Dr. Ananta Kulkarni

Professor And Hod General Surgery

Bavmc Pune

---

### Abstract

Phyllodes tumor is benign breast cancer with malignant potential<sup>[1]</sup>. Histologically it is sarcoma<sup>[1,2]</sup>. Hereby report the phyllodes tumor, rarely seen in young adult of age 27 years. Who presented with lump in left breast occupying whole breast. Which slowly increased in size over a period of 1 year.

---

Date of Submission: 20-01-2024

Date of Acceptance: 30-01-2024

---

### I. Introduction

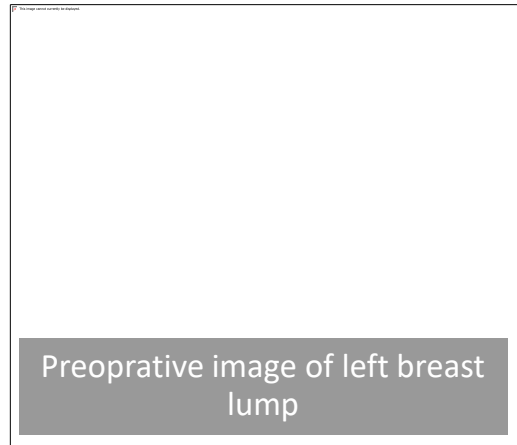
Phyllodes tumor is a rare tumor of breast in comparison to other histologic subtypes<sup>[1]</sup>. Accounting <1% of all breast malignancies<sup>[1,2]</sup> and it has an incidence of about 2.1 per million<sup>[3]</sup>. Usually occurs in 4th or 5th decades of life but this is rare case in young lady of 27 years old<sup>[1,3]</sup>. The bulk of this tumor is connective tissue with mixed gelatinous cystic and solid areas<sup>[3]</sup>. The only treatment option for this is surgical removal<sup>[3]</sup>

### II. Case report

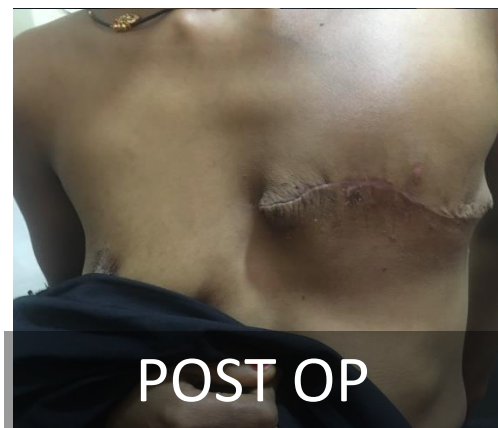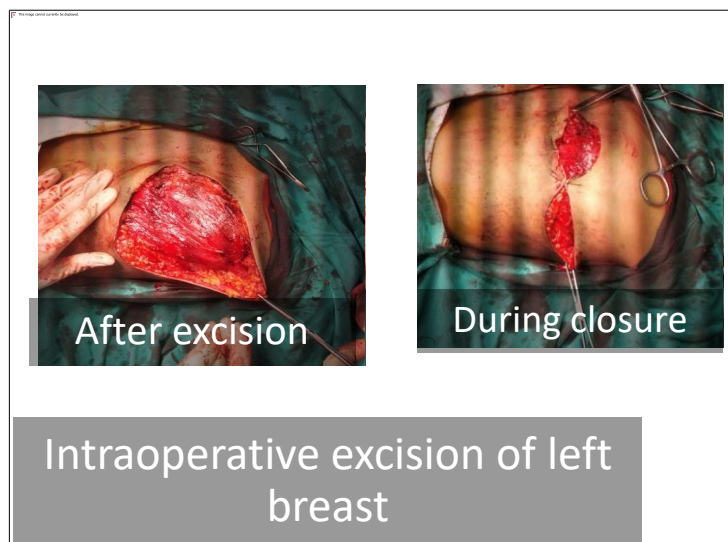
27 year old lady, married, with one issue presented to OPD with mass in left breast. Menses regular, using barrier method of contraception, had breast fed her baby adequately with no family history of breast cancer, Physical examination, no abnormalities detected.

Lump in the left breast had been gradually increasing over a period of 13 months. On breast examination lump of 18x16x10 cm occupying entire left breast, axillary lymph nodes not palpable, contralateral breast normal with no dilated veins on right breast, on left no complaints of pus discharge.

**On ultrasonography** of breast a large fairly well defined round to oval lesion with lobulated margins, heterogeneous echotexture and solid cystic components is seen involving near entire left breast. The lesion approximately measures 12.8x11.4x6.4 cm



The patient underwent simple mastectomy without axillary dissection



A breast tissue measuring 26x16x8 cm in dimensions was resected (fig 2). Deep margins displays butt out smooth surfaced nodules, cut surface is multi nodular and shows variable sized fleshy, soft to firm, off white to ash colored leafy nodules.

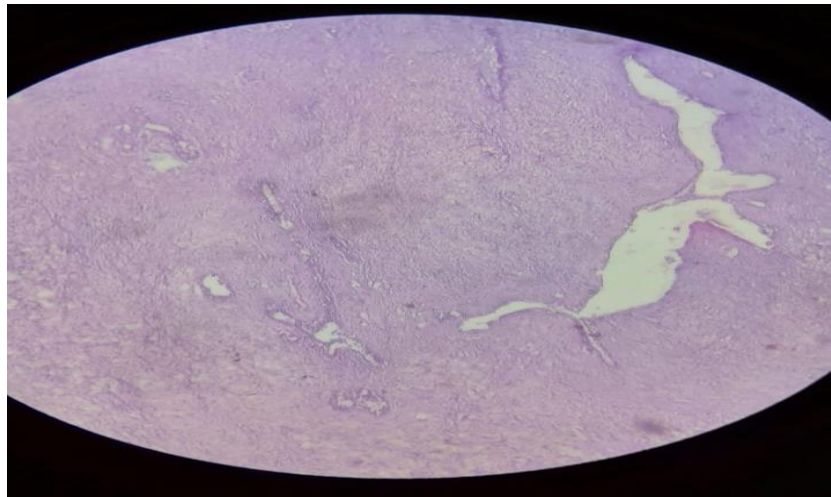
**HPE S/O** - Nipple areola appears normal slightly pushed to one side, on cut section whitish, lobulated, with slit like spaces tumor of size 15x12x6 bulges out. Cut section also shows serous yellow colour fluid and few mucoid areas. Tumor is located 0.1cm from outlined skin and 0.3cm away from base.

**Microscopy :-** section shows variable sized, predominately compressed double layered ducts forming intra canalicular pattern surrounded by stroma which is cellular, fibromyxoid. At some places ducts are dilated.

They contain laceration and chronic inflammatory infiltrate.

27 year old lady operated on 26/12/2023

Specimen:- Excised sample of left breast



**Impression :-** s/o of benign phyllodes tumour

### III. Discussion:-

As well-known phyllodes tumor are usually found as an incidental findings during the examination of female breast. These tumors are usually well circumscribed and painless with an average size of 5 cm. But lesions measuring more than 30 cm have also been reported. While primarily a disease of females, reports of these tumors have been published in few case of male breast [4,5]. Phyllodes tumors peak incidence is between 30-40 years but can be occur at any age [6]. Etiology of these tumors remains unknown. The left breast is more commonly affected than right one as we can see in these case and other cases we treated. These tumors grow radially and compress the surrounding breast parenchyma, a false capsule is created, though which the tumor extends and grows into the rest of the healthy mammary tissue [7]. The overlying skin is shiny and translucent enough to reveal underlying veins at its initial presentation [3].

Ultimately tumor can cause ulcer or open wound on the skin. These tumors represents a character of sizable malignant sarcoma, taking a leaf like appearance on gross examination and cystic spaces on histological examination [8]. In most cases it mimics benign breast condition such as fibroadenoma making a diagnosis more challenging unless it grows to a large, ulcerative, hemorrhagic lesion. The incisional and excisional biopsies are definitive method for diagnosing phyllodes tumor, although core biopsy is reliable investigation for diagnosis. Complete surgical resection is a treatment of choice however particularly in borderline and malignant phyllodes tumor the extent of resection is controversial as they penetrate in the surrounding healthy tissue [9]. For this reason a wide local excision is done that must include a healthy breast tissue. No proven curative or palliative role in the management of these tumors was confirmed for neoadjuvant and adjuvant therapy, due to lack of tumor-free margins during the surgical resection, a recurrence rate of less than 13% is usually observed [10]

### IV. Conclusion :-

As accurate preoperative pathological diagnosis allows correct surgical planning and avoidance of reoperation. The value of FNAC in the diagnosis of phyllodes tumor remains controversial, but core needle biopsy has high sensitivity values [6]. Surgical management is although mainstay, and local recurrence in phyllodes tumor has been associated with inadequate local excision

### Reference :

- [1]. Yohe S Yeh It. Missed Diagnosis Of Phyllodes Tumor On Breast Biopsy Pathological Clue To Its Recognition Int J Surg Pathol 2008;16(2):137-42. Doi:10.1177/1066896907311378
- [2]. Faris-Eisner Gt, Small K, Swistel A, Ozerdem U, Talmor M. Immediate Implant Breast Reconstruction With Acellular Dermal Matrix For Treatment Of Large Recurrent Malignant Phyllodes Tumor. Aesthetic Plastic Surg. 2014;38(2):373-8 Doi:10.1007/S00266-014-0283-9
- [3]. Lanin Dr, Geibel J. Cystosarcoma Phyllodes's 2014 Available From [Medscape Article]
- [4]. Bapat K, Oropeza R, Sahoo S, Benign Phyllodes Tumor Of Male Breast. Breast J. 2002;8(2):115-6 Doi: 10.1046/J.1524-4741.2002.08209.X. [PubMed] [Crossref]
- [5]. Nielsen Vt, Andersen C, Phyllode Tumors Of The Male Breast . Histopathology 1987;11:761-2
- [6]. Salvadori B, Cusumano F, Del Bo R, Delledonne V, Grassi M, Rovini D, Et Al. Surgical Treatment Of Phyllodes Tumor Of Breast Cancer. 1989;63(12):2532-6.

- Doi:10.1002/1097-0142(19890615)63:12<2532::Aid-Cncr2820631229>3.0.Co;2-Q
- [7]. Adamietz B, Difference Between Phyllodes Tumor And Fibroadenoma Using Real Time Elastography. *Ultraschall Med.*2011;32(Suppl 2) :E75-9. Doi:10.1055/S-0031-1282024 [Pub Med] [Crossref] [Google Scholar]
- [8]. Parker Sj,Harries Sa. Phyllodes Tumors. *Postgrad Med J.*2001;77(909):428-35.Doi:10.1136/Pmj.77.909.428 [Pub Med] [Crossref] [Google Scholar]
- [9]. Ben Hassouna J, Bousquet G, Marsiglia H, Ray Coquard I, Magne N, Malard Y,Et Al. Phyllodes Tumor Of Breast. *Int J Radiat Oncol Biol Phys* 2008;70(2):492-500 Doi:10.1016/J.Ijrobp.2007.06.059 [Pub Med] [Crossref] [Google Scholar]
- [10]. Belkacemi Y, Bousquet G Marsiglia H,Ray Coquard I,Magne N,Malard Y,Et.Al.*Int.J. Radiat Oncol Biol Phys* 2008;70(2):492-500 Doi:10.1016/J.Ijrobp.2007.06.059 [Pub Med] [Crossref] [Google Scholar]