

# Role Of Multimodal Imaging In Optic Nerve Sheath Meningoma

Dr. Drusya Pamuru, Dr.G. Jayamadhury

Date of Submission: 25-12-2023

Date of Acceptance: 05-01-2024

## I. INTRODUCTION

Optic Nerve Sheath Meningiomas (ONSM) are rare benign neoplasms originating from the meningotheelial cells of the meninges surrounding the optic nerve.<sup>1</sup>The tumor may arise from either the intraorbital or intracanalicular portions of the optic nerve where there is a meningeal sheath. Although considered benign tumors, primary ONSMs cause slow, progressive vision loss secondary to compression of the adjacent optic nerve and its blood supply.<sup>2</sup> The incidence of ONSM is highest in adult women in the fourth or fifth decades of life, with women being three times more likely than men to be affected.<sup>3</sup>

## II. CASE REPORT

### HISTORY

A 55yr old female presented with protrusion of left eye ball with swelling of left side of face and diminution of vision since 1 year. Proptosis was painless, gradual, progressive and not associated with double vision or any history of trauma. No past history of thyroid disease.

### EXAMINATION

Best corrected visual acuity in right eye was 20/20, in left eye 20/80. Colour vision in both eye 21/21. Intraocular pressure in both eyes 14mm Hg. Left eye showed axial proptosis with no restriction of extra ocular movements. Hertel's exophthalmometry readings were right eye 12mm, left eye 20mm. Slit lamp biomicroscopy revealed anterior segment within normal limits. Pupils were round, regular and reacting to light. Fundus examination of right eye showed normal optic disc with 0.4 cup disc ratio and normal foveal reflex. Left eye showed normal optic disc with 0.4 cup disc ratio with mild elevation nasal and superior to disc and retinal folds temporal to disc (Paton's lines).

### INVESTIGATIONS

Thyroid function tests showed total T<sub>3</sub> 0.95ng/ml, total T<sub>4</sub> 6.53µg/dL, TSH 1.87mIU/L.

MRI T<sub>1</sub> weighted images showed well defined hypointense and T<sub>2</sub> weighted images showed hyperintense spindle shaped lesion measuring 2.3 x 1.3 cm in intraconal compartment of left orbit. The lesion is seen arising from optic nerve sheath displacing optic nerve medially suggestive of optic nerve sheath meningioma. SD OCT showed thinning of ganglion cell complex and circumpapillary retinal nerve fibre layer thinning.

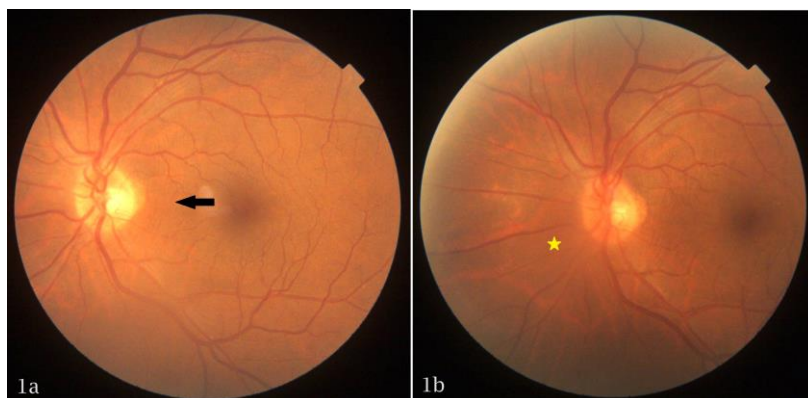


Figure 1a,1b : Color fundus image showing elevation nasal and superior to disc (yellow star) with retinal folds temporal to disc - Paton's lines(black arrow).

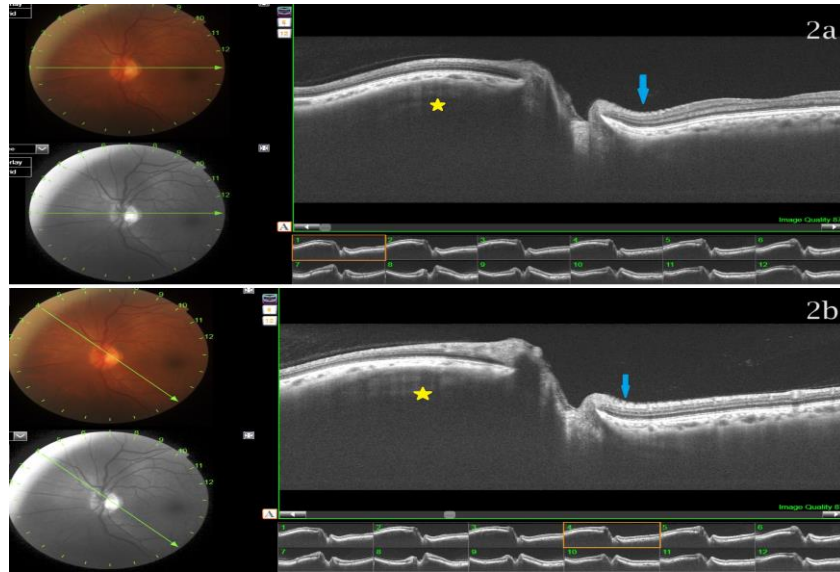
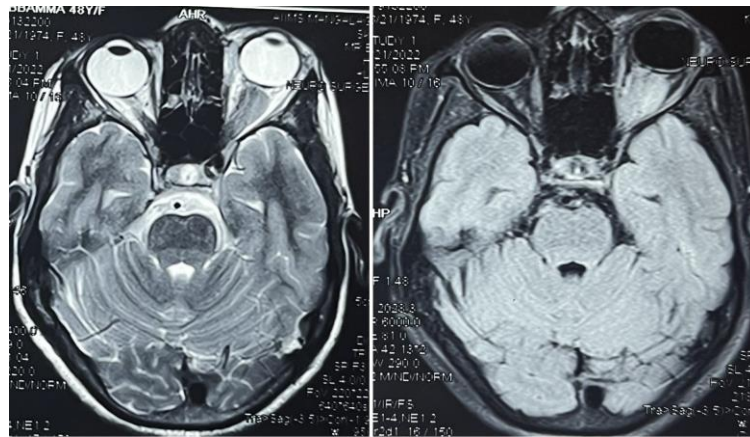


Figure 2a, 2b : Optical coherence tomography of left eye showing paton’s lines(blue arrow) temporal to disc and elevation nasal to disc.



3a

3b

Figure 3a, 3b: MRI showing well defined spindle shaped lesion hypointense on T1W and hyperintense on T2W.

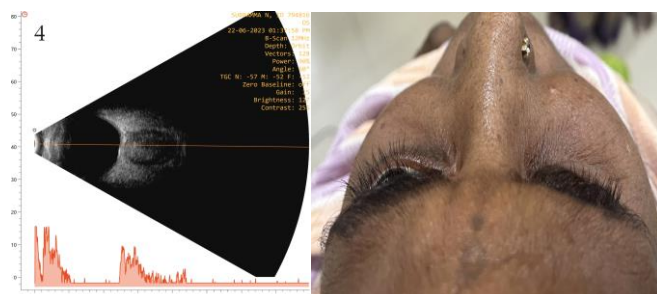


Figure 4: B scan showing moderate reflective homogenous lesion around optic nerve  
Figure 5: worm’s view showing left eye proptosis

### III. DISCUSSION

ONSMs constitute 2% of all orbital tumors and 1–2% of all meningiomas.<sup>6</sup>The incidence of ONSM is highest in adult women in the fourth or fifth decades of life. Though most cases of ONSM are idiopathic, the exact cause has not yet been determined.<sup>5</sup>Meningiomas have a history of being linked to ionizing radiation exposure. ONSM have also been associated with neurofibromatosis type 2.<sup>4</sup>

Typical symptoms in orbital meningiomas are reduced visual acuity followed by visual field defect, diplopia, proptosis, and optic disc swelling or atrophy.<sup>7</sup>

Management options include observation, surgical excision, or radiation therapy.<sup>5,7</sup> Radiation therapy may be considered for ONSM if intervention is required for preventing further visual loss. Surgical intervention is generally not recommended for eyes with useful vision due to the risk of post-operative blindness. Surgery may worsen the vision because of the common pial blood supply shared by the optic nerve and the ONSM.

As the patient in our situation has good visual acuity, we decided to examine and perform a three-monthly follow-up.

#### **IV. CONCLUSION**

With advent of newer investigative modalities we can diagnose optic nerve sheath meningioma and monitor the visual function based on the retinal nerve fibre layer thickness which correlates with early visual damage.

#### **REFERENCES**

- [1]. Frisen L, Hoyt Wf, Tengroth Bm. Optociliary Veins, Disc Pallor And Visual Loss: A Triad Of Signs Indicating Spheno - Orbital Meningioma. *Acta Ophthalmologica*. 1973 Apr;51(2):241-9.
- [2]. Biousse V, Bruce Bb, Newman Nj. Ophthalmoscopy In The 21st Century: The 2017 H. Houston Merritt Lecture. *Neurology*. 2018 Jan 23;90(4):167-75.
- [3]. Hong S, Usami K, Hirokawa D, Ogiwara H. Pediatric Meningiomas: A Report Of 5 Cases And Review Of Literature. *Child's Nervous System*. 2019 Nov;35:2219-25.
- [4]. Shaikh M, Khera P, Yadav T, Garg P. Dural Ectasia Of The Optic Nerve: A Rare Presentation In Neurofibromatosis Type I. *Journal Of Neurosciences In Rural Practice*. 2019 Apr;10(02):349-51.
- [5]. Eddleman Cs, Liu Jk. Optic Nerve Sheath Meningioma: Current Diagnosis And Treatment. *Neurosurgical Focus*. 2007 Nov 1;23(5):E4.
- [6]. Parker Rt, Ovens Ca, Fraser Cl, Samarawickrama C. Optic Nerve Sheath Meningiomas: Prevalence, Impact, And Management Strategies. *Eye And Brain*. 2018 Oct 24:85-99.
- [7]. Cantore Wa. Neural Orbital Tumors. *Current Opinion In Ophthalmology*. 2000 Oct 1;11(5):367-71.