

# Rhinoplasty with Bloodless Atraumatic Technique (Bat)

Sergio Noviello MD, FAACS, FWACS

Andrea Maroni MD

Massimiliano Tocchio MD

Carlo Chirilli MD

Tiziano Mirabello MD

Gualtiero Cogliandro MD

Sergio Noviello Academy - Milan - Italy

Corresponding Author:

Sergio Noviello MD, FAACS, FWACS

---

## Abstract

Rhinoplasty enhances facial harmony and the proportions of the nose. This procedure is still gaining in interest and certainly represents a large portion of aesthetic surgery practice with more than 18.000 procedures in Italy. Bloodless Atraumatic Technique is an innovation in surgery that reduces pain, discomfort and complications in most of the patients and which could be used in all areas of surgery. Given the mounting evidence that the use of BAT in any field of surgery is predictable, and safe we decided to implement the procedure in all rhinoplasties in our private practice.

Rhinoplasty procedure is the most difficult operation in the area of cosmetic surgery. To achieve functional and aesthetic unity, the surgeon requires strong and deep knowledge of both internal and functional anatomy.

The data we recently published revealed a significantly reduced incidence of pain, discomfort, swelling, bleeding, patient dissatisfaction with cosmetic appearance, iatrogenic deformity of the nose, airway obstruction in the BAT group, compared to the traditional technique, in 95% of patients.

In conclusion, BAT rhinoplasty offers objective improvements in terms of recovery, complications, and reoperation rates. Patient's experience is therefore undoubtedly more positive.

**Keywords:** rhinoplasty, atraumatic technique, complications.

---

Date of Submission: 04-09-2023

Date of acceptance: 16-09-2023

---

## I. Introduction

Rhinoplasty, sometimes referred to as a "nose job" or "nose reshaping" by patients, enhances facial harmony and the proportions of the nose. It can also correct impaired breathing caused by structural defects in the nose.

Rhinoplasty can treat nose size in relation to facial balance, nose width at the bridge or in the size and position of the nostrils, nose profile with visible humps or depressions on the bridge, nasal tip that is enlarged or bulbous, drooping, upturned or hooked, nostrils that are large, wide or upturned and nasal asymmetry.

If the patient desires a more symmetrical nose, keep in mind that everyone's face is asymmetric to some degree. Results may not be completely symmetric, although the goal is to create facial balance and correct proportion.

Rhinoplasty can correct also a deviated septum. Nose surgery that's done to improve an obstructed airway requires careful evaluation of the nasal structure as it relates to airflow and breathing. Correction of a deviated septum, one of the most common causes of breathing impairment, is achieved by adjusting the nasal structure to produce better alignment.

Rhinoplasty is a highly individualized procedure. The patients should do it for themselves, not to fulfill someone else's wish or to try to fit any sort of ideal image. Good candidates for rhinoplasty have a complete facial growth, they are physically healthy, they do not smoke, They have a positive outlook and realistic goals in mind for the improvement of their appearance.

During the rhinoplasty consultation the surgeon have to discuss about patient's surgical goals, with regard to

both appearance and breathing, medical conditions, drug allergies and previous medical treatments, current medications, vitamins, herbal supplements, alcohol, tobacco and drug use and previous surgeries.

The surgeon must evaluate patient's general health status and any pre-existing health conditions or risk factors, the options available for nose reshaping, examine and measure the parameters of the face, take digital pictures, discuss surgery options, recommend a course of treatment, analyse outcomes and any risks or potential complications.

The decision to have cosmetic surgery is personal. The patients will have to decide if the benefits will achieve their goals and if the risks and potential complications of rhinoplasty are acceptable.

The surgeon will explain in detail the risks associated with nose surgery. The patients will be asked to sign consent forms to ensure that They fully understand the procedure and any risks or potential complications.

Rhinoplasty surgery risks include anesthesia risks, infections, poor wound healing or scarring (above all in open rhinoplasty), change in skin sensation (numbness or pain), and even though is rare nasal septal perforation. Additional surgical treatment may be necessary to repair the septum but it may be impossible to correct this complication. Moreover difficulty breathing, unsatisfactory nasal appearance, skin discoloration and swelling, possibility of revisional surgery.

In preparing for rhinoplasty surgery, the patients may be asked to get a lab test, take certain medications or adjust their current medications, stop smoking, avoid taking aspirin, anti-inflammatory drugs and herbal supplements as they can increase bleeding

Rhinoplasty may be performed in an accredited office-based surgical facility, a licensed ambulatory surgical center or a hospital.

#### Surgical steps

Rhinoplasty surgery includes the following steps:

##### a. Anesthesia

Medications are administered for patient's comfort during the surgical procedure. The choices include intravenous sedation or general anesthesia. The surgeon will recommend the best choice for the single case.

##### b. The incision

Rhinoplasty is performed either using a closed procedure (our first choice), where incisions are hidden inside the nose, or an open procedure, where an incision is made across the columella, the narrow strip of tissue that separates the nostrils.

Through these incisions, the skin that covers the nasal bones and cartilages is gently raised, allowing access to reshape the structure of the nose.

##### c. Reshaping the nose structure

An overly large nose may be reduced by removing bone or cartilage. Sometimes surgery of the nose may require the addition of cartilage grafts. Most commonly, cartilage from the septum, the partition in the middle of the nose, is used for this purpose. Occasionally cartilage from the ear or rarely a section of rib cartilage can be used.

##### d. Correcting a deviated septum

If the septum is deviated, it can be straightened and the projections inside the nose reduced to improve breathing.

##### e. Closing the incision

Once the underlying structure of the nose is sculpted to the desired shape, nasal skin and tissue is redraped and incisions are closed. Additional incisions may be placed in the natural creases of the nostrils to alter their size. For a few days, splints and gauze packing may support the nose as it begins to heal.

During rhinoplasty recovery, a splint and/or packing may be placed inside the patient's nose and a splint or

bandages placed on the outside to support and protect the new structures during initial healing.

While initial swelling subsides within a few weeks, it may take up to a year for the new nasal contour to fully refine. During this time the patient may notice gradual changes in the appearance of the nose as it refines to a more permanent outcome.

Swelling may come and go and worsen in the morning during the first year following rhinoplasty surgery.

The surgeon will give specific instructions that may include: how to care for the surgical site, medications to apply or take orally to aid healing and reduce the potential for infection, specific concerns to look for at the surgical site or in the patient general health, and when to follow up with the cosmetic surgeon.

The results of rhinoplasty surgery will be long-lasting. As body ages, it is natural to have some gradual changes to the face of the patient including the nose. But most of the improvement should be relatively permanent. A healthy lifestyle and life-long sun protection will help extend the results of the new appearance.

Rhinoplasty is the most requested surgical procedure for aesthetic purposes by men in Italy - in sixth place in numerical terms (male and females patients) according to statistics released by the Italian Association of Aesthetic Plastic Surgery in 2019<sup>1</sup>. This procedure is still gaining in interest and certainly represents a large portion of aesthetic surgery practice with more than 20.560 procedures.

However, this operation is associated with significant pain and discomfort in the immediate postoperative period and may cause unwanted complications and side effects. Complications of rhinoplasty include patient dissatisfaction with cosmetic appearance, iatrogenic deformity of the nose, prolonged edema, airway obstruction, epistaxis, and rarely, complications of the soft tissue, such as fibrosis, necrosis, infection, mucosal inclusion cysts, and subcutaneous granulomas from foreign materials. Autologous grafts to the nose are commonly at risk for displacement, warping, or resorption. Alloplastic implants pose additional risk of extrusion and infection.

Residual and new airway obstruction is one of the most common complications following rhinoplasty. Sixty to 74 percent of patients undergoing revision rhinoplasty complain of airway obstruction. Objective findings correlate highly with patient complaints of obstruction.<sup>2-3</sup>

Patient dissatisfaction with cosmetic appearance following primary rhinoplasty may be a result of iatrogenic deformity or poor patient selection and management of expectations. Iatrogenic deformities include asymmetry, deviation, and a constellation of other structural problems. Commonly recognized deformities of the nasal dorsum and middle vault include saddle nose, scooped out, and Polly beak deformities. Issues involving the lower third of the nose include pinched tip, underrotated and overrotated tip, alar retraction, and collapse of the external valves.

Postoperative epistaxis, one of the most common complications, can be minimized with good perioperative blood pressure control and cessation of aspirin and other nonsteroidal antiinflammatory drugs for 1 week before and 2 weeks after nasal surgery.<sup>4-5</sup> Bleeding originating from the incision line or traumatized mucosa is generally mild and can be treated with head elevation, gentle pressure, or intranasal vasoconstrictors (e.g., oxymetazoline nasal spray). Continuous bleeding requiring repeated nasal packing may benefit from administration of desmopressin, a synthetic analogue of the antidiuretic hormone L-arginine vasopressin shown to increase coagulation activity through a rise in plasma concentrations of factor VIII and tissue plasminogen activator. Major or persistent epistaxis always warrants a return trip to the operating room for exploration.

Many Authors<sup>6-7-8</sup> in the literature have published about the level of pain, discomfort and complications in rhinoplasty in their experience. Despite mounting evidence that classical technique in rhinoplasty may actually have higher level of pain and discomfort rates, many surgeons are reluctant to change their practice to adopting a procedure that can lower or totally eliminate these negative side effects.

In November 2015, after more than a decade of work revisiting all of the techniques, instruments, materials and processes of cosmetic surgery, the senior Author presented one lecture, in one of the most innovative professional congress in cosmetic medicine and surgery of the United Arab Emirates, the Abu Dhabi International Conference & Exhibition in Dermatology & Aesthetics. This lecture represented the Bloodless Atraumatic Technique (BAT), one confirmed methodology that enabled 95% of patients to resume full normal activities within 72 hours of their surgery with evident reduction in postoperative pain level, discomfort and complications.

The Authors first reported in the literature the use of the Bloodless Atraumatic Technique (BAT)<sup>9</sup>, since then many have been interested in comparisons and outcomes with this technique. Authors have noted consistent decreased complication level rates after converting from classical rhinoplasty to atraumatic technique<sup>10-11-12</sup>.

Given the mounting evidence that the use of BAT is predictable, safe and could reduce our pain level, discomfort and complication rate, we decided to implement the procedure in all rhinoplasties in our private practice in Milan, Italy.

In this paper we examine our single accredited outpatient surgery center experience transitioning from the use of classical rhinoplasty to the use of BAT rhinoplasty.

Our method

Current techniques and procedures of medicine and cosmetic surgery allow many patients to improve their appearance quite often with immediate results, without therefore the need to suspend their social and work activities.

Today the goal is to preserve the essence of each person by trying to improve their own natural beauty.

Our approach or Logical Beauty Harmony<sup>13</sup> is not a magic formula but a pattern of thought, a flow of ideas in which the first one changes the second, and so on. We could consider it a conceptual algorithm that allows us to constantly re-evaluate the results in our patients and rethink how we can improve them. A real process of quality and continuous improvement of medicine and cosmetic surgery procedures with the aim of creating harmony and balance.

Each physician develops a personal definition of the concept of beauty. And inevitably their patients mirror this frame of reference. A modern scheme should allow natural results, not necessarily linked to a marked rejuvenation, but ideal and in harmony with any age, without evident signs of surgery or artificiality.

A sophisticated concept of beauty, nowadays, must be firmly supported by studies of anatomy and pathophysiology of aging, validated by international scientific literature<sup>14-15-16</sup>. Every medical treatment or surgical technique can or better must be constantly modified by new knowledge and acquisitions with the aim of reducing pain, operating times, complications and adverse events, increasing comfort and improving the patient experience.

The whole process must always and in any case be re-evaluated by the doctor or surgeon, analyzing every single aspect, the results, the patient's opinion, his experience and above all his smile.

Our vision coincides precisely with the latter aspect which results from the improvement of the quality of life. Logical Beauty Harmony adapts and accompanies patients in each new phase of their own harmony in order to achieve the desired result or change.

#### Bloodless Atraumatic Technique (BAT) in Rhinoplasty

Rhinoplasty procedure is the most difficult operation in the area of cosmetic surgery<sup>17-18</sup>. To achieve functional and aesthetic unity, the surgeon requires strong and deep knowledge of both internal and functional anatomy. Bloodless Atraumatic Technique requires an even more in-depth knowledge of the clinical anatomy of the nose and the entire face. To this end, we strongly suggest attending cadaver dissection courses.

Capable surgeons specializing in rhinoplasty usually have no problem using a closed technique or endonasal approach, but unskilled surgeons and beginners to cosmetic surgery may hold to be true that the open technique or extranasal approach is easier and initially gives them a better view of the anatomical structures. However it is challenging in many aspects.

In the closed technique we have three main incisions to enter the nose: the intercartilaginous incision, the intracartilaginous incision and the margin incision. For primary rhinoplasties, the intercartilaginous and intracartilaginous approaches are generally suitable. The margin incision is made only when the luxation

technique of the lower cartilages is to be used:

secondary rhinoplasties, large boxy tips or complex cases. If the surgeon has thorough knowledge of the internal nasal valves and the mucosa are not violated, large portions of the triangular and lower cartilage can be removed without compromising nasal function and airway. The whole bony and cartilaginous nasal framework can be exposed, dissected and reshaped using the closed technique. Similarly, cartilage pieces of many different shapes and sizes can be reimplanted through this approach to achieve a more aesthetic nasal dorsum and tip, and fixed in place with stiches or fibrin glue.

In our experience the open technique sets aside some side effects: a scar in the columella, prolonged edema, possible distortions and fibrosis occurring in the soft tissue and nasal tip until wound healing is completed, and surgical look. Therefore We consider the extranasal approach in very complex and secondary cases.

Most of the patients undergoing rhinoplasty at our clinic are both female and male patients between 20 and 50 years who have a tension nose with a variable hump, therefore We have described the essential steps for this type of surgical procedure.

#### The initial consultation appointment

During the initial consultation, the surgeon will have the opportunity to discuss the functional and cosmetic goals of the patient, will evaluate him or her as a candidate for rhinoplasty and clarify what the procedure can do for him or her. The patient should come to the consultation prepared in order to discuss complete medical history. See Table 1.

- Previous surgeries
- Past and present medical conditions
- Allergies and current medications
- Medical treatments received
- Medications currently taken
- History of smoking, steroid use, or other factors that may influence healing

TAB 1. Complete medical history

The collection of the patient's anamnesis proves to be extremely useful for the purposes of carrying out Bloodless Atraumatic Techniques as it allows to foresee or employ specific preventive measures in the single patient.

This will include informations about:

- Previous surgeries
- Past and present medical conditions
- Allergies and current medications
- Medical treatments received
- Medications currently taken
- History of smoking, steroid use, or other factors that may influence healing

The surgeon will examine the external nose, with measurement of the nasofacial and nasolabial angle and other parameters in the area of facial morphometry.

The following examinations should be performed before any rhinoplasty procedure:

- Rhinoscopic examination of the anterior and posterior nasal regions
- Examination of the nasal mucosa, skin and history
- Endoscopic examination of the nasal and nasopharyngeal passages

- Rhinomanometry with and without detumescence
- Allergy tests
- X-ray or tomography of the nose at least in two planes (occipitomenital and lateral)
- Blood tests
- ECG

The surgeon will photograph the nose for medical record. Refer to the international literature in order to perform the pictures in a suitable manner.

#### Surgical Planning

The procedure is performed under general endotracheal anesthesia or in selected cases in local anesthesia plus sedation. Before the operation, the surgeon should discuss thoroughly with the patient the anatomical features, the changes desired, the expectations, the methods to fulfill these changes, the functional improvement and last but not least of importance are given detailed instructions on the precautions to be taken after surgery.

In order to be considered beautiful, each element of a face must have precise relationships, angles, and relationships with other structures. Refer to the Logical Beauty Harmony Principles in order to identify harmony and balance in planning the nasal procedure<sup>13</sup>.

#### Disinfection

The entire facial skin and the nasal vestibule are disinfected with a 1% chlorhexidine solution.

#### Local Anesthetic Injection Technique

Following disinfection of the external nose and the nasal vestibule, 30 ml of a solution (See Table 2) consisting of 2% Lidocaine (20 ml) with sterile saline 0.9% (10 ml), Epinephrine 1:100,000 (0.5 ml) and Tranexamic acid 1% (2,5 ml)<sup>19</sup> is infiltrated as follows:

- base of the columella (naso labial angle)
- k point where the nasal bones join the triangular cartilages
- membranous part of the septum of the nose
- nasal vestibule
- mucosa of the alar cartilages
- mucosa of the triangular cartilages
- mucosa of the septum
- infraorbital foramen
- supraorbital foramen and supratrochlear pedicle

- |  |
|--|
| <ul style="list-style-type: none"><li>• 2% Lidocaine (20 ml)</li><li>• sterile saline 0.9% (10 ml)</li><li>• Epinephrine 1:100,000 (0.5 ml)</li><li>• <u>Tranexamic acid</u> 1% (2,5 ml)</li></ul> |
|--|

TAB 2. Anesthetic Solution

The use of very small caliber needles (i.e. 30 - 33 Gauge) or blunt cannulas (i.e. 25 - 27 Gauge) allows the reduction of local trauma and bleeding of small vessels as well as the diffusion of the blood itself in the tissues with consequent presence of ecchymosis and subsequent triggering of inflammatory phenomena characterized above all by pain and swelling. The choice of materials, tools and devices aimed at reducing tissue trauma is extremely important in atraumatic techniques such as BAT. We strongly suggest atraumatic and complete injection of local anesthetic and vasoconstrictor (see Figure 1).

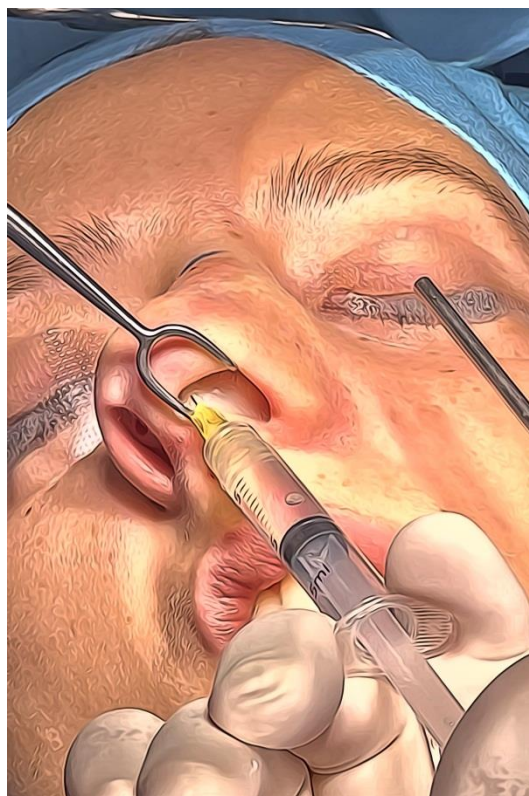


Fig. 1 - injection local anesthetic and vasoconstrictor

The surgeon now inserts a long cannula or needle between the lateral crus and the lateral nasal cartilage in order to detach the skin above the bony and cartilaginous structures of the nose as far as the frontonasal suture.

The surgeon then infiltrates the pathways of the basal osteotomies in a subcutaneous (external) and submucosal (internal) plane.

This procedure is carried out from both sides. The procedure provides anesthesia and also facilitates the subsequent dissection.

Local use of tranexamic acid may reduce blood loss comparably to intravenous prophylactic use with negligible risk of systemic adverse effects, There may not be one single ideal dosing regimen, but rather many possibilities adaptable for different surgical situations<sup>19</sup>.

#### Disinfection

The entire facial skin and the nasal vestibule are now again disinfected with a 1% chlorhexidine solution.

#### Surgical Technique

30 minutes after the beginning of the anesthetic infiltration is the correct waiting time in order to obtain the greatest vasoconstrictive effect and to prevent bleeding and blood soaking in the perinasal tissues; one of the fundamental aspect in bloodless and atraumatic techniques (BAT)<sup>20</sup>.

Two swabs are then inserted in the nasal cavities, at the level of the internal valves, with the nasal forceps bayonet shaped and Killian nasal speculum.

The surgical site is suctioned with Fergusson suction tube if needed, and the individual steps to be carried out during the operation are planned.

All of the hairs in the nasal vestibule are now removed with a Halstead-Mosquito forceps curved. This step prevents infection, gives the surgical team a good view of the nasal vestibule area and inform the surgeon about the level of anesthesia (above all if the patient is in local anesthetic modality plus sedation).

For this purpose, the nasal wing is pulled upwards with the sharp hooklet held in the left hand; simultaneously the middle finger presses the alar cartilage downward. The internal surfaces of the nasal wing are now under tension and the hairs can be eliminate without injuring the delicate mucosa. Subsequently, the mucosa are

cleaned and disinfected again with a moist gauze.

#### Incision Line

The assistant places the sharp hooklet on the right margin of the columella and pulls it laterally. Holding the number 15 scalpel in his or her right hand, and grasping vertically the anterior border of the septum with an Adson-Brown tissue forceps with his or her left hand the surgeon makes the transfixation incision at the level of the septum membranosum (see Figure 2).

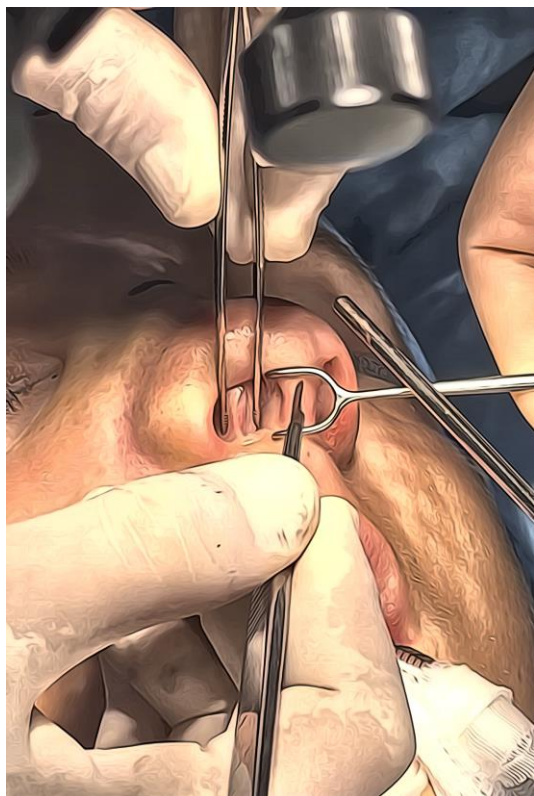


Fig. 2 - mucosal incision

This incision starts at the anterior nasal spine and proceeds upwards along the anterior edge of the septum. This major incision ends at the anterior margin of the top edge of the septum<sup>21</sup> (see Figure 3).



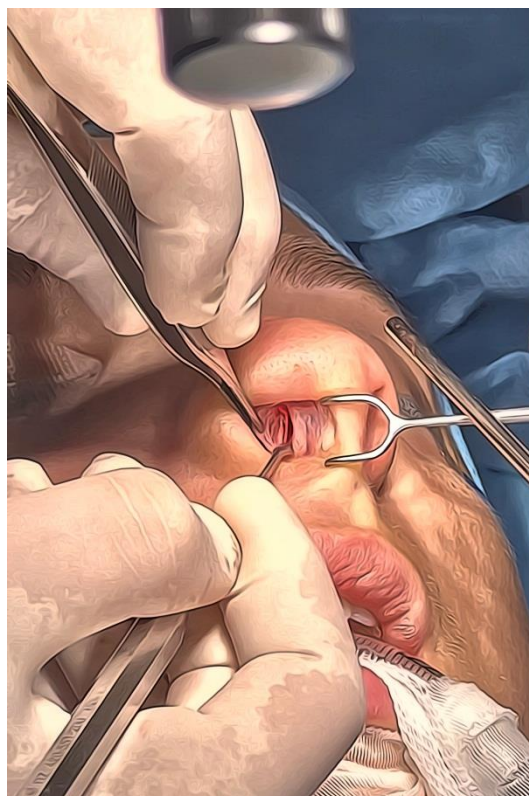


Fig. 3 - hemitransfix incision

Now the Cottle columella clamp is placed exactly at the level where the incision line on the left side will be later on at the level of the septum membranousum; it is then fixed in place with the screw mechanism. The Cottle columella clamp is held by the assistant slightly under tension and positioned vertically toward the front (see Figure 4).

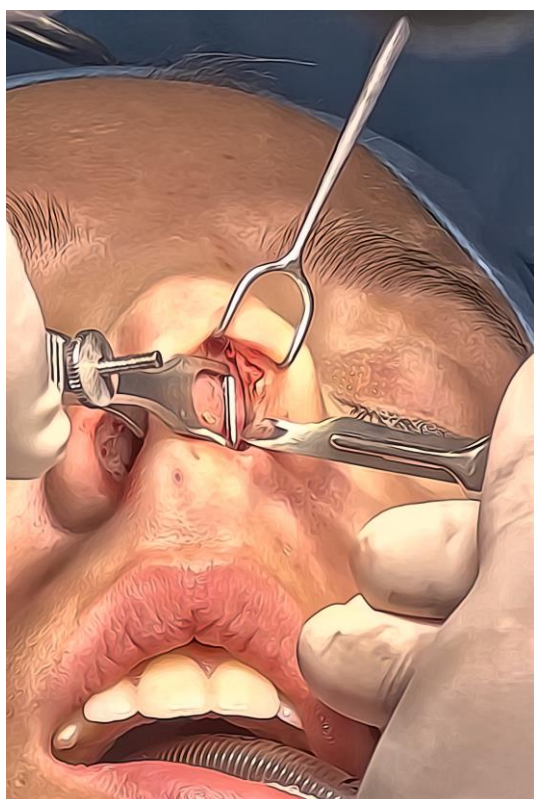


Fig. 4 - cottle columella clamp

Using his or her right hand, the assisting surgeon places the sharp hooklet in the free margin of the left nasal wing and pulls it cranially. Holding the number 15 scalpel in his or her right hand, the surgeon simultaneously makes the transfixation incision on the left side. This incision starts at the anterior nasal spine and proceeds upwards along the anterior edge of the columella clamp. This major incision ends at the anterior margin of the top edge of the septum<sup>22</sup>.

The Cottle columella clamp is now removed. Using his or her left hand, the surgeon places the sharp hooklet on the margin of the nasal wing and pulls it cranially. During this step the extended middle finger of the surgeon's left hand luxates the nasal wing in the direction of the orifice of the nasal vestibule. In this position, the transfixation incision can be extended laterally with little effort and extended to form an intercartilaginous or intracartilaginous incision bilaterally<sup>23</sup>.

The same procedure is carried out on the contralateral side. There are several variants of the incision line (i.e., margin vestibular incision, intracartilaginous incision, intercartilaginous incision). The greater the extent of nose shortening desired, the farther to the front the transfixation and intracartilaginous incisions should be placed.

Holding the number 15 scalpel in his or her right hand, and grasping vertically the anterior border of the septum with an Adson-Brown forceps the surgeon detaches the mucosa from the upper third of the septum bilaterally. This maneuver is facilitated along the pathway using first the Freer septum elevator and subsequently the Cottle septum elevator. This should be carried out with extreme caution, taking care not to injure the overlying mucosa. If septoplasty is necessary the detachment of the septum will be bilaterally complete.

#### Skeletonization

The next step is the skeletonization through the delicate detachment of the skin on the dorsum of the nose from the cartilage and bones up to the frontonasal suture. The surgeon's left hand is placed on the dorsum of the nose; the thumb and index finger serve as guide rails as the surgeon, holding the Metzenbaum dissecting scissors curved in his or her right hand, detaches the skin with gentle, spreading movements (see Figure 5).

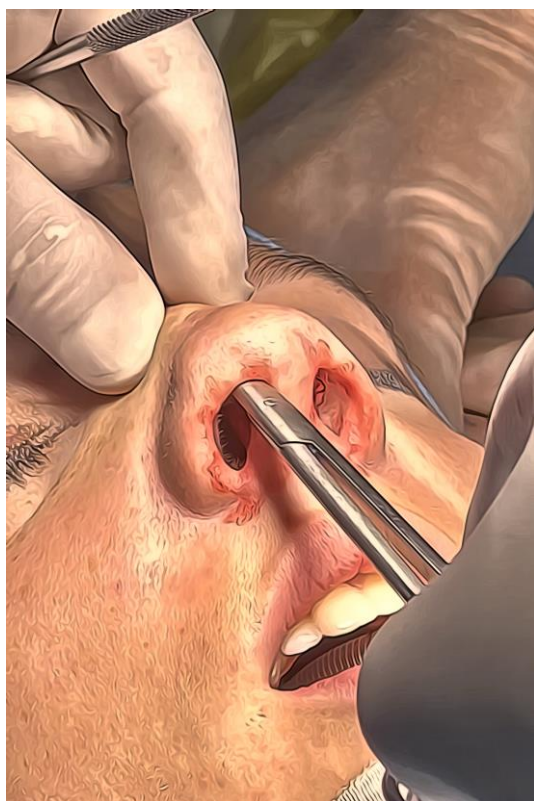


Fig. 5 - Skeletonization

During this procedure, the tip of the scissors always has contact to the underlying cartilage or bone. This dissection is made in two passages. The first one stops at the cartilage junction with the nasal bones (K point) in order to detach the pericondrium from the triangular cartilages and it is followed by the dissection under the

periosteum of the nasal bones done with the Joseph periosteal elevator<sup>24</sup>.

The second passage with the Metzenbaum dissecting scissors curved is performed up to the frontonasal suture and the limits of the dissection should be about 1.5 cm from the medial canthus. The detachment of the skin, pericondrium and periosteum from the dorsum of the nose is carried out from both the right and left intracartilaginous or intercartilaginous incisions.

Care must be taken to detach and remove all adhesions. This maneuver is facilitated using the Aufricht retractor with or without fiber optic and the Stevens scissors<sup>25</sup>. In this manner complete mobilization of the tissues on the dorsum of the nose can be achieved up to the glabella.

#### Correction of the Nasal Tip with the Eversion Method

This is the least traumatic method (our procedure of choice in the Bloodless Atraumatic Technique - BAT) and is sufficient for achieving excellent aesthetic results in most of the cases<sup>26-27-28</sup>. In patients where the primary complaint is a nasal hump or long nose, luxation of the alar cartilage or even open rhinoplasty is rarely the procedure of choice (see Figure 6).

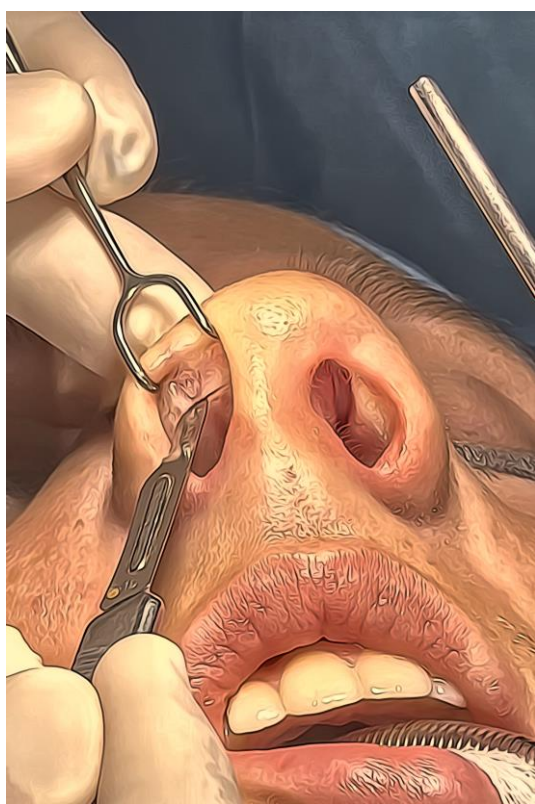

Fig. 6 - Eversion method

Using his or her right hand, the surgeon places the sharp hooklet in the free margin of the right nasal wing and pulls it cranially. With the help of the 5 mm diameter Fergusson aspirator the surgeon marks the mucosa of the right nasal wing pressing the tip of the aspirator close to the margin of the nasal wing.

Holding the number 15 scalpel in his or her right hand, the surgeon cuts the mucosa parallel to the free margin of the right nasal wing and detaches the mucosa from the lower alar cartilage up to the triangular cartilage caudal border using the Freer septum elevator<sup>29-30-31</sup>.

Subsequently holding the number 15 scalpel in his or her right hand, the surgeon cuts the lower alar cartilage parallel to the free margin of the right nasal wing and detaches the subcutaneous tissue from the lower cartilage up to the triangular cartilage lower border using the Freer septum elevator. Care must be taken to detach and remove all adhesions.



Once the lower cartilage is free the surgeon can easily remove the cephalic border of the lower alar cartilage (see Figure 7).

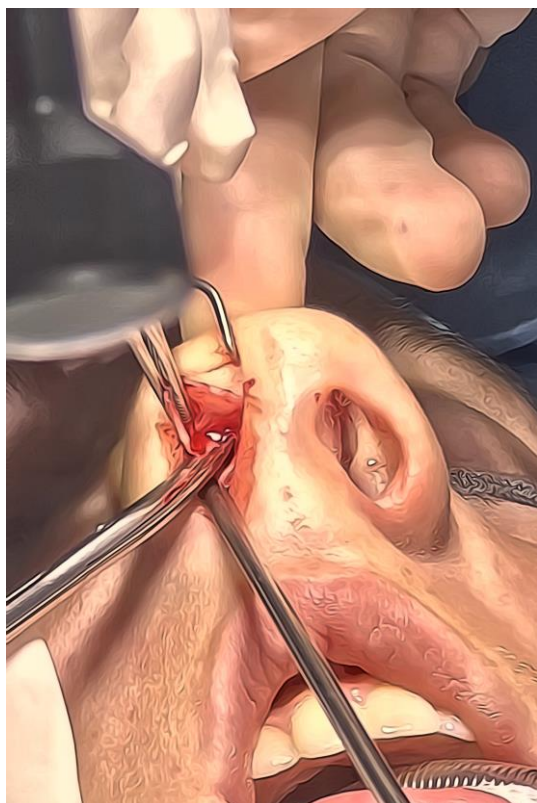


Fig. 7 - Eversion method and cartilage

Great care should be exercised here to leave the overlying skin and mucosa intact to prevent later contraction and stenosis. If the mucosa is kept intact, the posterior portion of the lower alar cartilage can be removed up to its attachment to the septal cartilage. If these precautions are followed, the patient will not experience any breathing difficulty or valvular stenosis postoperatively<sup>32-33</sup>.

A narrow anterior band of cartilage about 4-5 mm in width must remain in place. This resection causes a narrowing of the nasal wing and an elevation and shortening of the nasal tip. By means of the technique described above, the entire tip is rotated upwards. This procedure is now repeated on the contralateral side<sup>34</sup>.

Care should be taken here that the parts of the alar cartilage which are resected are identical in size on both sides in order to achieve homogeneous results on the nasal tip. Although it is more important to leave identical lower alar cartilages in place. Beginners are advised to initially take a conservative approach to cartilage removal. Radical resection, rarely suggested, should be attempted only by experienced surgeons<sup>35-36-37</sup>.

Stenosis can be prevented only if the mucosa remains intact. The sharp hooklet is now inserted again in the free alar margin; the nasal wing is then luxated to the front with the middle finger. The surgeon now has a good view of the surgical area and can remove pieces of connective tissue and excess mucosa from the dome of the nose with the Stevens scissors. This should be carried out with extreme caution, taking care not to injure the overlying skin. The extent of thinning to be undertaken here depends on the thickness of the skin of the nose.

#### Reducing the nasal length

Once the cephalic border of the lower alar cartilages has been removed the nasal length becomes shorter accordingly. Another anatomical structure responsible of the nasal length is the septum, the anterior border precisely.

Holding the sharp hooklet in his or her right hand, the assisting surgeon pulls the columella laterally and toward the front.

The surgeon now has a good view of the anterior border of the septal cartilage; using the number 15 scalpel and the Freer septum elevator he or she detaches cautiously the mucosa from the anterior edge of the septum, starting with the anterior nasal spine and continuing up to the cartilage dome<sup>38-39-40</sup>.

A correspondingly segment of the anterior border of the septal cartilage is resected from the nasal spine to the dome with the same scalpel. The size of this cartilage strip is naturally based on the desired degree of nasal shortening, the desired degree of tip rotation and the desired degree of tip projection.

This maneuver could be followed by careful resection of the dissected mucosa. Care should be taken here not to shorten the nose too radically in order to prevent distortions in the area around the tip of the nose and in order to avoid losing projection.

The procedure consist in removing mucosal strips having a width of about 2–3 mm each from the anterior and posterior margins of the transfixation incision, bilaterally, with the number 15 scalpel or Stevens scissors.

The surgeons have now succeeded in shortening, narrowing the nose and in rotating the tip region.

If septoplasty is necessary, it should be carry out after this surgical time. The surgeon should be careful not to mobilize the upper one third of the septum (L shape) as this could cause difficulties during the planned reduction of the nasal hump.

#### Hump reduction

With his or her left hand, the surgeon inserts the Aufricht retractor underneath the totally mobilized skin flap on top of the bony and cartilaginous nasal framework and pulls it upwards. Any remaining strips of fibrous connective tissue are removed with the Stevens scissors under direct vision. The bony-cartilaginous hump is now clearly visible.

Care should be taken to cleanly dissect the mucosa from the upper anterior border of the septal cartilage<sup>41-42-43</sup>. Using gently the Aufricht retractor the surgeon cuts with the Knight nasal scissors the triangular cartilages bilaterally along the septal junction in a straight fashion in order to separate the cartilaginous roof made up of the medial surfaces of the lateral nasal cartilages and the upper edge of the septal cartilage (see Figure 8).

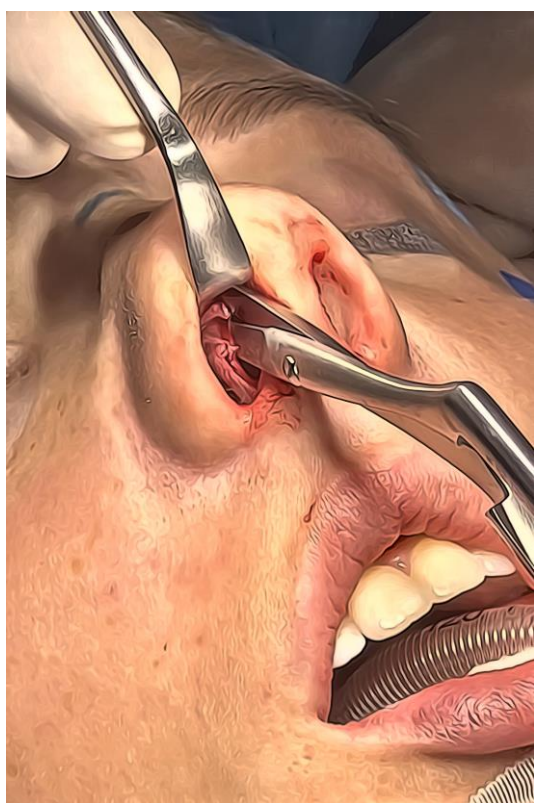


Fig. 8 - Triangular cartilages cutting

Using a Cottle septal scissors he or she cuts a thin strip of cartilage starting at the nasal vestibule and continuing up to the nasal bones (see Figure 9).

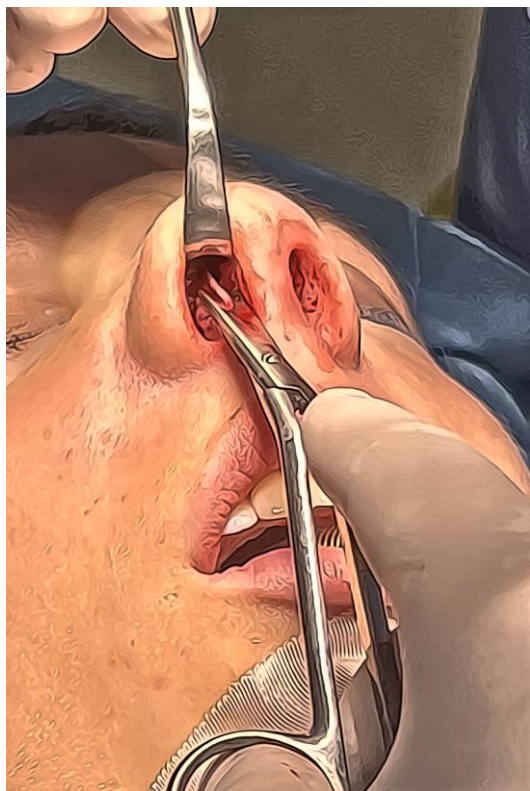

Fig. 9 - Removing cartilage hump

With the retractor still held under tension in an upward position, the surgeon now places the McIndoe nasal chisel with mushroom head into the incision lines<sup>44-45-46</sup>.

The retractor can now be removed. The thumb and index finger of the surgeon's left hand now serve simultaneously as guide rails for the McIndoe nasal chisel with mushroom head and as protection for the medial canthus. The assisting surgeon now applies uniform, sensitive hammer blows with a Mead mallet commensurate with the thickness and density of the bony structure (see Figure 10).

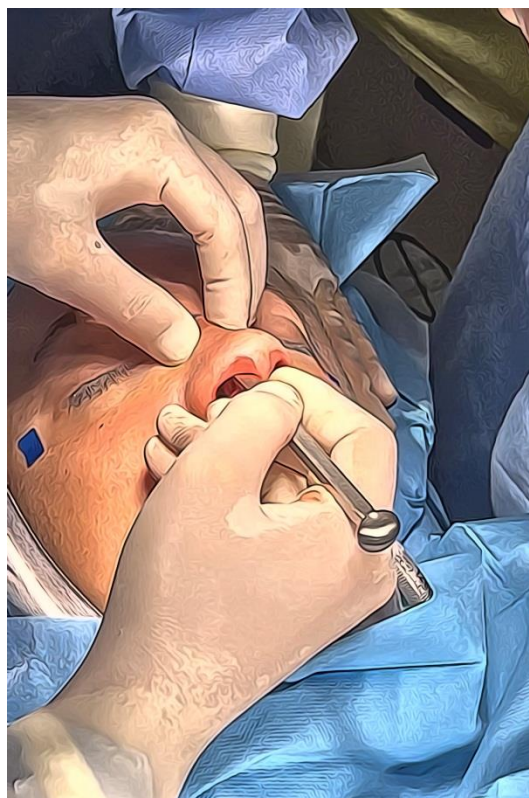


Fig. 10 - Removing bony hump

The extent of hump ablation is marked with a marker pen on the patient in the standing position (before the beginning of the surgery) and is geared to the lowest point in the region of the root of the nose. The hump should be eliminated totally in order to prevent later irregularities in the region of the dorsum of the nose.

The ablated hump is now removed with the small Kocher forceps. The sharp edges of the nasal bone are gently smoothed with a straight nasal rasp double ended. For this purpose, the nasal rasp is inserted from both sides over the intercartilaginous incision and under the skin on the dorsum of the nose. To prevent the instrument from slipping, the thumb and index finger of the surgeon's left hand again serve as guide rails.

#### Checking and Reshaping the nose

Any excess cartilage on the top edge of the septum is now removed with the delicate Cottle septal nasal scissors. The top edge of the septum, the shortened alar cartilages, and the open roof resulting from the osteotomy are all clearly visible.

Using the Freer septum elevator, the surgeon now detaches the mucosa from the newly created anterior edge of the septum without perforating it. If necessary, a small strip of septal cartilage can be resected in order to create a small trough in the tip region. This is to ensure optimal shaping of the supratip region.

Failure to dissect all the connective tissue structures in this region from the cartilages can produce unpleasant results – such as a supratip or parrot or polly beak – during the healing process in the following months.

The superfluous mucosa in the region of the front edge of the septum can now be resected. If the patient has requested a turned-up nose, it is necessary to remove correspondingly adequate portions of the cartilaginous and bony structures of the nose<sup>47</sup>.

When reshaping the nasal tip, the trick is to leave the mucosal and cartilage arch intact. Under this condition, a large part of the alar cartilage can be resected without any negative effects on the nasal breathing passages. Subsequently, all the cartilaginous edges, including the anterior edge of the septum, are trimmed again. The edges are carved with the Cottle nasal septal scissors. The amount of excess connective tissue removed depends on the extent of nasal thinning desired.

## Osteotomies

The paramedian, transversal and basal osteotomies are not performed until all the soft tissue reshaping has been completed. The osteotomies associated swelling and bleeding would make precise correction of the nasal soft tissues challenging.

Ten minutes before performing the osteotomies we strongly suggest to infiltrate the anesthetic solution again, along the pathway of the lines of fracture, in order to obtain the greatest vasoconstrictive effect and to prevent bleeding and blood soaking in the perinasal tissues; one of the aspect of paramount importance in bloodless and atraumatic techniques (BAT)<sup>19</sup>.

The surgical dressing is applied immediately after the osteotomies. This prevents major swelling, in particular in the periocular region and above all the medial canthus<sup>48</sup>.

The paramedian osteotomies are performed with the Rubin osteotome and They allow to create a bilateral medial line of fracture of the nasal bones along the pathway of the upper border of the septum up to the frontal bone.

The transversal osteotomies are performed with the Walter osteotome inserted percutaneously 1 cm medial to the inner canthus bilaterally and They permit to realize a line of fracture perpendicular on the nasal bones in order to mobilize the nose and to narrow the radix. Care should be taken not to interrupt completely the lines of fracture of the nasal bones in order to maintain stability of the new framework.

The bilateral basal osteotomies are performed with the Masing nasal chisel and are extended up to the medial canthus, forming with the transversal osteotomies a complete line of fracture. As a result, the frontal processes of the maxillary bone and the nasal bones are now totally mobile. Only a complete osteotomy on both sides guarantees that the nose can be ideally narrowed and the dorsum gently reshaped.

Osteotomies are indispensable in all rhinoplasty procedures performed to remove nasal humps and/or correct large or long noses. If the deformity consists only of a disharmonic nasal tip, it can be corrected under local anesthesia plus sedation without osteotomies by means of the eversion method.

To perform the paramedian osteotomy the surgeon places the Rubin osteotome close and parallel to the septum under the mucosal plane with his or her right hand. While performing the paramedian osteotomy on the right side, the surgeon guides the upper edge of the osteotome with his or her left hand with the thumb<sup>49</sup>. On the left side the osteotome is guided with the index finger of the surgeon's left hand.

The assisting surgeon must have a good feeling for bone thickness so that controlled hammer blows with the Mead mallet are applied, especially at the junction with the frontal bone.

To perform the transversal osteotomy the surgeon places the 2 mm Walter osteotome directly on the skin 1 cm medial to the inner canthus with his or her right hand. It is not necessary to cut the skin with a lancet. While performing the transversal osteotomy on the right side, the surgeon immobilize the nose with his or her left hand.

On the left side the osteotome is placed with his or her right hand and the nose immobilize again with his or her left hand. Attention must be paid to the transversal course of the osteotomy to prevent irregularities. The assisting surgeon applies controlled hammer blows with the Mead mallet.

To perform the basal osteotomy the surgeon places the Masing nasal chisel at the most basal point of the anterior nasal aperture at the level of the inferior turbinate with his or her right hand. It is mandatory in the rhinoplasty with Bloodless Atraumatic Technique (BAT) to predissect the mucosa and the Sub-SMAS plane along the pathway of the line of fracture, in order to prevent trauma, bleeding and blood soaking in the perinasal tissues (see Figure 11).



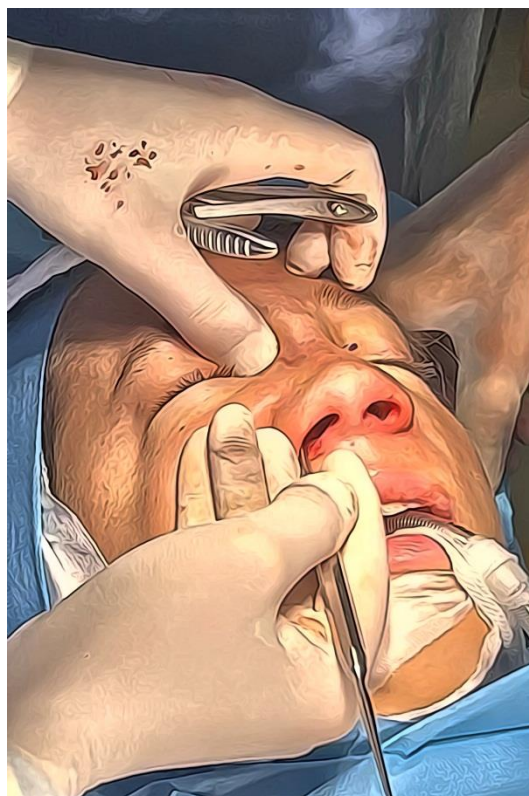

Fig. 11 - Sub-SMAS and mucosa dissection

While performing the basal osteotomy on the right side, the surgeon guides the lateral edge of the chisel with his or her left hand, with the thumb. On the left side the Masing nasal chisel is guided with the index finger of the surgeon's left hand (see Figure 12).

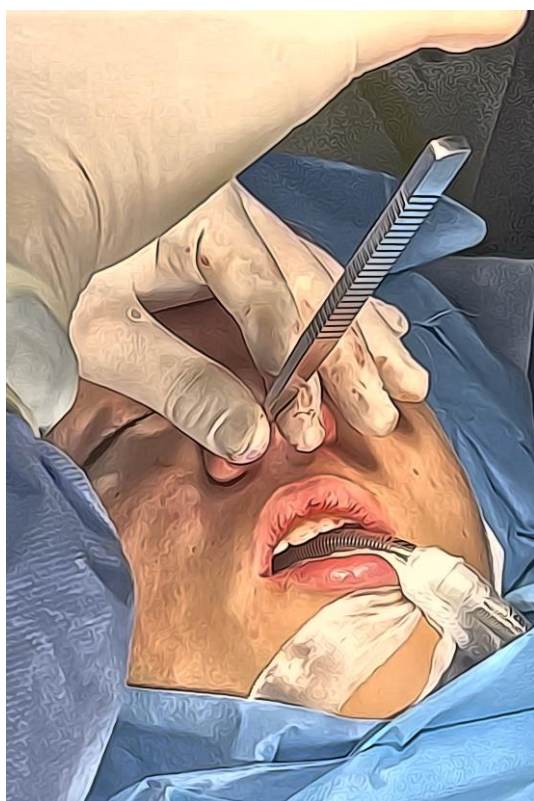

Fig. 12 - Osteotomies

Attention must be paid to the basal course of the osteotomy to prevent step formation. The assisting surgeon, again, must have an optimal feeling for bone thickness so that controlled hammer blows with the Mead mallet are applied, especially at the medial canthus and at the transition to the transversal osteotomy.

Swabs are removed and replaced saturated with naphazoline nitrate and applied for 10 minutes. The surgeon subsequently complete the fractures and mobilizes the nasal bones and the frontal processes of the maxillary bone along the osteotomy lines. This maneuver is realized firming hold delicately the dorsum of the nose with a gauze and making gentle lateral movements with the thumbs and index fingers of both hands. Care should be taken not to injure the mucosa in order to prevent trauma and bleeding<sup>50</sup>.

The nasal bone and the nose framework should be totally mobilized in order to achieve optimal cosmetic outcome.

The surgeon checks the dorsum of the nose and the alar region for irregularities. If necessary, small pieces of cartilage can be grafted on the dorsum, on the radix, on the tip or at the level of the nasolabial angle. The swabs saturated with naphazoline nitrate are now removed again with the nasal forceps bayonet shaped and the entire surgical area is suctioned with the Fergusson aspirator.

Finally, loose nasal packing is inserted and left in place for 24/48 h.

### Sutures

The mucosal incisions are now closed with interrupted 4/0 Vycril sutures. These sutures are absorbed and do not have to be removed later. The surgeon always starts suturing by placing two sutures at the columella and then continues suturing in the direction of the upper edge of the septum and the nasal wing, where 3 sutures are usually sufficient (see Figure 13).

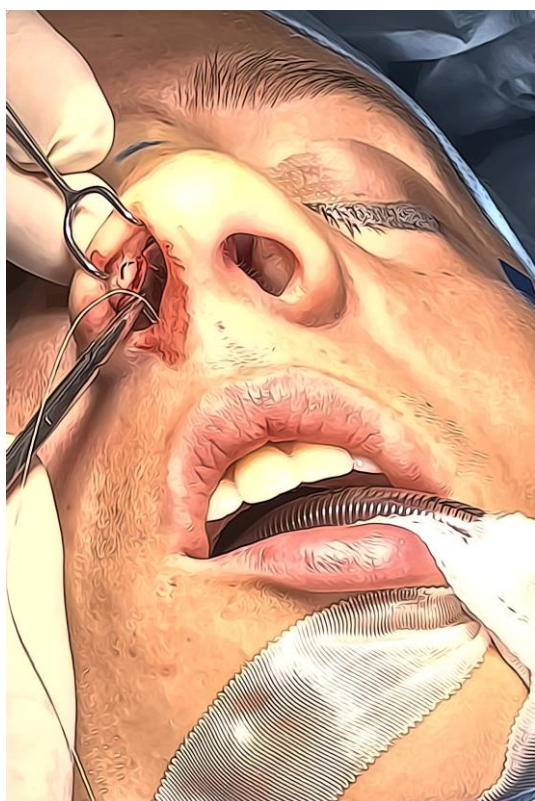

Fig. 13 - Sutures

Any fine corrections that still have to be made, for example cartilage graft in the nasal tip, the alar or triangular cartilage region, or in the dorsum of the nose, should be made before or after the osteotomies depending from the correction<sup>47</sup>.

For this purpose, the pieces of cartilage removed and then placed in a saline solution are now molded to form, crushed and implanted in the desired region, and secured with stitches or fibrin glue. If larger pieces of cartilage are required, they can be taken from the septum or rarely from the concha of the ear. Reduction of the nasal wings, if necessary, is also performed prior to the osteotomies. Therefore, bilaterally, a wedge-shaped piece of skin at the alar base is excised, above the nasal wing margin incision.

The incision is closed without any tension with a single stitch resorbable Monocril suture in the subcutis followed by interrupted 5/0 Nylon sutures. Beginners should take care when reducing the nasal wings due to the possibility of asymmetry of the base of the nose.

#### Dressing

The skin of the nose and cheeks is gently cleaned with a moist gauze with sterile saline. The surgeon now places with care overlapping Steri-Strips™ on the dorsum of the nose. He or she starts directly in front of the nasal tip surrounding the dome area and continues placing the strips on the supratip area up to the root of the nose. This anterior support creates compression of the tip and supratip region. It is important to prevent any bleeding in order to prevent swelling, infiltration, adhesion and subsequently a disharmonic polly or parrot beak.

A thermoplastic pad is now cut to fit perfectly the new shape of the nose, heated in hot water bath and the placed on the dorsum of the nose, supported with nontraumatic adhesive tape. The external dressing does not exert any shaping or corrective effect; it serves as protection.

And finally two soft swabs are inserted, with the Killian nasal speculum and the nasal forceps bayonet shaped, and left in place for 24/48 hours depending on the patient and the surgical intervention.

#### Postoperative Considerations

Antibiotic (azithromycin 500 mg) is administered orally for 3 days postoperatively to continue the antibiotic treatment instituted during the operation. Mild painkillers are sufficient to control postoperative discomfort and pain. Otherwise corticosteroids are used for one week to reduce swelling and to accelerate recovery. Very useful strategy in Bloodless Atraumatic Technique.

The patient should observe rest for 7 days after the operation and should limit facial expressions, chewing or laughing. The patient should sleep the first two or three days on his or her back with the head raised and supported by at least two pillows.

Twentyfour or fortyeight hours after the operation, the nasal swabs are taken out, the nose is gently and cautiously suctioned, and any crusts are removed. Nasal ointment applied to the nasal mucosa and saline lavage are recommended three times a day. Wound cleaning to remove wound secretions and crusts once a day is advisable.

During the first 3 weeks after the operation is not recommended to take hot baths, go out in the sun, go to the sauna or engage in strenuous sport activities. It takes about 4 to 6 months after the operation before the nose is completely recovered. Any touch up or corrections which may be necessary should not be undertaken until one year after the operation due to the evolving nasal healing process.

## Conclusion

Bloodless Atraumatic Technique (BAT) is an innovation in surgery that reduces pain, discomfort and complications in most of the patients and which could be used in all areas of surgery.

BAT arises from the evidence that much of the pain, the discomfort in the post-operative period and the complications of a surgical intervention are linked to the "traumatism of the tissues" and to the "blood" that inevitably comes out of the small vessels.

The determining aspects to be implemented in the Bloodless Atraumatic Techniques are therefore revealed:

- General endotracheal anesthesia
- Very strong and deep knowledge of both internal and functional anatomy
- Closed technique or endonasal approach
- Detailed and complete medical history
- Accurate examinations of the nasal regions and tests
- Atraumatic and complete injection of local anesthetic and vasoconstrictor
- Use of Tranexamic acid
- 30 minutes Waiting time
- Delicate surgical technique
- Correction of the nasal tip with the eversion method
- Further injection of local anesthetic and vasoconstrictor before performing the osteotomies
- Predissection of the mucosa and the Sub-SMAS plane along the pathway of the line of fracture

See Tab. 3

<ul style="list-style-type: none"><li>• General endotracheal anesthesia</li><li>• Very strong and deep knowledge of both internal and functional anatomy</li><li>• Closed technique or <u>endonasal</u> approach</li><li>• Detailed and complete medical history</li><li>• Accurate examinations of the nasal regions and tests</li><li>• Atraumatic injection of local anesthetic</li><li>• Use of <u>Tranexamic acid</u></li><li>• 30 minutes Waiting time</li><li>• Delicate surgical technique</li><li>• Correction of the nasal tip with the eversion method</li><li>• Further injection of local anesthetic and vasoconstrictor before performing the osteotomies</li><li>• <u>Predissection</u> of the mucosa and the Sub-SMAS plane along the pathway of the line of fracture</li></ul>
TAB 3. Determining aspects to be implemented in BAT

We therefore carried out a careful review of our classic operating technique, not only analytical but using the video footage of the surgery. Not only the surgical approach but also the instruments were reconsidered in order to make them as less traumatic as possible. The idea was precisely to reduce any microtrauma and avoid the spread of blood in the tissues. We started thinking microscopically.

The data we recently published revealed a significantly reduced incidence of pain, discomfort, swelling, bleeding, patient dissatisfaction with cosmetic appearance, iatrogenic deformity of the nose, airway obstruction in the BAT group, compared to the traditional technique, in 95% of patients.

In conclusion, rhinoplasty with Bloodless Atraumatic Technique (BAT) offers objective improvements in terms

of recovery, complications, and reoperation rates. Patient's experience is therefore undoubtedly more positive.

### Acknowledgements

The authors would like to thank the whole team of the BAT center in Milan, the entire surgical team of the Universo Salute - Vista Vision Clinical Center and all the professionals of the Sergio Noviello Academy.

### Conflicts of interest

The authors declare that there are no conflicts of interest.

### References

- [1]. [https://www.aicpe.org/wp-content/uploads/2020/05/statistiche\\_aicpe\\_2019.pdf](https://www.aicpe.org/wp-content/uploads/2020/05/statistiche_aicpe_2019.pdf)
- [2]. Sasindran V, Harikrishnan B, Mathew N. Cosmetic and Functional Outcomes of Septorhinoplasty. *Indian J Otolaryngol Head Neck Surg.* 2020 Jun;72(2):194-199. doi: 10.1007/s12070-019-01756-1. Epub 2019 Nov 5. PMID: 32551277; PMCID: PMC7276476.
- [3]. Vian HNK, Berger CAS, Barra DC, Perin AP. Revision rhinoplasty: physician-patient aesthetic and functional evaluation. *Braz J Otorhinolaryngol.* 2018 Nov-Dec;84(6):736-743. doi: 10.1016/j.bjorl.2017.08.011. Epub 2017 Sep 14. PMID: 29074124; PMCID: PMC9442826.
- [4]. Taha M, AlZubaidi HAA, Alrezqi AAA, Alsulbi AMO, Alrashdi AAA, Alzubaidi AAK, Alqarni ASA. Adult Knowledge About Postoperative Complications of Rhinoplasty in the Western Region of Saudi Arabia. *Cureus.* 2023 Apr 5;15(4):e37183. doi: 10.7759/cureus.37183. PMID: 37159787; PMCID: PMC10163213.
- [5]. Eşki E, Yılmaz İ. Pack free septoplasty: functional outcomes and complications. *Kulak Burun Bogaz Ihtis Derg.* 2015;25(5):275-8. doi: 10.5606/kbbihtisas.2015.01879. PMID: 26476515.
- [6]. Gadkaree SK, Shaye DA, Occhiogrosso J, Lee LN. Association Between Pain and Patient Satisfaction After Rhinoplasty. *JAMA Facial Plast Surg.* 2019 Dec 1;21(6):475-479. doi: 10.1001/jamafacial.2019.0808. PMID: 31536105; PMCID: PMC6753502.
- [7]. Sethi RKV, Lee LN, Quatela OE, Richburg KG, Shaye DA. Opioid Prescription Patterns After Rhinoplasty. *JAMA Facial Plast Surg.* 2019 Jan 1;21(1):76-77. doi: 10.1001/jamafacial.2018.0999. PMID: 30193252; PMCID: PMC6439729.
- [8]. Bagatin T, Bagatin D, Šakić L, Šakić K. IMPACT OF LOCAL INFILTRATION ANESTHESIA ON POSTOPERATIVE PAIN MANAGEMENT AFTER RHINOPLASTY IN DAY CARE SURGERY. *Acta Clin Croat.* 2019 Jun;58(Suppl 1):62-66. doi: 10.20471/acc.2019.58.s1.09. PMID: 31741561; PMCID: PMC6813470.
- [9]. Noviello S., De Santis A., Tocchio M. Face-lift with Bloodless Atraumatic Technique (BAT). Reducing downtime, side-effects and complications. *Plast Surg Mod Tech.* 2016;1
- [10]. Sciuto S. Modern rhinoplasty. *Acta Otorhinolaryngol Ital.* 2013 Jun;33(3):145. PMID: 23853408; PMCID: PMC3709527.
- [11]. Patel PN, Abdelwahab M, Most SP. A Review and Modification of Dorsal Preservation Rhinoplasty Techniques. *Facial Plast Surg Aesthet Med.* 2020 Mar/Apr;22(2):71-79. doi: 10.1089/fpsam.2020.0017. PMID: 32130066; PMCID: PMC7312707.
- [12]. Crosara PF, Nunes FB, Rodrigues DS, Figueiredo AR, Becker HM, Becker CG, Guimarães RE. Rhinoplasty Complications and Reoperations: Systematic Review. *Int Arch Otorhinolaryngol.* 2017 Jan;21(1):97-101. doi: 10.1055/s-0036-1586489. Epub 2016 Sep 22. PMID: 28050215; PMCID: PMC5205520.
- [13]. Noviello S, Gritzalas K, Maroni A, Tocchio M, Cogliandro G, Di Benedetto N. Logical Beauty Harmony and Natural Shape zones (NSz). *International Journal of Case Reports,* 2020
- [14]. 2020
- [15]. Kim TK, Jeong JY. Surgical anatomy for Asian rhinoplasty. *Arch Craniofac Surg.* 2019 Jun;20(3):147-157. doi: 10.7181/acfs.2019.00290. Epub 2019 Jun 20. PMID: 31256550; PMCID: PMC6615416.
- [16]. Kim TK, Jeong JY. Surgical anatomy for Asian rhinoplasty: Part II. *Arch Craniofac Surg.* 2020 Jun;21(3):143-155. doi: 10.7181/acfs.2020.00234. Epub 2020 Jun 29. PMID: 32630985; PMCID: PMC7349142.
- [17]. Kim TK, Jeong JY. Surgical anatomy for Asian rhinoplasty: Part III. *Arch Craniofac Surg.* 2023 Feb;24(1):1-9. doi: 10.7181/acfs.2022.01123. Epub 2023 Feb 20. PMID: 36858354; PMCID: PMC10009209.
- [18]. Yeolekar A, Qadri H. The Learning Curve in Surgical Practice and Its Applicability to Rhinoplasty. *Indian J Otolaryngol Head Neck Surg.* 2018 Mar;70(1):38-42. doi: 10.1007/s12070-017-1199-x. Epub 2017 Sep 6. PMID: 29456941; PMCID: PMC5807294.
- [19]. Bussi M, Palonta F, Toma S. Grafting in revision rhinoplasty. *Acta Otorhinolaryngol Ital.* 2013 Jun;33(3):183-9. PMID: 23853414; PMCID: PMC3709529.
- [20]. Ausen K, Fossmark R, Spigset O, Pleym H. Safety and Efficacy of Local Tranexamic Acid for the Prevention of Surgical Bleeding in Soft-Tissue Surgery: A Review of the Literature and Recommendations for Plastic Surgery. *Plast Reconstr Surg.* 2022 Mar 1;149(3):774-787. doi: 10.1097/PRS.0000000000008884. PMID: 35196701; PMCID: PMC8860217.
- [21]. Kitahara LBW, Silva VPD, Peres G, Miot HA, Schmitt JV. Efficacy of different concentrations of lidocaine and association of vasoconstrictor in local infiltration anesthesia in adults. *An Bras Dermatol.* 2021 Sep-Oct;96(5):623-625. doi: 10.1016/j.abd.2020.08.021. Epub 2021 Jul 16. PMID: 34275695; PMCID: PMC8441500.
- [22]. Fichman M, Piedra Buena IT. Rhinoplasty. 2023 Jun 12. In: StatPearls [Internet]. Treasure Island (FL): StatPearls Publishing; 2023 Jan-. PMID: 32644396.
- [23]. Dibelius G, Hohman MH. Rhinoplasty Tip-Shaping Surgery. 2023 Mar 1. In: StatPearls [Internet]. Treasure Island (FL): StatPearls Publishing; 2023 Jan-. PMID: 33620827.
- [24]. Aufrecht G (1958) A few hints and surgical details in rhinoplasty. *Laryngoscope* 53:317
- [25]. Bernstein LA (1975) Basic technique for surgery of the nasal lobule. *Otolaryngol Clin North Am* 8:599
- [26]. Brown JB, McDowell F (1965) Plastic Surgery of the Nose. CV Mosby, St. 26. Converse JM (1955) The cartilaginous structures of the nose. *Ann Otol Rhinol Laryngol* 64:220
- [27]. Converse JM (1964) Deformities of the nose. (Reconstructive plastic surgery, vol 2). WB Saunders, Philadelphia London, p 695
- [28]. Cottle MH, Loring, RM (1948) Surgery of the nasal septum: new operative procedures and indications. *Ann Otolaryngol* 57:707
- [29]. Daniel RX, Lessard ML (1984) Rhinoplasty: a graded aesthetic-anatomical approach. *Ann Plast Surg* 13:4361
- [30]. Dayan SH. Evolving techniques in rhinoplasty. *Facial Plast Surg.* 2007 Feb;23(1):62-9; discussion 70-9
- [31]. Goldman IB (1967) Principles in rhinoplasty. *Minn Med* 50:833
- [32]. Joseph J (1931) Nasenplastik und sonstige Gesichtsplastik: nebst einem Anhang über Mammoplastik. Curt Kabitzsch, Leipzig, pp 507-509
- [33]. McCollough EG, English JL (1985) A new twist in nasal tip surgery: an alternative to the Goldman tips for the wide or bulbous lobule. *Arch Otolaryngol* 111:524

- [34]. McCurdy JA Jr. (1977) Surgery of the nasal tip: current concepts. *Ear Nose Throat J* 56:238
- [35]. McKinney P (1984) Teaching model for rhinoplasty. *Plast Reconstr Surg* 74:846
- [36]. Millard DR (1976) Secondary rhinoplasty surgery. Symposium on corrective rhinoplasty. CV Mosby, St. Louis
- [37]. Ortiz-Monasterio F (1972) Rhinoplasty in the thick skin nose. Abstract book first in the National Congress ISAPS, Rio de Janeiro, p 14
- [38]. Ortiz-Monasterio F, Olmedo A, Osoy L (1981) The use of cartilage grafts in primary aesthetic rhinoplasty. *Plast Reconstr Surg* 67:597
- [39]. Peck GC (1976) Rhinoplasty surgery. In: Millard DR Jr. (ed) Symposium on corrective rhinoplasty. CV Mosby, St. Louis
- [40]. Peck GC (1984) Techniques in aesthetic rhinoplasty. Gower Medical Publishing Ltd., New York
- [41]. Pitanguy I (1965) Surgical importance of a dermocarilaginous ligament in bulbous noses. *Plast Reconstr Surg* 36:247
- [42]. Pitanguy I (1994) Revision rhinoplasty. *Am J Cosmet Surg* 11:183-187
- [43]. Rees TD (1973) Secondary rhinoplasty: symposium on aesthetic surgery of the nose, ears and chin. CVMosby, St. Louis
- [44]. Rees TD (1980) Secondary rhinoplasty in aesthetic plastic surgery. WB Saunders, Philadelphia, p 388
- [45]. Sheen JH (1976) Finesse in rhinoplasty. In: Millard DR Jr. (ed) Symposium on corrective rhinoplasty. CVMosby, St. Louis
- [46]. Sheen JH (1978) Aesthetic rhinoplasty. CV Mosby, St. Louis
- [47]. Skoog T (1966) A method of hump reduction in rhinoplasty. *Arch Otolaryngol* 83:283
- [48]. Skoog T (1975) Plastic surgery. WB Saunders, Philadelphia
- [49]. Stevens MH (1977) General anesthesia in nasal septal surgery. *Ear Nose Throat J* 56:22
- [50]. Tardy ME Jr, Brown RJ (1990) Surgical Anatomy of the Nose. Raven Press, New York
- [51]. Webster RC, Smith RC (1980) Rhinoplasty. In: Goldwyn RM (ed) Long-term results in plastic and reconstructive surgery. Little, Brown & Co., Boston