

# Case Management Of Young Patients With Temporomandibular Osteoarthritis Joint Disorders Using Stabilization Splint, Self Therapy And Chondroitin Sulfate-Glucosamine Supplements

Hanna Mentari Uliani<sup>1</sup>, Ricca Chairunnisa<sup>2</sup>, Syafrinani<sup>3</sup>

<sup>1</sup>(Prosthodontics Postgraduate Program, Faculty of Dentistry/ University of North Sumatra, Medan, Indonesia)

<sup>2</sup>(Lecturer, Departement Prosthodontics, Faculty of Dentistry/ University of North Sumatra, Medan, Indonesia)

<sup>3</sup>(Lecturer, Departement Prosthodontics, Faculty of Dentistry/ Universitas Sumatera Utara, Medan, Indonesia)

## Abstract:

**Background:** Osteoarthritis (OA) is a disorder of temporomandibular joint which results in permanent changes to TMJ. Scissors bite and bad habits are one of etiological factors of OA. OA causes deviation when opening mouth, limitations of mouth opening and joint crepitus sounds. Use of stabilization splints (SS), physical therapy, and consumption of chondroitin sulfate-glucosamine supplements aimed at reducing joint pain, relaxing of TMJ muscles and preventing joint damage.

**Case report:** A 22 year old female patient came to USU General Hospital with complaints stiff jaw when opening her mouth, especially in the morning. Complaints of pain occurred since skelling treatment 3 years ago. Clinical examination showed scissors bite and habit of chewing on right side. Palpation of right anterior temporalis muscle revealed familiar pain and joint crepitus sound. Based on DC/TMD assessment, patient had OA where the mouth opening is 35 mm without pain and 38 mm with pain accompanied by left deviation of 1.5 mm. On CBCT examination there was flattening on TMJ surface. Treatment is carried out by using SS every day and consuming chondroitin sulfate-glucosamine supplements for once a day accompanied by self therapy. Self therapy is carried out alone by practicing opening and closing the jaw for 15 minutes every day. After 6 months is obtained without assisted mouth opening of 36 mm to 41 mm. There is no pain on palpating muscles but there is still crepitus sound when opening and closing mouth.

**Conclusion:** Treatment of OA with SS, self therapy and consumption of Chondroitin Sulfate-Glucosamine supplements is effective in reducing TMJ joint pain and muscle stiffness through chondroitin stimulation mechanism so that prevent further degenerative processes.

**Key Words:** Temporomandibular joint disorder, Osteoarthritis, Stabilization splints

Date of Submission: 26-08-2023

Date of Acceptance: 06-09-2023

## I. Introduction

Osteoarthritis (OA) is a disorder of the temporomandibular joint characterized by a destructive process on the surface of the articular disc between the condyle and the fossa, causing an increase in joint load. Sustained stress causes thinning of the layers of the articular surface (chondromalacia) and subarticular bone. Progressive degeneration in OA will cause erosion of the cortical layer. Erosion of the articular eminence is the loss of attachment to the surface of the articular eminence. 6 Osseous changes in the TMJ can be clarified by CBCT images. 7

The condyle is covered with connective tissue containing mesenchymal cells and differentiates into chondrocytes which we know as fibrocartilage. Fibrocartilage is a secondary tissue consisting of perivascular osteogenic cells whose outer cell matrix is denser than hyaline bone cartilage. Osteogenic cells contain fibrous connective tissue that binds glycosaminoglycans (GAGs) and type I collagen fibers. Collagen, which is part of fibrocartilage, can withstand mechanical loads. The tensile strength of the cartilage bone causes the width of the tissue due to osmotic pressure. The occurrence of OA triggers the release of cytokines and increased growth factors in the synovial fluid in the TMJ. Cytokines can trigger the inflammatory process and the occurrence of synthesis accompanied by the release of proteases. This causes depletion of collagen and cartilage bone which causes symptoms in OA. 1,3

The etiology of OA is multifactorial. OA can be caused by trauma, parafunction, systemic disease, and joint loads that are too large when the TMJ is functioning. 1-4, 2, 8 Degenerative changes occur due to TMJ remodeling disorders. Remodeling is a biological response to TMJ stress. This is important for the balance

between joint function and occlusion. Excessive load for a long time accompanied by a lack of TMJ adaptation causes remodeling disorders. The initiation and progression of OA are due to the overload of the TMJ. Mechanical factors due to trauma cause changes in the articular disk, cartilage degradation, and the occurrence of inflammation and pain. Parafunction causes dislocation of the articular disc and articular eminence which will cause friction, unstable occlusion, and excessive functional load. Light loads will cause asymptomatic bone remodeling due to the adaptability of the TMJ when it functions. However, if the load received is greater than the adaptability of the bones accompanied by a habit of chewing on one side for a long time, it can exacerbate OA conditions.

Clinical characteristics in OA are characterized by a limited mandibular opening accompanied by pain in the joint.<sup>1,2,3,5,8</sup> The history of patients with OA is characterized by unilateral pain when mandibular movement occurs. The pain may be constant and worse, especially in the morning or at night. Symptoms of OA are specifically accompanied by a crepitus sound caused by friction between the bone surfaces. However, patients can also adapt so that they do not cause symptoms. This is because when the load is reduced, the TMJ will adapt even though changes in bone morphology continue to occur. This adaptive stage is known as osteoarthrosis.

Korean health institutions report an increase in the number of patients diagnosed with OA at the age of 50 years and over.<sup>10</sup> In a study by Ju et al, the ratio of experiencing OA can occur in patients aged 10-20 years.<sup>11</sup> Cases of young patients are rarely found because this age is still in the phase of development of occlusion and craniofacial bones.<sup>6,8</sup> However, the prevalence of several studies says that crepitus can be experienced in young patients around 12.5%.<sup>5,8,12</sup>

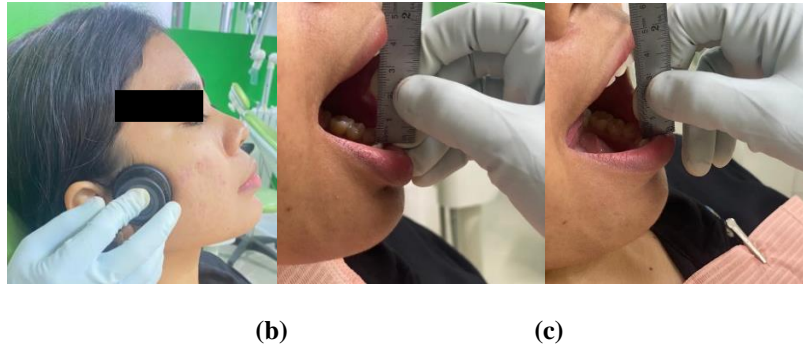
OA treatment according to the severity can be combined with the use of corticosteroids, hyaluronic acid, or chondroitin sulfate-glucosamine supplements.<sup>3,4</sup> The advantage of this supplement as a natural product is that it does not cause side effects. Chondroitin sulfate-glucosamine supplements have been clinically tested for their effectiveness in reducing TMJ joint pain. This is due to the stimulation mechanism of chondroitin where sulfur can cause a reaction in cartilage bone to prevent the TMJ degeneration process from occurring.<sup>3,4,13</sup>

OA treatment is divided into 3 groups, namely conservative treatment (patient education, analgesics, splint therapy, and physiotherapy), non-invasive surgical procedures (intra-articular injections, arthrocentesis, arthroscopy), and surgical procedures (arthroscopic procedures and TMJ surgery). SS protects the TMJ joint from overload and relieves muscle tension. The use of this tool helps the clinician to find out the area that is the center of the pain. SS therapy in patients caused by occlusion disorders such as scissors bite will reduce pain.<sup>13</sup> Several studies say that decreased TMJ function due to OA can be prevented due to the osseous bone remodeling process in the temporal TMJ which can still occur at a young age. Patients who experience recurrent symptoms can combine treatment using SS with self-therapy.<sup>14</sup> Use of a Stabilization Splint (SS) combined with self-therapy and supplements can relax stiff muscles.<sup>5,9,15</sup> Muscle relaxation will reduce the difficulty of opening and closing the TMJ joints.<sup>11,12</sup>

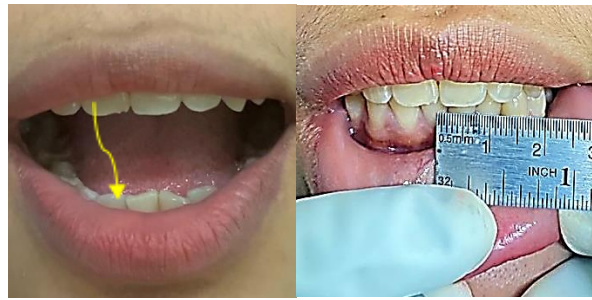## **II. Case Report**

A 22-year-old female patient came to the Dental and Oral Hospital of the University of North Sumatra with complaints of stiffness in the jaw joint when opening and closing her mouth when she wakes up. The patient has a habit of chewing on the right side. The patient complained of pain for the first time after skelling treatment due to opening the mouth for too long  $\pm$  3 years ago. This causes the jaw to be locked so that it is difficult to open or close the mouth.

Palpation of the masticatory muscles did not reveal pain except for the right anterior temporalis muscle when opening and closing the mouth where there was familiar pain and a crepitus sound in the jaw joint. On examination of the mouth opening, there was a mouth opening of 35 mm without pain and 38 mm of pain (figure 1a, b, and c). When opening the mouth there is a deviation of 1.5 mm to the left and a midline of 1.5 mm to the left (figures 2a and b). When examining the movement of the joint to the right 8 mm there was no pain but when moving to the left 9 mm there was a crepitus sound accompanied by pain in the right side of the TMJ joint. So based on the DC/TMD examination these conditions can be diagnosed as Degenerative Joint Disorders with Osteoarthritis (figure 3).<sup>16</sup>



Figur 1a) Photo of TMJ crepitus examination; b) Examination of opening mouth without pain: 35 mm; c) Examination of opening mouth with pain: 38 mm



(a) (b)  
Figure 2 a. Deviation to the left  
2 b. Midline shift 1.5 mm to the left

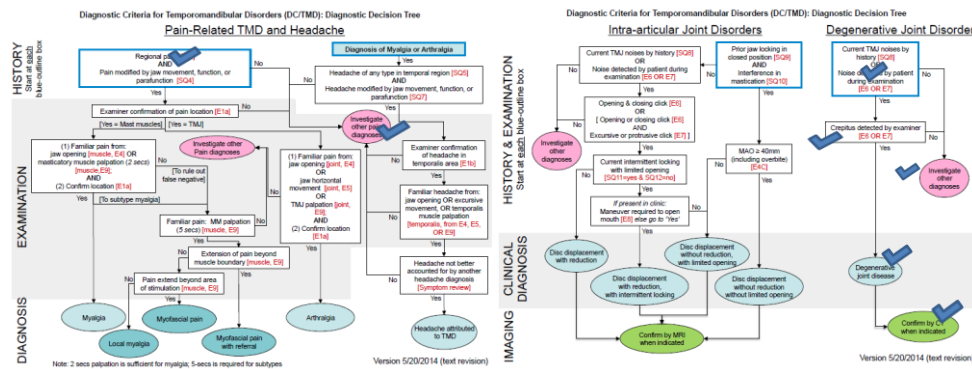
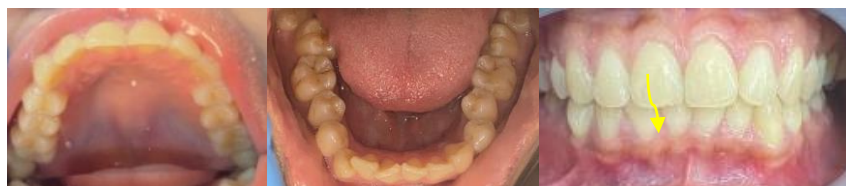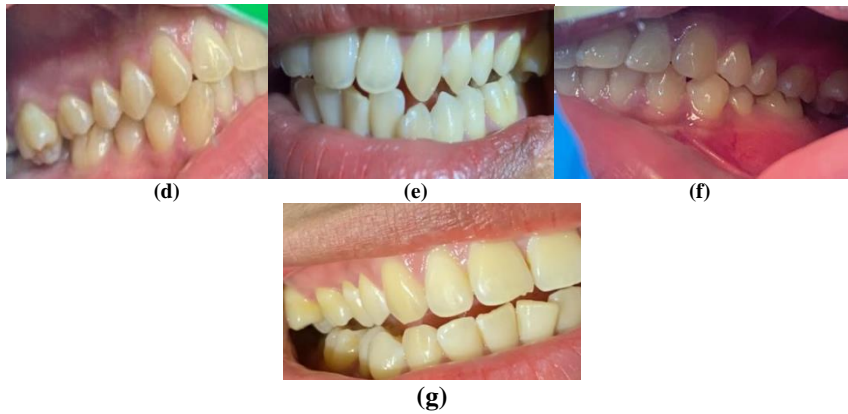


Figure 3  
Diagnostic criteria for temporomandibular disorders (DC/TMD): diagnostic decision tree 16

Intraoral examination and panoramic photo analysis showed no dental restorations but there are buccoversion of teeth 18, 28, 38, and 48. This could lead to scissors biting. Examination of overbite and overjet about  $\pm$  3 mm. Features of intraoral examination (Fig. 4 a-g).

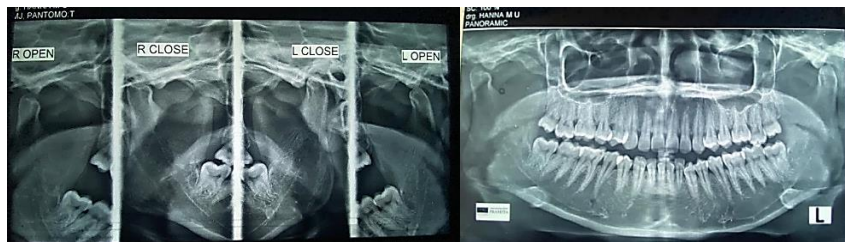

(a) (b)

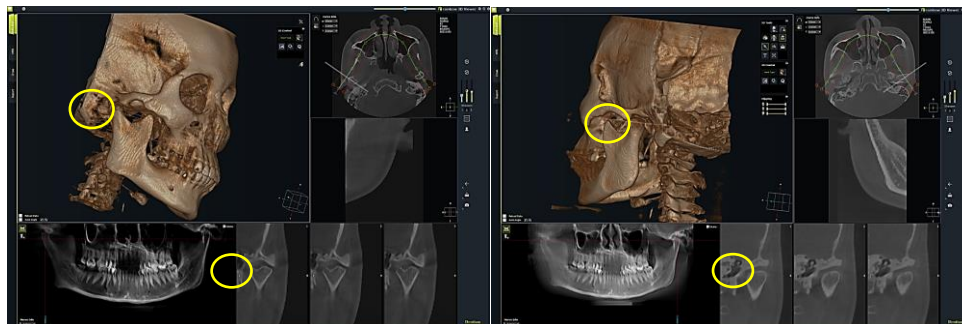


**Figure 4. Intraoral condition (a) maxilla (b) mandible, (c) front view, (d) right lateral, (e) left lateral and (f-g) dynamic occlusion relationship**

Panoramic radiographic images showed flattening of the left condyle (Fig. 5a and b). This is confirmed by a 3D image of the jaw joint with CBCT (Fig. 6). In the 3D view of the jaw joint when opening and closing it was found that there was an image of the condyle not reaching the articular eminence. This causes joint movement disorders which are characterized by limited mouth opening.

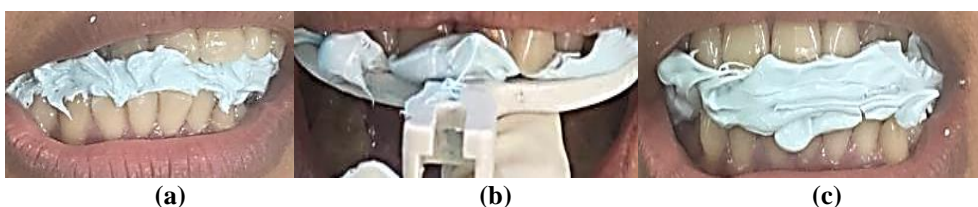


**Figure 5. Radiographic examination (a) of the TMJ in the closed and open positions (b) panoramic**



**Figure 6. CBCT examination (a) right and (b) left**

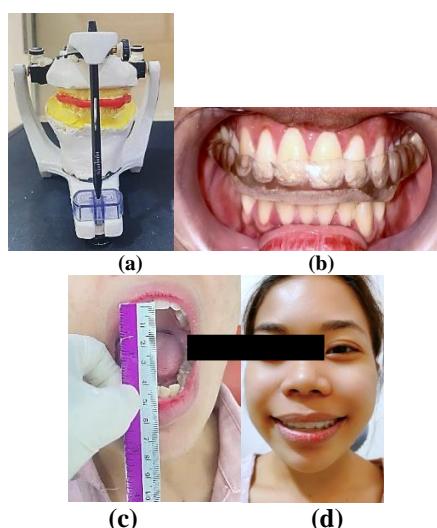
On the first visit, primary impression was carried out using an irreversible hydrocolloid (Hygident USA). After that, it was followed by making final cast model using type IV plaster material (Hard Stone THS-S Type 4, TST, Taiwan). Occlusal registration was performed with bite registration material (blue-mousse VPS, USA) according to the patient's centric occlusion, lateral movement right, left, and protrusive (Fig. 7 a-c).



**Figure 7 (a-c). Occlusal registration of centric occlusion and lateral movement**

After obtaining the bite height, final cast model was mounting on a semi-adjustable bioart articulator. Wax patterns are made by increasing the height by 2 – 4 mm to obtain a mutually protected occlusion (canine guidance). After everything is appropriate then flaked and dewaxed of wax pattern (picture 8a). Next was packing the wax pattern with clear acrylic resin (Heat Curing Vertex®, Vertex-Dental B.V., Netherlands) for the manufacture of SS. The results of SS insertion were checked again with articulating paper to obtain mutually protected occlusion (canine guidance) during centric and eccentric occlusion (figure 8b).

Patients were instructed to use the device every day. Patients are advised to reduce the habit of chewing on one side to reduce pain. Self-therapy is recommended to be done alone by the patient in the morning when he wakes up. Self-therapy is done by opening and closing the mouth straight in front of the mirror every day for 15 minutes. Patients were also instructed to take chondroitin sulfate-glucosamine supplements once a day. Then the patient was instructed to come for control once a month. Control splint use is done after 1 week, 2 weeks, and every month thereafter. At the visit after 6 months, the patient reported a decrease in symptoms of pain and stiffness in the muscles when opening and closing the mouth, especially in the morning. Unassisted mouth opening from 36 mm to 41 mm. Palpation of the muscles found no pain when opening and closing the mouth but there was still a crepitus sound in the right joint. Control after 6 months (figure 8c).



**Figure 8. a) Wax pattern making, b) Use of a stabilization splint  
c and d ) Control after 6 months**

### III. Discussion

The occurrence of Osteoarthritis (OA) in the temporomandibular joint based on pathophysiology, epidemiology, and severity shows different signs and symptoms. OA treatment can be done both invasively and non-invasively.<sup>4,7,17</sup> The use of non-steroidal anti-inflammatory drugs (NSAIDs) and analgesics are generally given to reduce pain, but long-term consumption can cause problems in the gastrointestinal tract and kidney.<sup>4</sup>

Chondroitin sulfate-glucosamine supplements can relieve TMJ joint pain. This supplement aims to be anti-aging, antioxidant, prevent the development of bacteria, increase immunity, and stimulate hormone production. Several studies say that taking glucosamine chondroitin sulfate supplements for 3 months as an anti-inflammatory will reduce joint stiffness and sound in joints.<sup>13</sup> This occurs due to a stimulation mechanism of chondroitin where sulfur can react in the TMJ cartilage so that it can cause remodeling of the TMJ. <sup>3,4,13</sup>

OA treatment can be combined using a stabilization splint (SS) and self-therapy. Ok. et al said that the use of SS for  $\pm$  11 months can stimulate bone remodeling in the anterior part of the condylar head thereby reducing the occurrence of bone resorption in the glenoid fossa. This can be evaluated based on the lack of symptoms and superimposed features on CBCT before and after treatment. <sup>18</sup> Pficer et al said that OA treatment with SS and self-therapy showed a significantly high success rate in less than 3 months, while Milojević et al said that optimal results can be obtained after 6 months of treatment.<sup>9,15</sup> The purpose of using SS and self-therapy is to reduce bone resorption, especially in the mandibular fossa of the TMJ.<sup>11</sup> This tool is effective in reducing pain, improving quality of life, and patient comfort, especially when opening the mouth.<sup>9,11,15</sup>

#### IV. Conclusion

OA does not only occur in old age but can also be experienced by young patients due to bad habits and trauma. The effectiveness of chondroitin sulfate-glucosamine supplements has a higher success than medication with analgesics but it is not clear how the side effects on the body are so further research is needed. 3,4,13 Use of stabilization splints (SS), self therapy combined with supplements chondroitin sulfate-glucosamine is the treatment with the least risk of all treatment options but further studies are still needed based on the degree of severity in the diagnosis of OA. 5,7,9.

#### References

- [1]. Okeson JP. Management Of Temporomandibular Disorders And Occlusion - Jeffrey P. Okeson - 8th Edition (2019) 512 Pp., ISBN: 9780323582100.
- [2]. Pardo Juárez V. Diagnostic Efficacy Of Cone Beam Computed Tomography For The TMJ Arthropathies. *J Dent Heal Oral Disord Ther.* 2020;11(6):176–85.
- [3]. Artuzi FE, Puricelli E, Baraldi CE, Quevedo AS, Ponzoni D. Reduction Of Osteoarthritis Severity In The Temporomandibular Joint Of Rabbits Treated With Chondroitin Sulfate And Glucosamine. *Plos One* [Internet]. 2020;15(4):1–16. Available From: [Http://Dx.Doi.Org/10.1371/Journal.Pone.0231734](http://dx.doi.org/10.1371/journal.pone.0231734)
- [4]. Melo G, Casett E, Stuginski-Barbosa J, Guerra ENS, Fernandes DA, Porporatti AL, Et Al. Effects Of Glucosamine Supplements On Painful Temporomandibular Joint Osteoarthritis: A Systematic Review. *J Oral Rehabil.* 2018;45(5):414–22.
- [5]. Vrbanović E, Alajbeg IZ. Mlada Pacijentica S Osteoartritisom Temporomandibularnog Zgloba: Prikaz Slučaja. *Acta Stomatol Croat.* 2017;51(3):232–9.
- [6]. Jung W, Lee K Eun, Suh B Jik. Temporomandibular Joint Osteoarthritis In Older And Young People Abstract : 2022;1–6.
- [7]. Derwich M, Mitus-Kenig M, Pawłowska E. Interdisciplinary Approach To Temporomandibular Joint Osteoarthritis—Review Of The Literature. *Med.* 2020;56(5):1–22.
- [8]. Krisjane Z, Urtane I, Krumina G, Neimane L, Ragovska I. The Prevalence Of TMJ Osteoarthritis In Asymptomatic Patients With Dentofacial Deformities: A Cone-Beam CT Study. *Int J Oral Maxillofac Surg* [Internet]. 2012;41(6):690–5. Available From: [Http://Dx.Doi.Org/10.1016/J.Ijom.2012.03.006](http://dx.doi.org/10.1016/j.ijom.2012.03.006)
- [9]. Milojević-Šamanović A, Zdravković D, Veličković S, Jovanović M, Milosavljević M. Non-Invasive Approach In The Treatment Of Temporomandibular Joint Osteoarthritis. *Srp Arh Celok Lek.* 2021;149(1–2):97–101.
- [10]. Kim HK, Song SO, Noh J, Jeong IK, Lee BW. Data Configuration And Publication Trends For The Korean National Health Insurance And Health Insurance Review & Assessment Database. *Diabetes Metab J.* 2020;44(5):671–8.
- [11]. Ju HM, Lee SH, Jeon HM, Kim KH, Ahn YW, Ok SM, Et Al. Could Crepitus Be An Indication For Early Temporomandibular Joint Osteoarthritis? *J Oral Med Pain.* 2019;44(3):146–146.
- [12]. Emshoff R, Bertram A, Hupp L, Rudisch A. Condylar Erosion Is Predictive Of Painful Closed Lock Of The Temporomandibular Joint: A Magnetic Resonance Imaging Study. *Head Face Med.* 2021;17(1):1–9.
- [13]. Derwich M, Górski B, Amm E, Pawłowska E. Oral Glucosamine In The Treatment Of Temporomandibular Joint Osteoarthritis: A Systematic Review. *Int J Mol Sci.* 2023;24(5).
- [14]. Türp JC. Occlusal Splints For Painful Craniomandibular Dysfunction. Lori Bateman, Editor. Batavia, IL: Quintessence Publishing Co, Inc; 2022.
- [15]. Pficer JK, Dodic S, Lazic V, Trajkovic G, Milic N, Milicic B. Occlusal Stabilization Splint For Patients With Temporomandibular Disorders: Meta-Analysis Of Short And Long Term Effects. *Plos One.* 2017;12(2).
- [16]. Rdc I, Consortium TMD, Editor N, Version RO. DC-TMD English Assessment Instruments\_2016\_06\_11\_Secured.
- [17]. Song H, Lee JY, Huh KH, Park JW. Long-Term Changes Of Temporomandibular Joint Osteoarthritis On Computed Tomography. *Sci Rep* [Internet]. 2020;10(1):1–10. Available From: [Http://Dx.Doi.Org/10.1038/S41598-020-63493-8](http://dx.doi.org/10.1038/S41598-020-63493-8)
- [18]. Ok SM, Jeong SH, Ahn YW, Kim Y Il. Effect Of Stabilization Splint Therapy On Glenoid Fossa Remodeling In Temporomandibular Joint Osteoarthritis. *J Prosthodont Res* [Internet]. 2016;60(4):301–7. Available From: [Http://Dx.Doi.Org/10.1016/J.Jpor.2016.03.001](http://dx.doi.org/10.1016/j.jpor.2016.03.001)