

Implant In The Critical Esthetic Zone: A Case Report

Dr. Vishakha Lakhode, Dr. Jyoti Tembhurne, Dr. Arti Gangurde

(Department of Prosthodontics and Crown & Bridge, Government Dental College and Hospital Mumbai, India)

ABSTRACT:

Dental implant is the best treatment option for a lost tooth in today's era of modern dentistry. Placing implant in esthetic zone, it is imperative to understand bone quality and bone volume as well as give equal importance to the esthetic expectations of the patient. Alveolar ridge defects occur due to maxillofacial trauma, accidents, traumatic tooth extraction, and advanced periodontal diseases. Defects that occur in bone and soft tissue can be horizontal or vertical in nature. This defect can be corrected by various reconstruction techniques like soft tissue or bone graft, guided bone regeneration. This case demonstrates the replacement of missing maxillary anterior tooth using screw-retained implant prosthesis after guided bone regeneration.

Key word: mucoperiosteal facial flap, DFDBA, bone graft, temporary restoration, labial ridge deformity

Date of Submission: 23-08-2023

Date of Acceptance: 03-09-2023

I. INTRODUCTION:

For restoring a single missing tooth, dental implants have been established as an alternative to the conventional 3-unit fixed dental prostheses. Aesthetic concerns play a major role, particularly in the maxillary anterior region in patient with high lip line. The characteristics of the soft and hard tissue present in the edentulous area plays an important decisive factor for the success of implant placement and its esthetic outcome. With the help of guided bone regeneration implants can still be successfully placed in sites having various degrees of ridge defect. Both the dentist and the patient should come to a collective conclusion of the best treatment option. The dentist should guide the patient about all the pros and cons of different treatment options to achieve the best esthetic outcome.

II. CASE REPORT:

This case represents replacement of missing maxillary right central incisor, restored by implant prosthesis after the use of bone graft for correction of buccal bone defect. A 21-years old male reported with missing maxillary right central incisor due to trauma 2 years back. He did not have any underline medical condition. Extra oral examination revealed normal TMJ movement and lip tonicity and profile. Intra oral examination revealed the missing of right central incisor and class 1 Ellis fracture with right lateral incisor (fig1). The mucosa over the edentulous area was firm and resilient with normal thickness. CBCT revealed missing tooth-11, the labial cortical plate appeared thin with focal discontinuity evident in mid-alveolus region (figure2). There was adequate bone height and mesiodistal width and D2 bone quality for the placement of implant. A two-stage implant surgical procedure (using osstem S3 implant) was planned with simultaneous use of bone graft to cover any dehiscence in the labial aspect that may appear during the placement procedure. After evaluating the clinical and radiographic findings, a stepped-screw implant of 11 mm length and 3.5 mm diameter was considered ideal for the site. Non-surgical periodontal treatment including scaling and polishing was performed 2 weeks prior to the implant placement surgery. Study models were prepared.

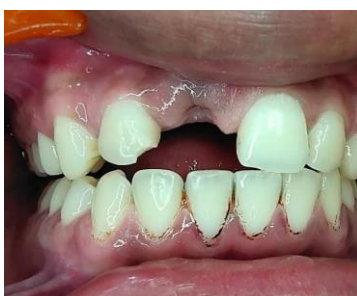

Figure 1: Missing central incisor with labial defect and Elli's class 1 fracture with 12

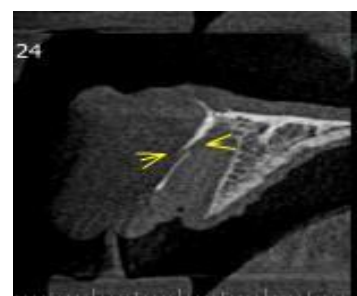


Figure2: Thin labial plate with discontinuity Labial in mid-alveolus region

First surgical stage:

After anesthetizing the surgical site using infiltration anesthesia, a full thickness (mucoperiosteal flap) was elevated following a horizontal incision on the palatal aspect of the alveolar ridge and sulcular incision on the proximal aspect of the adjacent teeth. The papillae were reflected as a part of mucoperiosteal facial flap. Osteotomy began 0.5mm more palatal than the usual mid crest. Drilling protocol was followed in a sequential manner. After the final drill of 3.5mm diameter to the depth of 11mm, implant reched into the osteotomy site under 20 Ncm torque. After implant insertion, cover screw was placed in position.

Bone Grafting:

Due to the discontinuity in the mid alveolus region on the coronal aspect of the implant, the labial bone was decorticated with hand instrument and bone allograft mixed with saline was placed covering the dehiscence (figure3). GBR membrane was placed and flap was sutured using interrupted sutures (figure4). Post-operative intraoral radiograph was taken to verify the proper positioning of the implant (Figure5). A temporary Maryland bridge was fabricated and used during the transitional period i.e., period of healing(figure6)

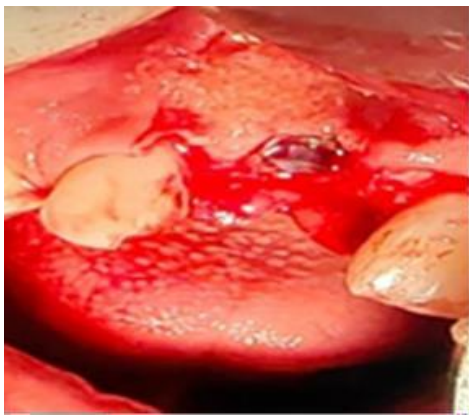


Figure3: Placement of bone graft and bone defect

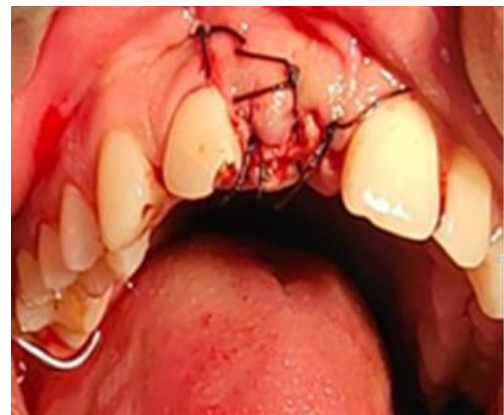

Figure4: suture placed membrane to cover

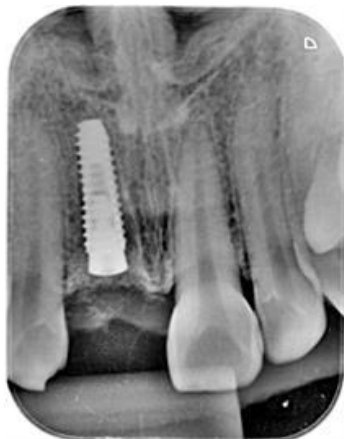

Figure 5: Post operative intra-operative Radiograph

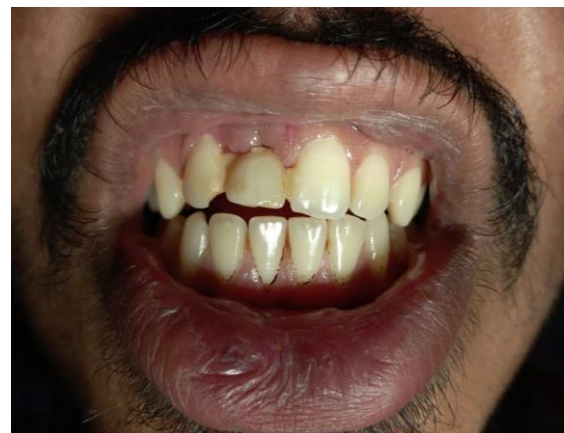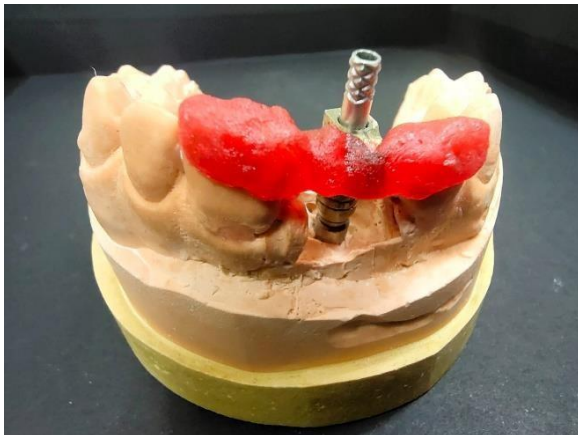


Figure 6: Maryland bridge as provisional prosthesis

Second surgical stage:

After a healing period of 4 months, implant site was uncovered and healing abutment was placed to achieve optimal soft tissue contour. 5-6 days after removal of healing abutment, emergence profile was achieved. After 15 days implant level impression was made with a special tray using additional silicon impression material. The cast was obtained after attaching implant analogue to the impression coping. The position of the implant and the accuracy of the impression was verified using zig trial to obtain emergence profile in such cases. A NP cast abutment was selected with the gingival collar of 2 mm to achieve the crown margin 1 mm subgingivally. After a satisfactory try in, screw retained prosthesis was fabricated(figure7,8).. In

the following subsequent appointment, the patient's oral hygiene maintenance found satisfactory and the final



prosthesis was delivered (figure9).
Figure 7: Zig fabrication

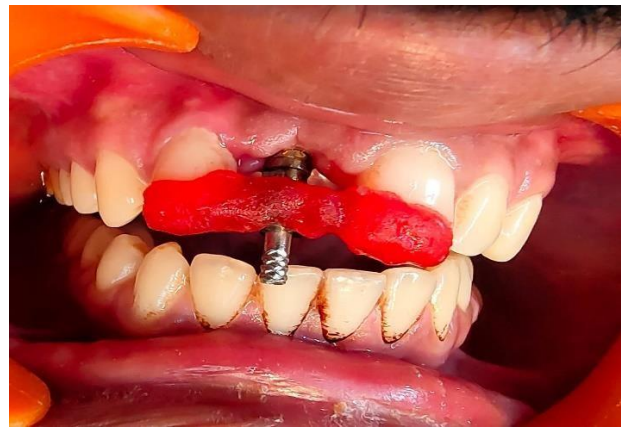

Figure 8: Verification of zig-trial intraorally

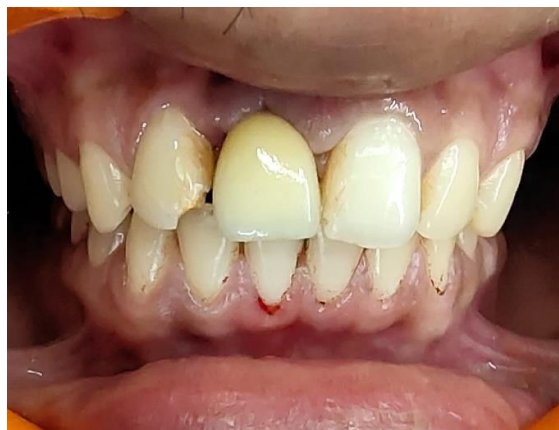

Figure 9: final prosthesis

III. DISCUSSION:

Management of an anterior missing tooth can be extremely challenging to an implantologist in terms of achieving an esthetic emergence profile. Precise implant placement in a 3-dimensional plane is the key to achieve better esthetic, function, and patient's satisfaction. Frequently due to history of trauma or fracture of the labial bone during extraction may create a dehiscence defect. Sometimes, the threads of the implant might be exposed due to such either dehiscence or fenestration. To achieve a favorable esthetic outcome, it is mandatory to do bone or soft tissue grafting. There are various types of allogenic or xenografts available in a market or else autogenous bone can also be utilized to achieve a better bone contour and implant coverage. In this article, demineralized freeze-dried bone allograft was used to cover labial ridge deformity to enhance osseointegration as well as bone formation around the implant site.

To enhance tissue regeneration, it is imperative to use a barrier membrane, which not only causes guided tissue regeneration but also provides a scaffold for a bone guided regeneration. This barrier membrane can be biodegradable or non-biodegradable. Non-biodegradable membranes are manufactured from synthetic polymers, metals, or composite of these materials. Biodegradable membranes are mainly made from natural and synthetic polymers. Biodegradable membranes, which are almost exclusively polymer-based (natural and synthetic polymers), have the advantage that it does not require secondary surgery.

IV. CONCLUSION:

For an optimal placement of an implant supported prosthesis in the esthetic zone, the remaining bone and soft tissue plays a vital role. More the bone loss, the less predictable the esthetic outcome after implant placement. Bone grafts and membrane play an integral part in achieving a suitable bony and soft tissue contour. A combination of demineralized freeze-dried bone allograft and barrier membrane can be used to cover bone defects as well as exposed implant threads.

REFERENCES:

- [1]. F. G. Mangano, P. Mastrangelo, F. Luongo, A. Blay, S. Tunchel, and C. Mangano, "Aesthetic outcome of immediately restored single implants placed in extraction sockets and healed sites of the anterior maxilla: a retrospective study on 103 patients with 3 years of follow-up," *Clinical Oral Implants Research*, vol. 28, no. 3, pp. 272–282, 2017
- [2]. B. Butler, "Masking buccal plate remodeling in the esthetic zone with connective tissue grafts: immediate implant concepts, techniques," *Compendium of Continuing Education in Dentistry*, vol. 35, no. 7, pp. 486–493, 2014.
- [3]. W. Becker, "Immediate implant placement: diagnosis, treatment planning and treatment steps/or successful outcomes," *Journal of the California Dental Association*, vol. 33, no. 4, pp.303–310, 2005.
- [4]. C. N. Eliasa, F. A. Rocha, A. L. Nascimento, and P. G. Coelho, "Influence of implant shape, surface morphology, surgical technique and bone quality on the primary stability of dental implants," *Journal of the Mechanical Behavior of Biomedical Materials*, vol. 16, no. 1, pp. 169–180, 2012.
- [6]. D. Van Steenberghe, I. Naert, M. Andersson, I. Brajnovic, J. Van Cleynenbreugel, and P. Suetens, "A custom template and definitive prosthesis allowing immediate implant loading in the maxilla: a clinical report," *International Journal of Oral and Maxillofacial Implants*, vol. 17, no. 5, pp. 663–670, 2002.
- [7]. T. V. Padmanabhan and R. K. Gupta, "Comparison of crestal bone loss and implant stability among the implants placed with conventional procedure and using osteotome technique: a clinical study," *The Journal of Oral Implantology*, vol. 36, no. 6, pp. 475–483, 2010.
- [8]. M. G. Araújo, C. O. Silva, M. Misawa, and F. Sukekava, "Alveolar socket healing: what can we learn?" *Periodontology 2000*, vol. 68, no. 1, pp. 122–134, 2015.
- [9]. V. Chappuis, M. G. Araújo, and D. Buser, "Clinical relevance of dimensional bone and soft tissue alterations post-extraction in esthetic sites," *Periodontology 2000*, vol. 73, no. 1, pp. 73–83, 2017.
- [10]. S.-C. Cho, S. J. Froum, A. R. Kamer, P. M. Loomer, G. Romanos, and B. Demiralp, "Implants in the anterior maxilla: aesthetic challenges," *International Journal of Dentistry*, vol. 2015, Article ID 152420, 2 pages, 2015.
- [11]. P. P. Poli, A. K. Mukhtadar, F. Á. Souza, C. Maiorana, and M. Beretta, "Computer-guided implant placement associated with computer-aided bone regeneration in the treatment of atrophied partially edentulous alveolar ridges: a proof-of-concept study," *Journal of Dental Science*, vol. 16, no. 1, pp. 333–341, 2021.
- [12]. E. García-Gareta, M. J. Coathup, and G. W. Blunn, "Osteoinduction of bone grafting materials for bone repair and regeneration," *Bone*, vol. 81, pp. 112–121, 2015.
- [13]. H. E. Jazayeri, M. Tahriri, M. Razavi et al., "A current overview of materials and strategies for potential use in maxillofacial tissue regeneration," *Materials Science and Engineering: C*, vol. 70, no. Pt 1, pp. 913–929, 2017.
- [14]. R. V. Deev, A. Y. Drobyshev, I. Y. Bozo, and A. A. Isaev, "Ordinary and activated bone grafts: applied classification and the main features," *BioMed Research International*, vol. 2015, Article ID 365050, 19 pages, 2015.
- [15]. P. Kumar, B. Vinitha, and G. Fathima, "Bone grafts in dentistry," *Journal of Pharmacy & bioallied sciences*, vol. 5, pp. S125–S127, 2013.
- [16]. N. Moussa, Y. Fan, and H. Dym, "Maxillofacial bone grafting materials," *Dental Clinics of North America*, vol. 65, no. 1, pp. 167–195, 2021.
- [17]. D. Carmagnola, S. Abati, S. Celestino, M. Chiapasco, D. Bosshardt, and N. P. Lang, "Oral implants placed in bone defects treated with bio-oss, ostim-paste or perioglas: an experimental study in the rabbit tibiae," *Clinical Oral Implants Research*, vol. 19, no. 12, pp. 1246–1253, 2008.