

Fixed Implant Prosthesis: A Case Report

Dr. Priya Sonawane, Dr. Jyoti Tembhurne, Dr Arti Gangurde

(Department of prosthodontics and Crown & Bridge. Government Dental College and Hospital Mumbai, India)

Abstract:

Partially edentulous arch can be replaced by various treatment options including removable as well as fixed prosthesis.

The preferred choice for replacement of missing tooth in a tooth bound edentulous area can be either tooth supported or implant supported. With the vision of preservation of what remains, an implant supported prosthesis is always a better option. Thus this case report presents the replacement of mandibular first molar by an implant supported screw retained prosthesis.

Key Word: Implant dentistry, screw retained prosthesis, missing mandibular molar replacement

Date of Submission: 11-07-2023

Date of Acceptance: 21-07-2023

I. Introduction:

The mandibular first permanent molars are the first permanent teeth to erupt in the permanent dentition between the ages of 6-7 years old. It is often the first tooth to be lost because of dental caries. They perform the major portion of work of the lower jaw in mastication of food. They are the largest and strongest mandibular teeth because of their bulk and their anchorage. They help to maintain the overall structure and alignment of the dentition.

Loss of it results in nonphysiological occlusion due to tipping of adjacent teeth in edentulous space and supraeruption of opposing teeth. Options available for the replacement of a missing mandibular right first permanent molar are –removable partial denture, fixed partial denture, fixed implant prosthesis. Using removable prosthesis for younger patient is not a favorable option. Use of fixed partial denture for replacing missing teeth require tooth reduction of adjacent healthy teeth. Placement of dental implant for replacing missing mandibular first permanent molar creates a favorable option for restoration. It's both esthetically pleasing and has more patient satisfaction. This case report describes a method to rehabilitate a patient with missing mandibular first permanent molar with implant supported fixed prosthesis.

II. Case Report:

A 30-years old female patient reported to the department of prosthodontics, Government Dental College and Hospital, Mumbai with the chief complaint of difficulty in chewing food because of missing lower right first permanent molar.

Patient had history of extraction three years back because of decay, since that time patient is partially edentulous. She has been using removable prosthesis for last 2.5 years and was not satisfied. There is no other relevant medical history. Oral prophylaxis was done and instructions for maintaining good oral hygiene was explained to the patient.

On clinical examination of oral cavity it is seen that gingival and periodontal health of patient was good. Edentulous ridge is well rounded with an adequate occluso-gingival and mesio-distal dimensions of the edentulous space.

Due to the past experience of the removable prosthesis the patient wanted a fixed prosthesis. The patient was explained the pros and cons of both tooth supported and implant supported prosthesis and she opted for later.

Treatment Plan:

Diagnostic impression were made with irreversible hydrocolloid and impression were poured in dental stone, cast were mounted on articulator. CBCT was carried out to know the dimensions of the available bone. The bone width was noted to be 6.5 mm and bone height was noted to be 11 mm. After clinical examination and study of cast and CBCT, implant size of TSIII SA Fixture 4.5 x 8.5 mm was selected. The first step of treatment consist of surgically placing the implant into partially edentulous space which simulate the root form of the tooth and the second step consist of loading of implant after 3 months once the healing is completed.

A written informed consent was signed from the patient before the surgical procedure.

During the surgical phase the edentulous site was cleaned with povidone iodine solution and patient was asked to rinse with chlorhexidine gluconate mouthwash.

Surgical Procedure:

With the help of local anesthesia (XICAINE- 2% with adrenaline 1 in 80,000) Lignocaine hydrocolloid & adrenaline bitartrate I.P. injection surgical site was anesthetized , after few minutes when patient presented subjective & objective symptoms of anesthesia a conventional mid crestal incision were given followed by buccal and lingual crevicular incision around the adjacent teeth for better exposure of operative site with blade no.12 and BP handle. Full thickness mucoperiosteal flap was reflected with the help of periosteal elevator.

Lance drill was used to mark the implant site by using ossteum taper kit, a paralleling pin was placed in drilled socket and radiograph was taken to evaluate the parallelism of the drill .The sequential drilling was done till TSIII SA Fixture 4.5 x 8.5 mm and an implant fixation was done with a torque of 30 Ncm .Cover screw was placed. The mucoperiosteal flap was approximated and 3-0 non absorbable surgical black silk sutures with reverse cutting needle 26mm 3/8 circle were used for giving sutures. Simple interrupted sutures given. Post-surgical medication and instructions given to the patient. Patient were recalled after 10 days for removal of sutures. During the suture removal stage no inflammation or complications of surgical site was noted.

Second Stage Surgery:

After healing period of 3 months patient was recalled and radiograph was taken and it shows the sign of Osseo integration. For second stage surgery partial thickness flap technique was used and cover screw was removed, ossteum healing abutment was placed, IOPA was taken to check the fit of abutment and Patient is recalled after the healing period of 15 days.

Prosthodontics Phase:

Healing abutment was removed , impression coping was placed with the help of hex driver & Open tray impression technique was used for taking impression with putty and light body (AVUE Gum Putty & Light Body), impression was poured, jig was created for jig try-in and jig try-in done and radiograph was taken. In next appointment with custom made abutment metal and bisque trials done. A screw retained porcelain-fused-to-metal (PFM) crown was fabricated according to the shade of adjacent teeth and it was checked in to the patient's mouth for its fit to the implant and for occlusion. The crown was loaded onto the implant.

III. Discussion:

This case report discussed about the advantages of replacing a lost tooth with implant and how a removable prosthesis is unable to bear the mastication load with low patient compliance. Whereas a fixed prosthesis hampers the adjacent healthy teeth, requiring it to be reduced which in turn removes a healthy amount of enamel leaving it in a compromised state whereas a dental implant not only restore the function, esthetics, phonetics, and has a good patient compliance. Dental implants positively affecting the overall well-being of the patient including psychology.

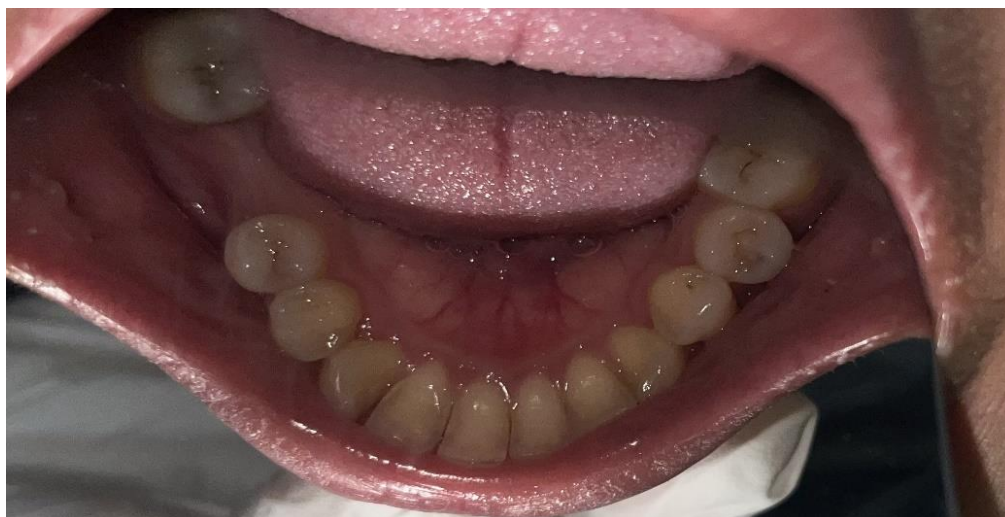

Fig 1: missing mandibular right first molar

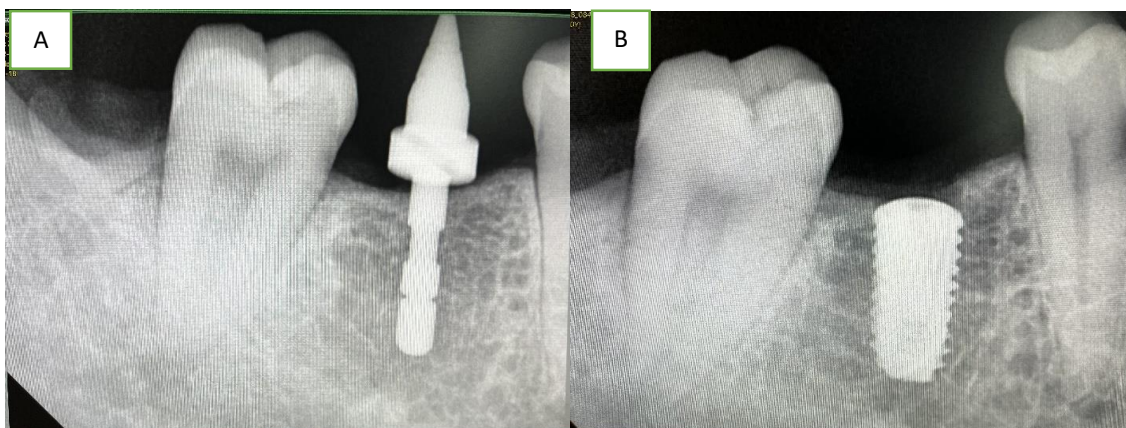


Fig 2: Intra-oral periapical radiographs showing A) parallelism pin placement and B) implant placement

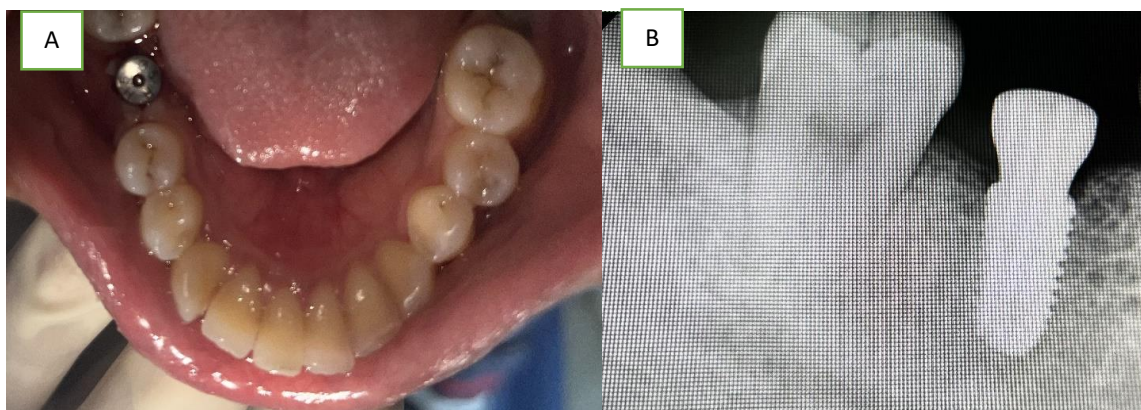


Fig 3: A) Healing abutment in place A) on clinical examination B) in intraoral periapical radiograph

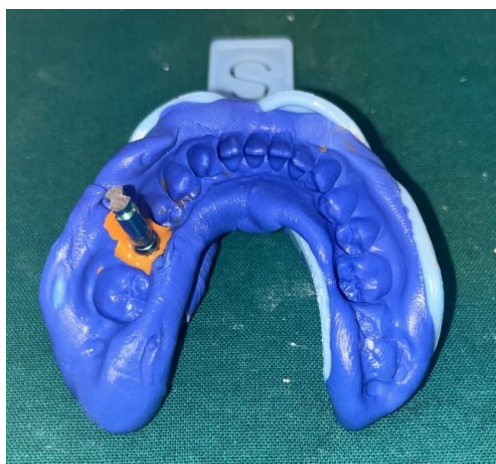

Fig 4: open tray impression with putty and light body

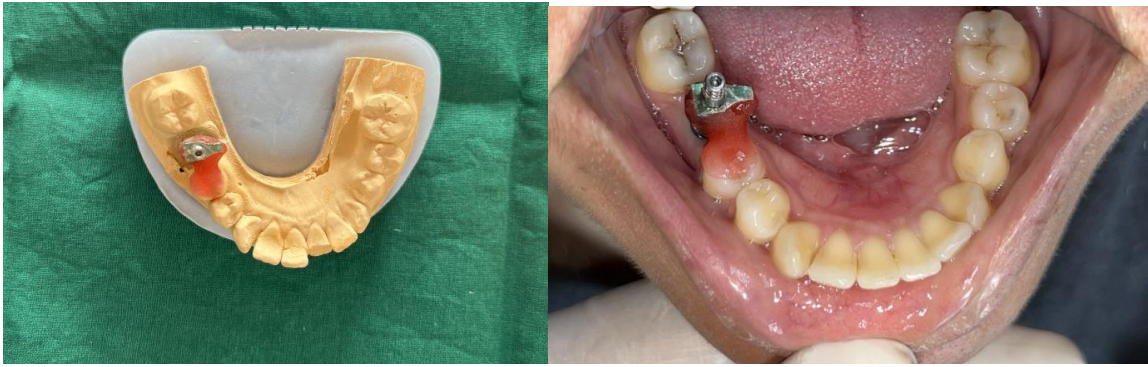


Fig 5: jig trial on coping A) on the prepared cast B) intra-orally

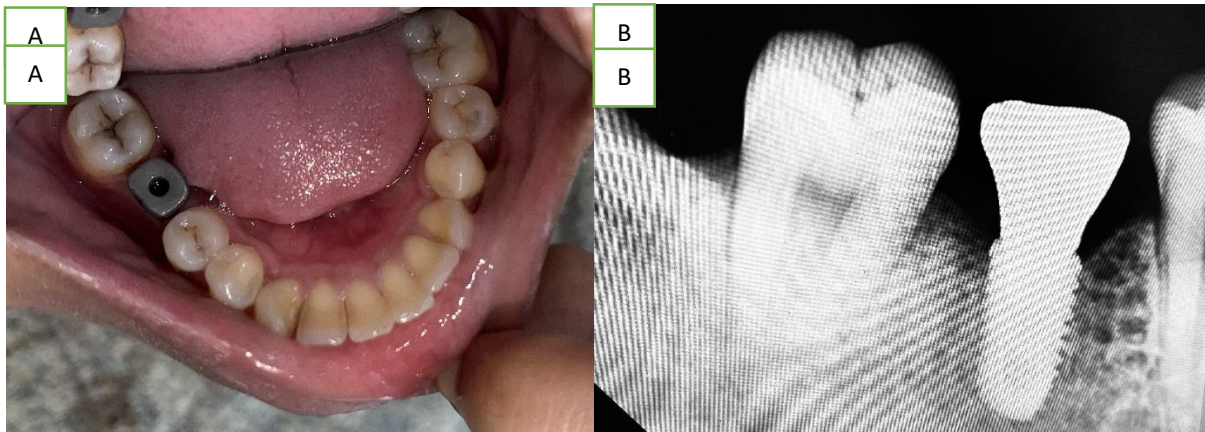


Fig 6: metal try in A) intra-orally B) in intra-oral periapical radiograph

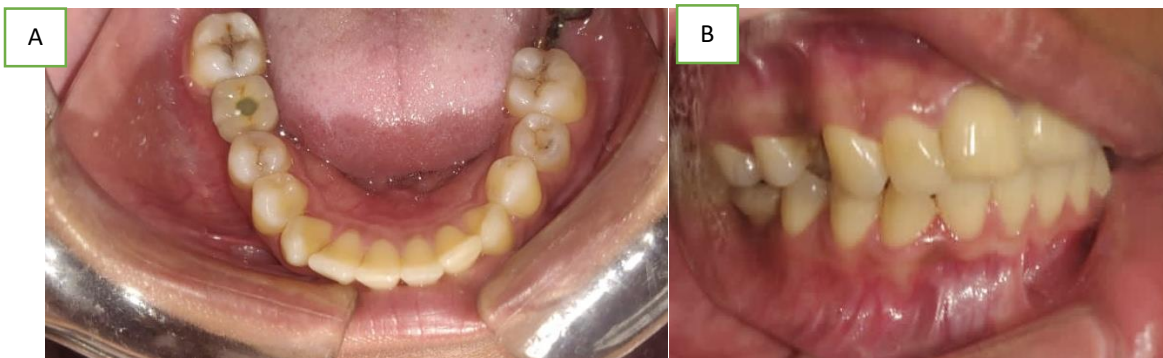
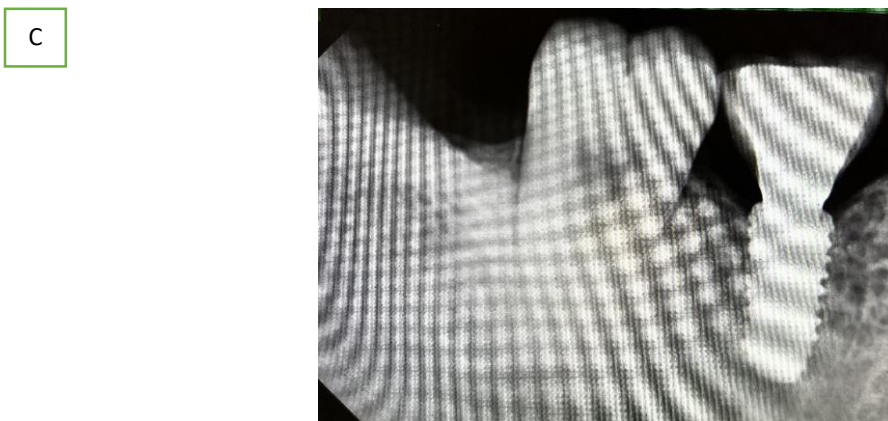

Fig 7: A) implant loaded with screw-retained porcelain fused to metal crown; B) achieved occlusion with the prosthesis in place



C) Intra-oral periapical radiograph after placement of the prosthesis

IV. Conclusion:

Dental implant treatment has been frequently used in dental practice as the most important prosthodontics procedure with long term predictability to restore oral function, maintain occlusion and improve the quality of life of a patient.

References:

- [1]. Brånemark PI, Adell R, Hansson BO, Et Al. Intraosseous Anchorage Of Dental Prosthesis: I-Experimental Studies. *Scand J Plast Reconstr Surg* 1969; 3: 81-100.
- [2]. Lewis S. Treatment Planning: Teeth Versus Implants. *Int J Periodontics Restorative Dent* 1996; 16: 366-77.
- [3]. Matosian GS. Treatment Planning For The Future: Endodontics, Post And Core, And Periodontal Surgery: Or An Implant? *Journal Of The California Dental Association* 2003; 31: 323-5.
- [4]. Hutter JW. Implants Versus The Natural Tooth: Stand Up For What We Know Is Right. *J Endod* 2001; 27: 637.
- [5]. Torabinejad M. Apples And Oranges. *J Endod* 2003; 29:5 41-2.
- [6]. Felton DA. Implant Or Root Canal Therapy: A Prosthodontist's View. *J Esthet Restor Dent* 2005; 17: 197-9.
- [7]. Moiseiwitsch J. Do Dental Implants Toll The End Of Endodontics? *Oral Surg Oral Med Oral Pathol Oral Radiol Endod* 2002; 93: 633- 4.
- [8]. Albrektsson T, Zarb GA, Worthington P, Et Al. The Long Term Efficacy Of Currently Used Dental Implants: A Review And Proposed Criteria Of Success. *Int J Oral Maxillofac Implants* 1986; 1: 11.
- [9]. Smith DE, Zarb GA. Criteria For Success Of Osseointegrated Endosseous Implants. *J Prosthet Dent* 1989; 62: 567-72.
- [10]. Jaffin RA, Berman CL. The Excessive Loss Of Brånemark Fixtures In Type IV Bone: A 5-Year Analysis. *J Periodontol* 1991; 62: 2-4.
- [11]. Block MS, Gardiner D, Kent JN, Misiek DJ, Finger IM, Guerra L. Hydroxyapatite-Coated Cylindrical Implants In The Posterior Mandible: 10-Year Observations. *Int J Oral Maxillofac Implants* 1996; 11: 626-633.
- [12]. Artzi Z, Tal H, Moses O, Kozlovsky A. Mucosal Considerations For Osseointegrated Implants. *J Prosthet Dent* 1993; 70: 427-432.
- [13]. Bauman GR, Mills M, Rapley JW, Hallmon WW. Plaque Induced Inflammation Around Implants. *Int J Oral Maxillofac Implants* 1992; 7: 330-337.
- [14]. Mombelli A, Marxer M, Gberthuel T, Grunder U, Lang NP. The Microbiota Of Osseointegrated Implants In Patients With A History Of Periodontal Disease. *J Clin Periodontol* 1995; 22: 124-130.
- [15]. Kohavi D, Greenberg R, Raviv E, Sela MN. Subgingival And Supragingival Microbial Flora Around Healthy Osseointegrated Implants In Partially Edentulous Patients. *Int J Oral Maxillofac Implants* 1994; 9:673-678.
- [16]. Meffert RM, Langer B, Fritz ME. Dental Implants: A Review. *J Periodontol* 1992; 63: 859-870.
- [17]. Neale D, Chee WW. Development Of Implant Soft Tissue Emergence Profile: A Technique. *J Prosthet Dent* 1994; 72: 364-7
- [18]. Siebert JS. Reconstruction Of Deformed, Partially Edentulous Ridges Using Full Thickness Inlay Graft, 1: Technique And Wound Healing. *Compend Contin Educ Dent* 1983; 4: 437-53
- [19]. Albrektsson T, Dahl E, Enbom L, Et Al. Osseointegrated Oral Implants. A Swedish Multicenter Study Of 8139 Consecutively Inserted Nobelpharma Implants. *J Periodontol* 1988; 59: 287-296.
- [20]. Hebel KS, Gajjar RC. Cement-Retained Versus Screw Retained Implant Restorations: Achieving Optimal Occlusion And Esthetics In Implant Dentistry. *J Prosthet Dent* 1997; 77: 28-35.