

## Treatment Of Class Ii Non-Compliant Patient: Pendulum Appliance

<sup>1</sup>Dr. Krutasvi Desai, <sup>2</sup>Dr. Monisha V, <sup>3</sup>Dr. Falguni Mehta, <sup>4</sup>Dr. Renuka Patel

<sup>1</sup>PG Student, Department of Orthodontics and dentofacial Orthopaedics, Government Dental College and Hospital, Ahmedabad, Gujarat, India.

<sup>2</sup>PG Student, Department of Orthodontics and dentofacial Orthopaedics, Government Dental College and Hospital, Ahmedabad, Gujarat, India.

<sup>3</sup>HOD and Professor, Department of Orthodontics and dentofacial Orthopaedics, Government Dental College and Hospital, Ahmedabad, Gujarat, India.

<sup>4</sup>Professor, Department of Orthodontics and dentofacial Orthopaedics, Government Dental College and Hospital, Ahmedabad, Gujarat, India.

---

### **Abstract:**

Angle's Class II Malocclusion Can Be Treated By Distalizing Maxillary Posterior Teeth In Cases With Skeletal Class I Base With Straight Profile, Horizontal Growth Pattern, Retroclined And /Or Crowded Maxillary Anteriors And Deep Bite. A 13 Years Old Male Patient With Similar Malocclusion And Severely Crowded Upper Anterior Teeth, Palatally Displaced Lateral Incisor, With Midline Shift Was Treated By Distalizing Maxillary Molars Thus Creating Space For Crowded Upper Anteriors. Orthodontic Treatment Was Carried Out In Two Stages: Distalization Of Upper Posterior Teeth Using Pendulum Appliance Distalizing Upper Molars Thus Creating Space For Crowded Anterior Teeth Followed By Fixed Mechanotherapy Aligning Them In The Second Stage. Post Treatment Result Shows Marked Improvement In Teeth Alignment, Profile And Smile Esthetics.

**Keywords:** Distalization, Pendulum, Class II Non-Compliant

---

Date of Submission: 02-07-2023

Date of Acceptance: 12-07-2023

---

### I. INTRODUCTION

Molar distalization is used in orthodontics to distalize molar teeth distally in the arch. There are several extra oral and intra oral methods to distalize the molar or to say gain space by distalization. Distalization with extra oral appliances highly rely on patient's compliance. Therefore, in early 1980s therapeutic approaches focused on development of intra arch appliances. Pendulum appliance, Distal jet, Distal propeller are some intra oral appliances used for distalization of molars. Pendulum appliance is one of the widely used intra oral appliance It is non-invasive and less patient compliance is required. Miniscrews can be used for distalization however this procedure is invasive.

Pendulum appliance was first introduced by Hilgers in 1992. According to Hilgers this appliance produces a broad, swinging arc or pendulum of force from the midline of the palate to the upper molars. This procedure is frequently used in patients with Class II malocclusion on skeletal Class I base. Other indications for pendulum appliance being deep bite, flat profile, crowded upper anteriors and horizontal growth pattern.

## II. CASE REPORT

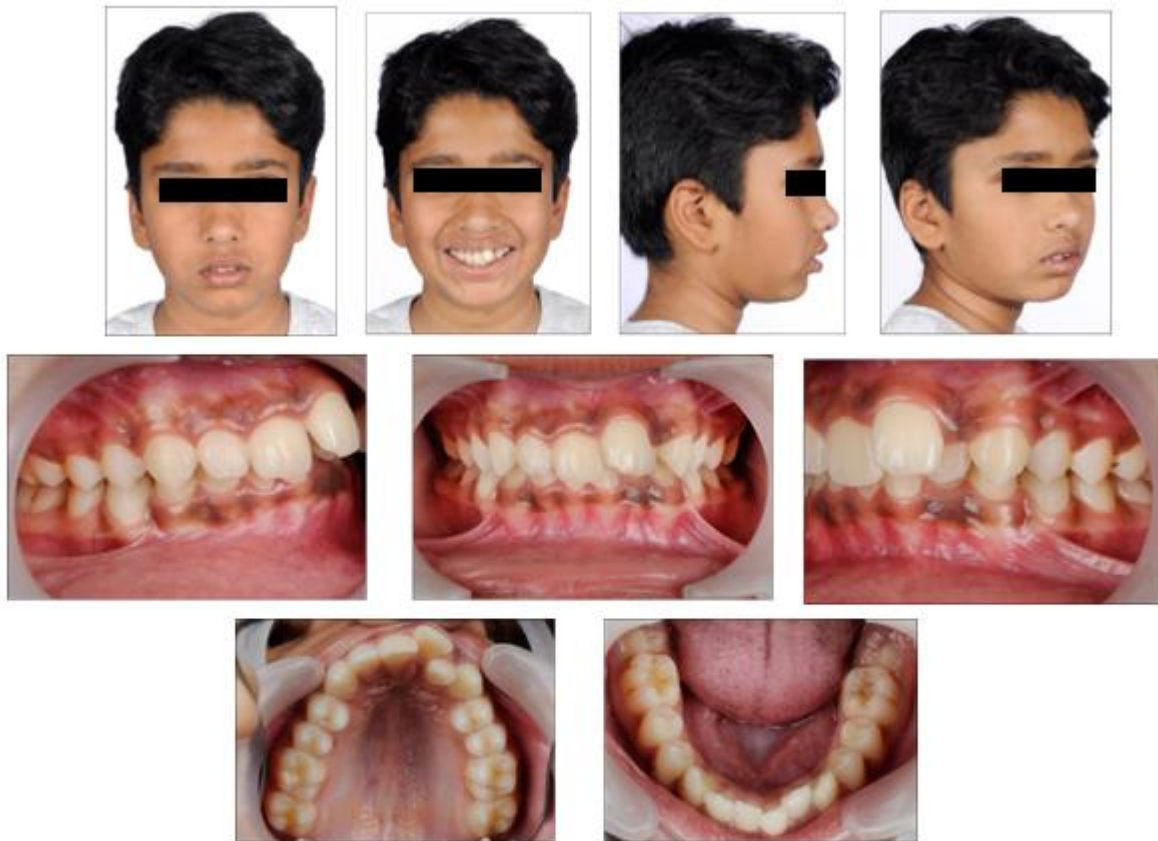

Fig.1, Pre-treatment extra oral and intra oral photographs

A Thirteen year old male patient reported in the Department of Orthodontics and Dentofacial Orthopaedics, Government Dental College and Hospital, Ahmedabad with the chief complaint of irregularly placed upper front teeth. Patient was diagnosed with Angle's Class II molar relation and end on canine relation bilaterally superimposed over skeletal Class I maxillo- mandibular base relationship, average growth pattern and mesoprosopic facial form, crowding in upper and lower anterior region, and anterior deep bite. Patient was having straight soft tissue profile, potentially competent lips, non-consonant smile arc.

Treatment objectives were to achieve normal alignment and levelling in upper and lower arches, to achieve Angle's Class I molar and canine relationship, consonant smile arc and to improve soft tissue esthetics.

Taking into consideration of clinical features and cephalometric readings, treatment plan was decided to give pendulum appliance for distalization of maxillary molars followed by fixed mechanotherapy.

For this pendulum appliance was fabricated by banding of upper first premolars and molars, and Nance palatal button for anchorage. Springs were prepared from 0.032" TMA wire (Fig.2). They were activated before cementation of this assembly. Activation was done at the interval of 3 weeks. Period of treatment with pendulum appliance- 5 months, where in maxillary molars were bodily distalized by 3 mm on both the sides (Fig.3).

Post distalization Nance palatal button maintained the distalization space, which was achieved by pendulum appliance.

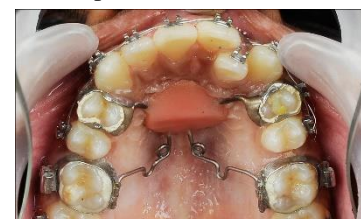
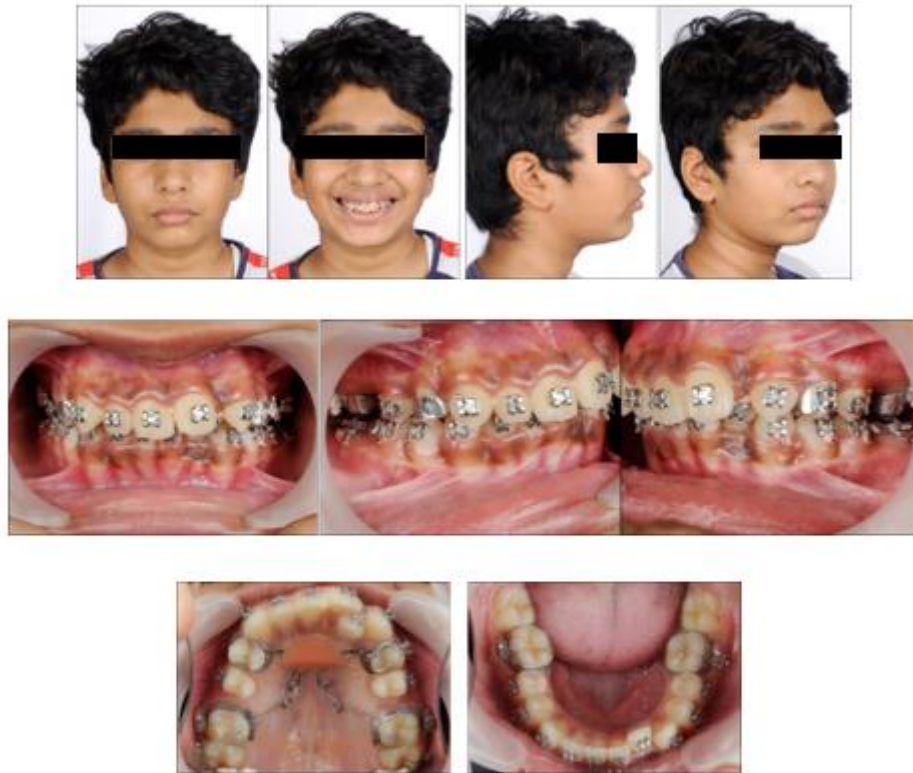
Fig.2, Pendulum appliance



*Fig.3, Post distalization extra oral and intra oral photographs*

Upper and lower teeth were bonded with 0.022" MBT bracket and premolars were distally driven into space obtained by distalizing upper first permanent molars. This helped in alignment and correction of crowded upper anteriors. Post fixed orthodontic treatment crowding was relieved both in upper and lower anterior teeth. Both upper and lower arches were well aligned, deep bite was relieved and consonant smile arc achieved.

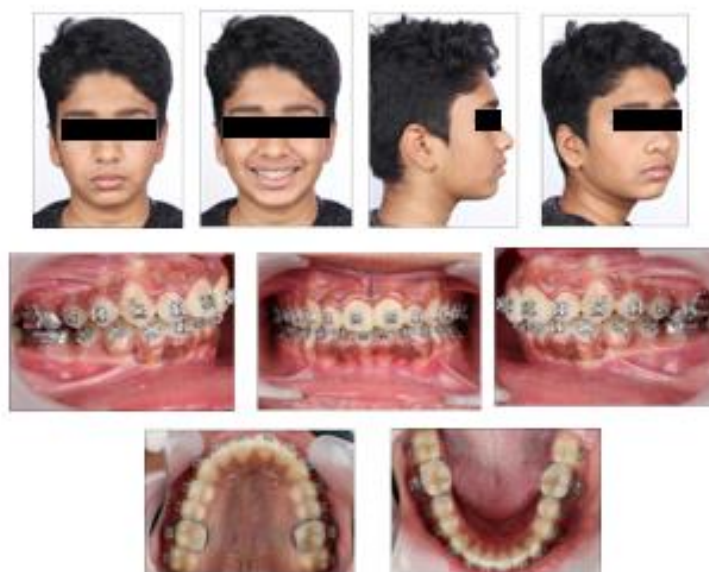

Fig.4, Post treatment extra oral and intra oral

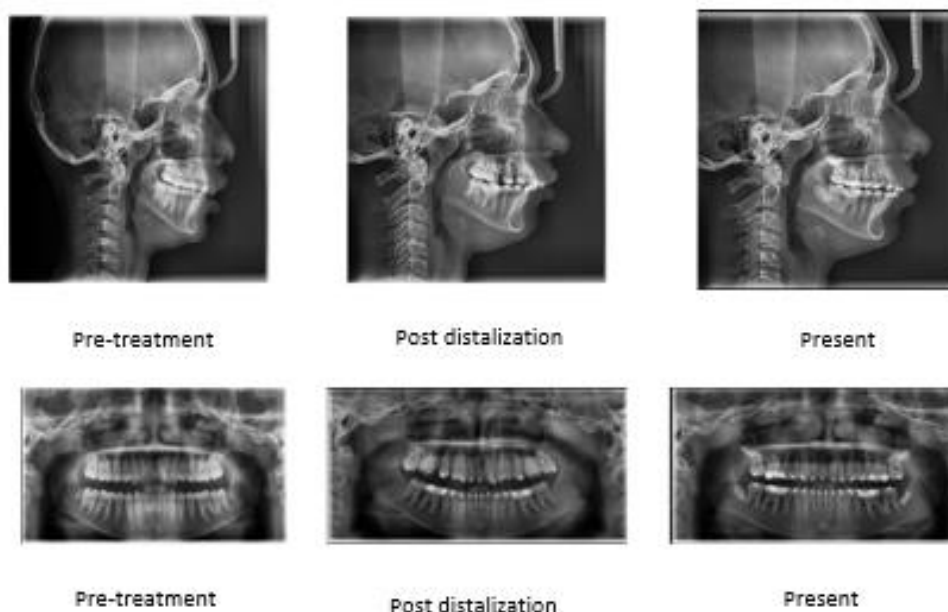


Fig.5, Lateral cephalogram and OPG

PARAMETERS	PRE-TREATMENT	POST DISTALIZATION	PRESENT
DENTOALVEOLAR PARAMETERS			
Upper 1 to NA (mm)	4 mm	8 mm	5 mm
Upper 1 to NA (angle)	16°	27°	24°
I to SN	100°	110°	105°
Lower 1 to NB (mm)	5 mm	6 mm	6 mm
Lower 1 to NB (angle)	27°	30°	30°
IMPA	93°	95°	95°
Interincisal angle	132°	122°	125°
Upper molar to ptv	18 mm	15 mm	15 mm

SOFT TISSUE PARAMETERS			
Nasolabial angle	87°	87°	93°
Basic upper lip thickness	12 mm	15 mm	15 mm
Upper lip thickness	11 mm	13 mm	13 mm
Lip strain	2 mm	2 mm	2 mm
Upper lip length	17 mm	17 mm	17 mm
Interlabial gap	6 mm	0 mm	0 mm
Lower lip length	32 mm	32 mm	32 mm
Mx 1 exposure	4 mm	0 mm	0 mm
Upper lip- S line	4 mm	4 mm	3 mm
Lower lip- S line	5 mm	5 mm	4 mm

Table.1, *Cephalometric readings*

### III. DISCUSSION

Hilgers pendulum treatments give favourable outcome with careful selection of patients. Patients with Class II malocclusion on skeletal Class I base, horizontal growth pattern, straight profile, preferably non-erupted maxillary second permanent molars, and increased naso-labial angles are the most appropriate candidates. In contrast to extra-oral tractions, which needs more pressure and longer periods of time to have the same impact, pre activation of Pendulum appliance allows movement of 1.02 mm each month with a force of 200gms to 250gms approximately.

In this case patient came with the chief complaint of irregularly placed upper front teeth and diagnosed with the Angle's Class II molar relation and end on canine relation bilaterally superimposed over skeletal Class I maxillomandibular base relationship. Distance from upper first molar to ptv was 18 mm, favourable to distalize the molars. Treatment objective here was to relieve the crowding, achieve Class I canine and molar relationship, consonant smile arc, maintain straight soft tissue profile. Pendulum appliance was decided to be the appliance to distalize the molars and achieve Class I molar relationship by gaining space to be utilised to relieve crowding. After pendulum appliance treatment, molars were in Class I relation, upper anteriors mildly proclined. However not much change was noted in facial profile. Molar distalization achieved was 3 mm on both sides. Premolars and anterior teeth were aligned utilizing this space. Crowding of upper anteriors was relieved and proper alignment was achieved.

There was improvement in inclination of upper and lower anteriors from 16° to 24° in upper and 27° to 30° in lower teeth. Interincisal angle also improved from 132° to 125°. Thus, molar distalization followed by fixed appliance helped us to achieve Class I molars, canine guided occlusion, and well-balanced profile.

### IV. CONCLUSION

Distalization is a proven method to gain space for correction of Class II molars and canines. This approach is non-invasive and efficient method and should be used when soft tissue aesthetics are good.

### REFERENCES

- [1]. Hilgers JJ. The Pendulum Appliance For Class II Non-Compliance Therapy. *J Clin Orthod.* 1992;26:706-14.
- [2]. Mehta F, Gandhi V. MAXILLARY MOLAR DISTALIZATION WITH THREE DIFFERENT CUSTOM MADE APPLIANCES: 3 CASES. *Guident.* 2015 Jan 1;8(2).
- [3]. Anistoroaei D, SÁVEANU CI, Golovcencu L, Cernei ER, Zegan G. PENDULUM APPLIANCE IN THE TWO-PHASE ORTHODONTIC TREATMENT. A CASE REPORT. *International Journal Of Medical Dentistry.* 2018 Jan 1;22(4):387-92.
- [4]. Nandeshwar N, Banerjee S, Jawalekar R, Shenoy U. Class II Correction By Maxillary Molar Distalization With Pendulum Appliance- A Case Report. *Journal Of Dental Specialities.* 2021 Oct 15;9(1):26-8.
- [5]. Keim RG, Berkman C. Intra-Arch Maxillary Molar Distalization Appliances For Class II Correction. *J Clinorthod.* 2004;38(9):505-11.
- [6]. Antonarakis GS, Kiliaridis S. Maxillary Molar Distalization With Noncompliance Intramaxillary Appliances In Class II Malocclusion. A Systematic Review. *Angle Orthod.* 2008;78(6):1133-40.
- [7]. Cetlin NM, Ten Hoeve A. Nonextraction Treatment. *J Clinorthod.* 1983;17(6):396-413.