

A RARE CASE OF RUPTURED RUDIMENTARY HORN PREGNANCY:CASE REPORT

Dr. Tejasvi Arjaria(1) ,Dr.Vaishali Chaurasia(2)

(1)PGMO, Department of obstetrics and gynaecology , DH Chhatarpur , Madhya Pradesh, India.

(2)Professor,People's medical college Bhopal,Madhya Pradesh,India.

Abstract:

Background

The incidence of uterine congenital anomalies because of Mullerian defects in the normal fertile population is 3.2%.A unicornuate uterus accounts for 2.4%-13% of all mullerian anomalies.72-85% of the rudimentary horn are non- communicating with the cavity. Pregnancy in rudimentary horn is rare and life-threatening . Rudimentary horn is non-communicating is 83% of cases. Pregnancy occurs in non-communicating horn of unicornuate uterus by transperitoneal migration of sperm or fertilized ovum. The incidence of pregnancy in rudimentary horn is 1/76,000 .Rupture of rudimentary horn pregnancy in second trimester is a usual presentation with patient presenting in shock and massive intraperitoneal hemorrhage.Early diagnosis and fast management are necessary to decrease the mortality and morbidity .We report an unusual rudimentary horn rupture pregnancy which present as chronic ruptured ectopic pregnancy of left adnexa with signs of shock.

Keywords: Rudimentary horn pregnancy , Mullerian anomaly, monochorionic twin.

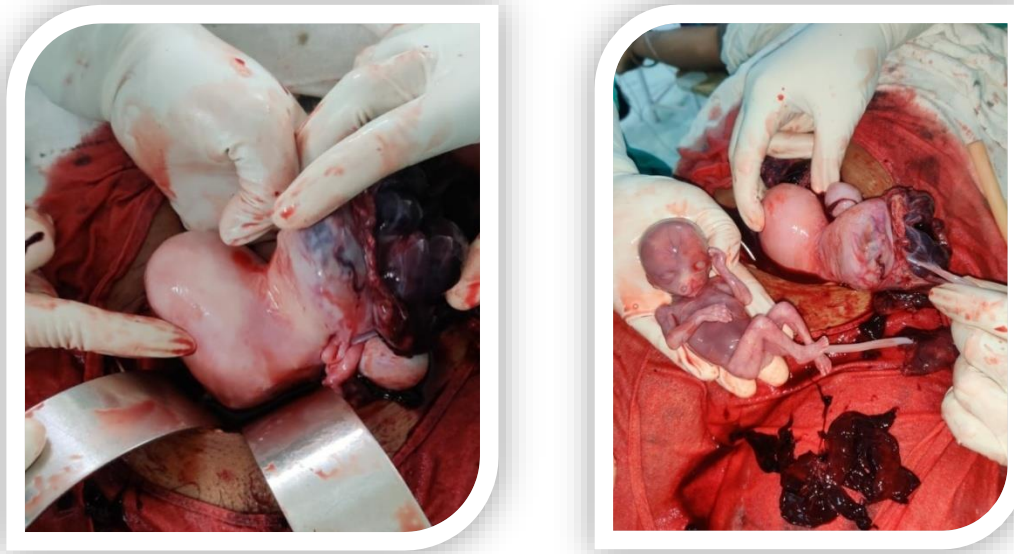
Date of Submission: 17-07-2023

Date of Acceptance: 27-07-2023

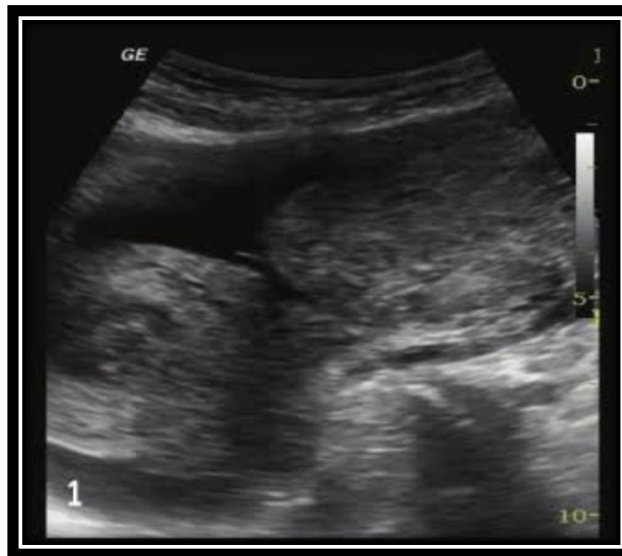
I. Case report

A 20 years old G2P1L1A0 with previous normal vaginal delivery at 20week of gestation reported to department of obstetrics and gynecology at Gandhi medical college Bhopal as a referral case from private hospital .She was presented to private hospital with symptom of pain abdomen where on ultrasound report left adnexal mass without cardiac activity revealed. she was referred as a case of suspicious ectopic pregnancy. In our hospital on general examination lady was in hypovolumic shock with rapid feeble pulse and severe pallor with tense and distended abdomen, and the uterine size couldn't be made out. Bimanual examination revealed bulky uterus with mass of left adnexa .There was no vaginal bleeding. As the patient was in shock she was taken for emergency laprotomy. At laprotomy there was a rupture of left rudimentary noncommunicating horn of 5,4.5,5cm of unicornuate uterus with the fetus lying free in the peritoneal cavity weighing 480gm and placenta lying inside the ruptured horn and the hemoperitoneum of around 1.5 liters. Both the tubes and ovary were normal. The rudimentary horn was excised .After achieving homeostasis abdomen was closed in layers after keeping a drain. The lady was transfused 3 units of blood. Her postoperative recovery was good. She was discharged from the hospital on the eighth postoperative day.

II. INTRA OPERATIVE FINDINGS



ULTRASONOGRAPHY



III. Discussion :

Casper Wolff described the mesonephros in 1759 at the age of 26 yrs. The paired structures were named wolffian bodies by the 19 century embryologist, Rathke, in recognition of Wolff's initial discovery and description. The mesonephric (wolffian) and paramesonephric (Mullerian) ducts are discrete primordia that coexist in all embryo upto 8 weeks. The Mullerian ducts develop later into fallopian tubes, uterus and upper portion of vagina in females. Rudimentary horn pregnancy with a unicornuate uterus results due to failure of the complete development of one of the Mullerian ducts and incomplete fusion with the contralateral side. A rudimentary horn with a unicornuate uterus results due to failure of the complete development of one of the mullerian ducts and incomplete fusion with the contra lateral side. The first case of uterine rupture with rudimentary horn was reported in 1669 by Mauriceau. The timing of rupture varies from 5 to 35 weeks depending on the horn musculature and its ability to hypertrophy and dilate. 70-90% rupture occurs before 20 weeks which can be catastrophic. As the uterine wall is thicker and more vascular, bleeding is more severe in rudimentary horn rupture. Kadan and Romano described rudimentary horn rupture as the most significant threat to pregnancy and a life-threatening situation. Early diagnosis of the condition is essential and challenging. Ultrasound, hysterosalpinogram, hysteroscopy, laparoscopy, and MRI are diagnostic tools. Primary strategy of management of rudimentary horn is surgical removal. Dicker et al. removed a small rudimentary

horn through the suprapubic laparoscopic port. Medical management with methotrexate and its resection by laparoscopy is also reported.

IV. Conclusion

Despite advances in ultrasound and other diagnostic modalities, prenatal diagnosis remains elusive, with confirmatory diagnosis being laprotomy. The diagnosis can be missed in ultrasound especially in inexperienced hands. Precious time may be lost due to delay in diagnosis and the general condition of the patient may worsen as in our case. Timely resuscitation, surgery and blood transfusion are needed to reduce the morbidity and mortality of the patients. There is a need for an increased awareness of this condition especially in developing countries where the possibility of detection before pregnancy or before rupture is unlikely and precious time is lost in shifting these women to the referral hospital.

References:

- [1]. B. W. Rackow And A. Arici, "Reproductive Performance Of Women With Müllerian Anomalies," *Current Opinion In Obstetrics And Gynecology*, Vol. 19, No. 3, Pp. 229–237, 2007.
- [2]. G. G. Nahum, "Rudimentary Uterine Horn Pregnancy: The 20th-Century Worldwide Experience Of 588 Cases," *Journal Of Reproductive Medicine For The Obstetrician And Gynecologist*, Vol. 47, No. 2, Pp. 151–163, 2002
- [3]. L. E. Fitzmaurice, R. M. Ehsanipoor, And M. Porto, "Rudimentary Horn Pregnancy With Herniation Into The Main Uterine Cavity," *American Journal Of Obstetrics And Gynecology*, Vol. 202, No. 3, Pp. E5–E6, 2010.
- [4]. B. W. Rackow And A. Arici, "Reproductive Performance Of Women With Müllerian Anomalies," *Current Opinion In Obstetrics And Gynecology*, Vol. 19, No. 3, Pp. 229–237, 2007.
- [5]. G. G. Nahum, "Rudimentary Uterine Horn Pregnancy: The 20th-Century Worldwide Experience Of 588 Cases," *Journal Of Reproductive Medicine For The Obstetrician And Gynecologist*, Vol. 47, No. 2, Pp. 151–163, 2002
- [6]. L. E. Fitzmaurice, R. M. Ehsanipoor, And M. Porto, "Rudimentary Horn Pregnancy With Herniation Into The Main Uterine Cavity," *American Journal Of Obstetrics And Gynecology*, Vol. 202, No. 3, Pp. E5–E6, 2010.
<https://pubmed.ncbi.nlm.nih.gov/34702216/>
- [7]. *Plos One*. 2019 Jan 25;14(1):E0210788. Doi: 10.1371/Journal.Pone.0210788. Ecollection 2019.
- [8]. *J Med Ultrason* (2001). 2015 Jan;42(1):117-20. Doi: 10.1007/S10396-014-0582-4. Epub 2014 Oct 17.
- [9]. *J Minim Invasive Gynecol*. 2022 Jul;29(7):816-817. Doi: 10.1016/J.jmig.2022.04.008. Epub 2022 Apr 27. Pmid: 35487431