

Immediate Loading Of Edentulous Maxilla With Implant-Supported Hybrid Prosthesis: A Case Report

Dr. Namrata Bhadwal¹, Dr. Aditya Chaudhary², Dr. Anju Aggarwal³ Dr. Punit R S Khurana⁴, Dr. Shivani Seth⁵

Post Graduate, Department of Prosthodontics, Crown and Bridge, Oral implantology and Maxillofacial Prosthodontics¹

Professor, Department of Prosthodontics, Crown and Bridge, Oral implantology and Maxillofacial Prosthodontics²

Professor, Department of Prosthodontics, Crown and Bridge, Oral implantology and Maxillofacial Prosthodontics³

Professor and HOD, Department of Prosthodontics, Crown and Bridge, Oral implantology and Maxillofacial Prosthodontics⁴

Post Graduate, Department of Prosthodontics, Crown and Bridge, Oral implantology and Maxillofacial Prosthodontics⁵

Abstract:

Background: The Application Of Implants Has Significantly Expanded The Scope And Quality Of Prosthodontic Rehabilitation. The Patient's Function When Wearing A Conventional Complete Denture Prosthesis May Be Reduced To 60% Of That Formerly Experienced With Natural Dentition. Dental Implants Have Provided A Paramount Success Rate In Patients With Maladaptive Denture-Wearing Experience. This Case Report Describes The Steps Involved In Transitioning From An Edentulous Maxilla With Hopeless Teeth To A Full-Arch Implant-Supported Provisional Prosthesis. A Patient Came With A Failing Dentition In Maxilla, And After The Treatment, The Patient Had A Full-Arch, Implant-Supported Acrylic Complete Denture In The Maxilla. The Report Describes The Steps Involved In The Prosthodontic Rehabilitation; A Cost-Effective Treatment Plan, The Restoration Of Vertical Dimension, An Implant-Level Impression, A Verified-Master Cast.

Keywords: Implant-Supported Prosthesis, Full-Arch Maxillary Prosthesis, Transitional Prosthesis, Interim Prosthesis

Date of Submission: 22-06-2023

Date of Acceptance: 02-07-2023

I. Introduction

The goal of modern dentistry is to restore the normal contour, function, comfort esthetics, speech, and health regardless of the atrophy, disease, or injury of the stomatognathic system.^[1] However, the more the number of teeth missing in a patient, it becomes more difficult to achieve this goal with traditional dentistry.

Dental implantology is a term used today to describe anchoring of alloplastic material into the jaws to provide support and retention for prosthetic replacement of teeth that has been lost.^[2] Dental implants have become a predictable treatment option to replace hopeless or missing teeth because of their documented long-term success rates.^[3] Since the introduction of implant osseointegration by Brånemark in the 1960s, the use of implant-supported restorations as a treatment option as opposed to conventional prosthodontic restorations has increased, especially in completely edentulous arches.^[4]

However, full-arch transition from a hopeless dentition to a prosthesis supported by dental implants remains a challenge. One treatment option for this process is the use of implants, an approach that allows for the transitioning of full-arch reconstructions from teeth to implant-supported prostheses.

The patient's function when wearing a conventional complete denture prosthesis may be reduced to 60% of that formerly experienced with natural dentition. Implant prosthesis offers a predictable treatment course than the traditional restorations.^[5] The increased need and use of implant-related treatments result from the combined effect of a number of factors including psychological aspects of tooth loss, aging population, tooth loss related to age, anatomic consequences of edentulism, poor performance of removable prosthesis, and predictable long-term results of implant-supported prostheses. The purpose of this clinical case report is to describe the steps involved in transitioning from an edentulous maxilla with hopeless teeth to a full-arch implant-supported provisional prosthesis.^[6]

II. Case Report

A 60-year-old male patient reported to the Department of Prosthodontics with a chief complaint of mobile bridge in the maxillary anterior region and wanted replacement of the same. On intraoral examination, Kennedy's class I edentulous span was found. Clinical and radiographic examinations were carried out and revealed multiple missing teeth, non-restorable teeth, periodontal disease, and bone loss. The final treatment plan that was then proposed to and accepted by the patient which included extraction of all remaining teeth in the maxilla, delivery of a provisional fixed restoration supported by six implants.

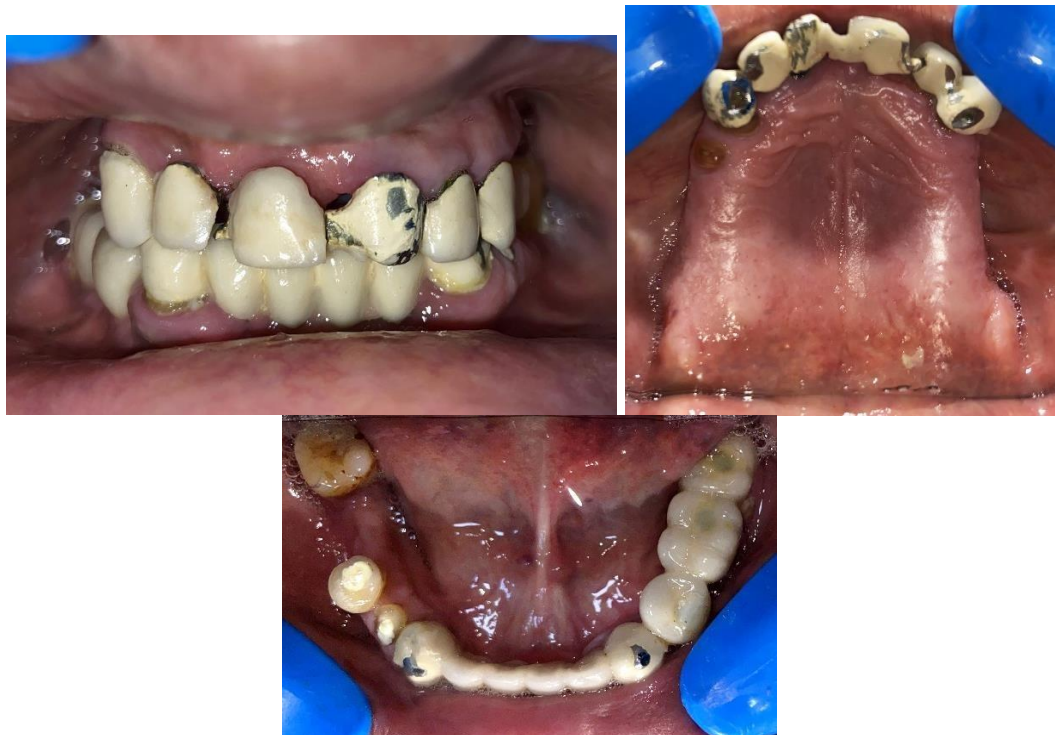

Figure 1: Pre operative intra-oral view

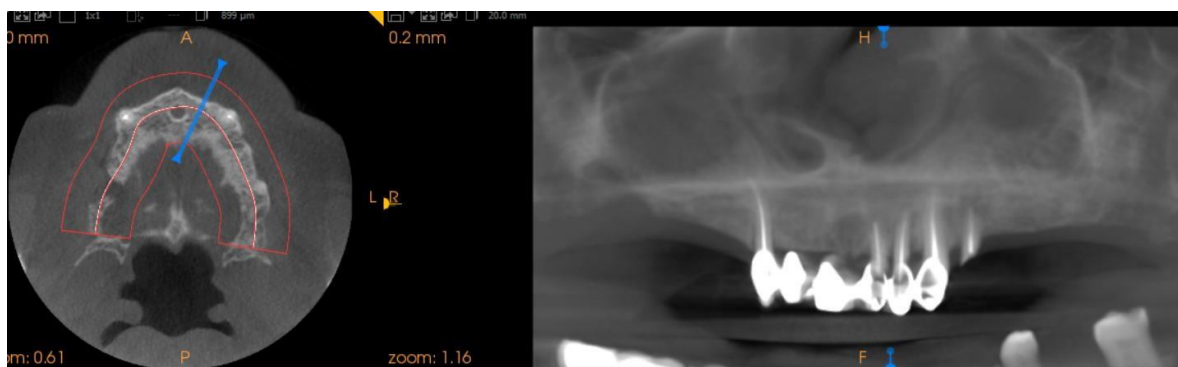

Figure 2: Treatment planning using CBCT

Surgical Phase

Prior to surgical phase, the fixed prosthesis in the maxillary arch was removed which was then followed by extraction of the remaining teeth irt 12,13, 21, 22, 23 and 24. The sockets were debrided with curettes (figure 3). A mid-crestal incision was performed, and a full-thickness flap was raised. Implants were placed irt 12,13,15,21,23,25 (figure 4). Following implant placement, temporary abutments were positioned on the implant and interrupted sutures wereplaced to achieve uneventful healing (figure 5)

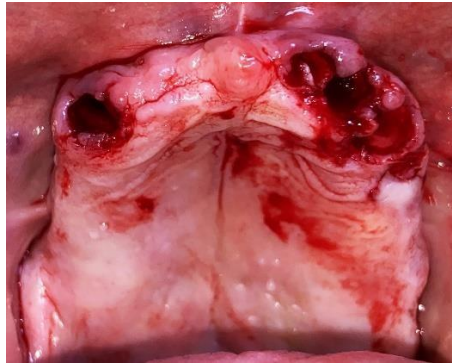

Figure 3: Intra oral view after extraction

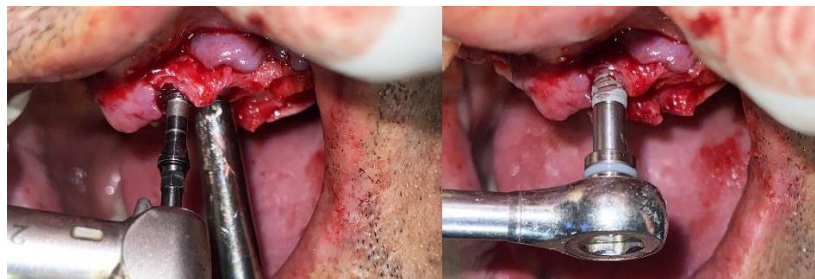

Figure 4: Implant placement

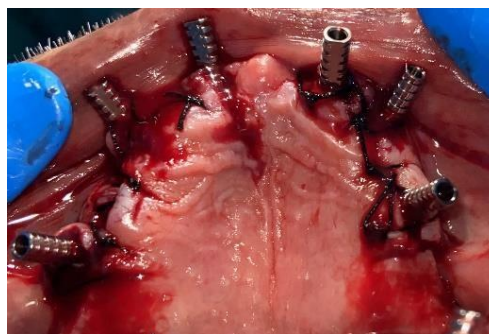


Figure 5: Post operative view with temporary abutments on the implant and sutures placed

Prosthetic phase

Post healing the temporary cylinders were removed and impression copings were placed on the implant. A splint type implant-level impression was taken with putty-light body (figure 6). The implant in the region irt 21 was left as a sleeping implant because it lacked primary stability.

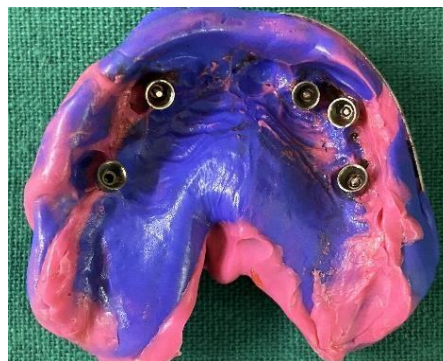

Figure 6: Implant-level impression with Putty- light body

Immediate Loading Of Edentulous Maxilla With Implant-Supported Hybrid Prosthesis: A Case Report

In the laboratory, the implant analogue was attached to the impression. A soft-tissue application material was applied and type IV dental stone was poured. A verification jig was made with pattern resin on the master cast and was verified in the patient's mouth (figure 7).

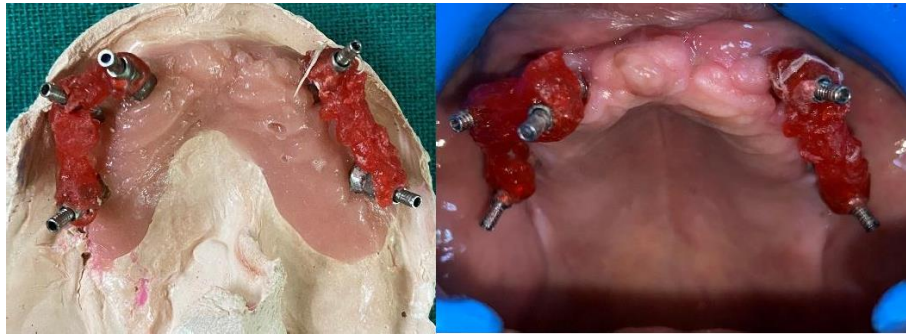


Figure 7: A verification jig on the master cast and in the patient's mouth

The patient's vertical dimension was recorded and maxillary rim was adjusted accordingly against the natural mandibular teeth (figure 8). The teeth arrangement was done and denture was cured with the temporary cylinders in place (figure 9). Only the crest of the denture base was allowed to remain in contact with the residual ridge and the lingual, labial, and buccal flanges were removed to the desired length. The prosthesis was highly polished to minimize plaque retention and was seated in the mouth (figure 10). Following this, the required occlusal adjustments were made. The screw access holes were covered with Teflon tape followed by composite (figure 11). The patient was given the post insertion recommendations. The patient was recalled after four months for the final prosthetic procedures.

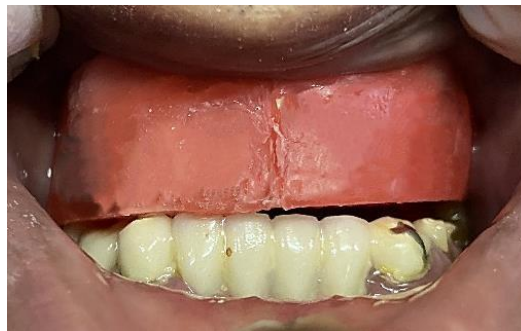

Figure 8: Jaw relation and bite registration

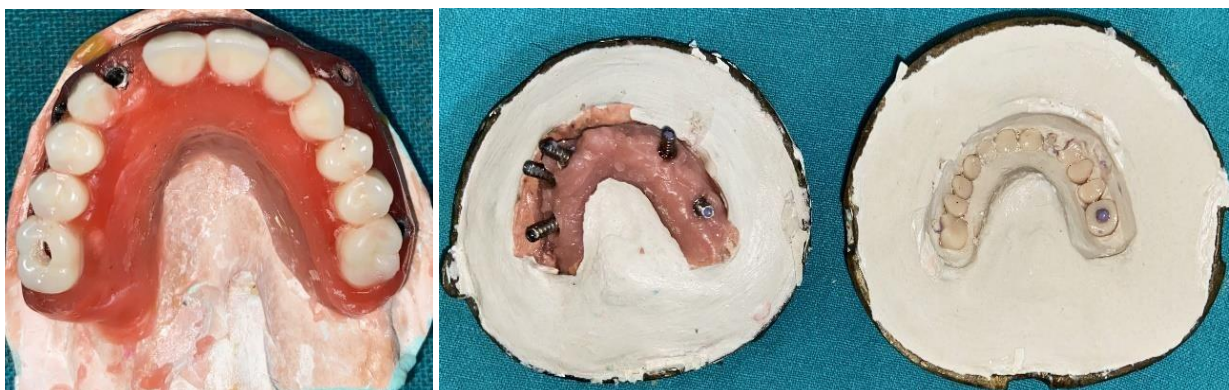

Figure 9: Wax-up and curing of the denture with the temporary cylinders in place

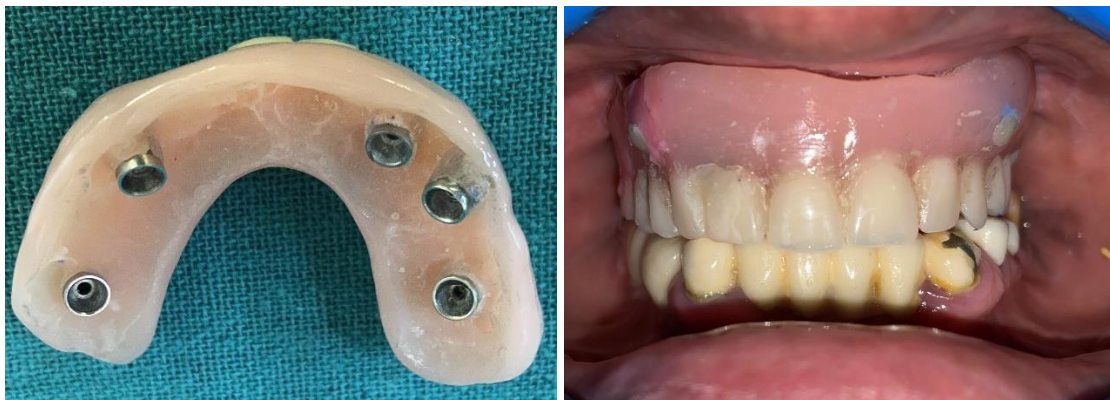

Figure 10: Processed and polished denture base.

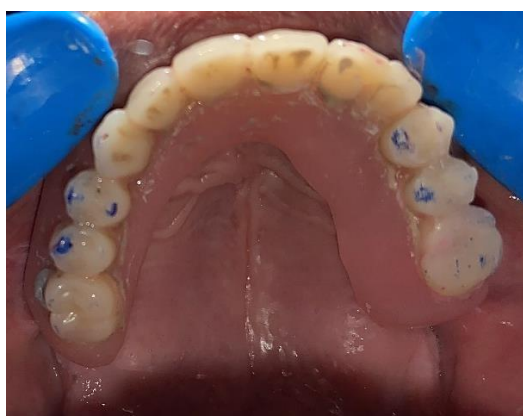

Figure 11: Occlusal view of the provisional prosthesis

III. Discussion

A potentially edentulous patient usually prefers a fixed prosthesis over a removable prosthesis to restore function and aesthetics. The treatment modalities with dental implants include fixed and removable prostheses in several configurations and by means of various types of implant bodies and attachments.^[7] Among them, screw-retained implant prostheses have accomplished well in cases needing fixed complete dentures.^[8]

A completely edentulous state can be successfully rehabilitated with 4–6 implants supporting a fixed complete denture.^[9] In this case report, the maxilla was restored with six implants. The follow-up evaluation of the prosthesis and the patient's experience suggest the modality to be cost effective and durable. However, previous reports suggest that all-on-4 concept can also provide a durable result.^[10,11]

The success rate of implants in the maxilla is less than that of the mandible due to various factors such as residual ridge morphology, bone quality and biomechanics. Previous reports suggest a remarkable success rate of FCDs with six implants in maxilla.^[12,13]

Such six implant-supported, shortened dental arch prostheses offer adequate mastication, aesthetics and cost effectiveness;^[14] on the other hand, implant placement in the maxillary posterior region presents many hurdles.

IV. Conclusion

Implants have become the treatment of choice when missing teeth require replacement. Studies of the interaction between implant-supported restorations and the surrounding oral environment conclude that the human host response to oral implants is favorable. The treatment planning for an implant restoration is unique regarding the number of variables that may influence the therapy. A definitive treatment plan, a good surgical technique and an adequate prosthetic design are essential. Implant placement good functional and esthetic results, as well as addressing the social/psychological aspects of trauma.

References

- [1]. Dewan SK, Arora A, Sehgal M, Khullar A. Implant Failures: A Broader Perspective. *J Dent Implant*. 2015;5:53–9.
- [2]. Dholam KP, Gurav SV. Dental Implants In Irradiated Jaws: A Literature Review. *J Cancer Res Ther*. 2012;8(Suppl 1):S85–93.
- [3]. Paranhos KS, Froum SJ, Reis N, Cho SC. Long-Term Results Of Maxillary Full-Arch Reconstruction Using Transitional Implants: A Case Report With 20-Year Follow-Up. *Compend Contin Educ Dent*. 2022 Jan;43(1):40–45. PMID: 34951944.
- [4]. Brånemark PI, Adell R, Breine U, Et Al. Intra-Osseous Anchorage Of Dental Prostheses. I. Experimental Studies. *Scand J Plast Reconstr Surg*. 1969;3(2):81–100.
- [5]. Misch CE. *Dental Implant Prosthetics*. 2nd Ed. Amsterdam, Netherlands: Elsevier Health Sciences; 2014.
- [6]. Gowd MS, Shankar T, Ranjan R, Singh A. Prosthetic Consideration In Implant-Supported Prosthesis: A Review Of Literature. *J Int Soc Prev Community Dent*. 2017 Jun;7(Suppl 1):S1–S7.
- [7]. Zarb GA, Hobkirk J, Eckert S, Et Al. *Prosthodontic Treatment For Edentulous Patients: Complete Dentures And Implant Supported Prostheses*. 13 Edn. Elsevier Health Sciences, 2013
- [8]. Michalakis KX, Hirayama H, Garefis PD. Cement-Retained Versus Screw-Retained Implant Restorations: A Critical Review. *Int J Oral Maxillofac Implants* 2003;18:719–28.
- [9]. Tealdo T, Bevilacqua M, Pera F, Et Al. Immediate Function With Fixed Implant-Supported Maxillary Dentures: A 12-Month Pilot Study. *J Prosthet Dent* 2008;99:351–60.
- [10]. Maló P, De Araújo Nobre M, Lopes A, Et Al. The All-On-4 Treatment Concept For The Rehabilitation Of The Completely Edentulous Mandible: A Longitudinal Study With 10 To 18 Years Of Follow-Up. *Clin Implant Dent Relat Res* 2019;21:565–77.
- [11]. Lopes A, Maló P, De Araújo Nobre M, Et Al. The Nobelguide® All-On-4® Treatment Concept For Rehabilitation Of Edentulous Jaws: A Retrospective Report On The 7-Years Clinical And 5-Years Radiographic Outcomes. *Clin Implant Dent Relat Res* 2017;19:233–44
- [12]. Brånemark PI, Hansson BO, Adell R, Et Al. Osseointegrated Implants In The Treatment Of The Edentulous Jaw. Experience From A 10-Year Period. *Scand J Plast Reconstr Surg Suppl* 1977;16:1–132.
- [13]. Henry PJ. Tooth Loss And Implant Replacement. *Aust Dent J* 2000;45:150–72.
- [14]. Witter DJ, Van Palenstein Helderma WH, Creugers NH, Et Al. The Shortened Dental Arch Concept And Its Implications For Oral Health Care. *Community Dent Oral Epidemiol* 1999;27:249–58.