

The Effect of Platelet-Rich Fibrin on Bone Regeneration After Peri radicular Surgery in Healthy and Diabetic animals Histologic and Radiographic study

Shaban A.G.¹, Alkhawas M.A.², Gobran H.G.³, Islam.T.M.⁴, Tealab A.M.⁵

¹ (Ass. Lecturer at Department of Endodontics, Faculty of Dental Medicine/ Al-Azhar University, Cairo, Egypt)

² (Professor at Department of Endodontics, Faculty of Dental Medicine / Al-Azhar University, Cairo, Egypt)

³ –(Professor at, Department of oral biology, Faculty of Dental Medicine, Al-Azhar University, Cairo (boys)

⁴ –(Professor at Department of Endodontics, Faculty of Dental Medicine, Al-Azhar University, Cairo (boys)

⁵—(Ass. Professor at, Department of Pathology, Faculty of Medicine, Al-Azhar University, Cairo (boys)

Abstract:

Background: The aim of the study was to evaluate the effect of platelet-rich fibrin on bone regeneration after peri radicular surgery in healthy and diabetic dogs

Materials and Methods: Sixteen adult male dogs were included according to the power study (Eight dogs healthy and eight dogs diabetic). Root canal treatment of the mandibular 4th premolar teeth on both sides was done. one bone defect (7 mm × 7 mm × 7 mm each) was created in each side of the mandible in relation to the distal root of the selected teeth According to the bone cavity filling materials used there were two groups: platelet-rich fibrin (PRF) on the right side of the mandible and Blood Clot(BC) on the left side of the mandible. The animals were sacrificed at 1 week, 5 weeks, 9 weeks, and 13 weeks after the treatment and the mandibles were harvested. Dual-energy X-ray absorptiometry evaluation (DEXA) was done to evaluate the bone density at the defects. A histological evaluation was done to evaluate the new bone formation.

Results: 1 week: There was a significant difference between prf and control. (0.173 ± 0.003 & 0.111 ± 0.001), **5 weeks:** There was a significant difference between prf and control. (0.566 ± 0.008 & 0.279 ± 0.006) **9 weeks:** There was a significant difference between prf and control. (0.830 ± 0.003 & 0.372 ± 0.009), **13 weeks:** There was a significant difference between prf and control. (1.087 ± 0.037 & 0.433 ± 0.015) ($p < 0.000$)

Conclusion: PRF is a valuable and promising material that can be used as a grafting material in periradicular surgery to improve and accelerates bone regeneration

Key Word: Bone regeneration, bone density, platelet-rich fibrin, peri radicular surgery

I. Introduction

Periapical pathology occurs as a sequela of microbial insults from the root canal leading into excessive osteoclastic bone resorption circumscribing the root ⁽¹⁾. Failure of nonsurgical root canal treatment necessitates surgical intervention in the form of periradicular surgery ⁽²⁾.

The periradicular surgery aims to remove the pathological and granulation tissues in the periapical area. Removal of such tissues creates a surgical defect in the periapical area that requires bone substitutes to fill the defect. The type of bone substitute is a critical factor that affects the healing of the periradicular area. The best bone substitute is the autologous bone which has osteoconductive and osteoinductive properties that accelerate the healing of the periapical tissues⁽³⁾ Unfortunately, such type of bone substitute requires donor sites rather than the defective surgical one that leads to provoking pain, stress, and delayed surgery for the patient⁽⁴⁾ Platelet-rich in fibrin (PRF) which is an autologous leukocyte and platelet-rich fibrin biomaterial with a specific composition and three-dimensional architecture. PRF consists of a fibrin three-dimensional polymerized matrix in a specific structure, with the incorporation of almost all the platelets and more than half of the leukocytes along with growth factors and circulating stem cells. It supports and accelerates the healing process which introduces it as a promising blood derivative for bone healing. Diabetes mellitus is a chronic metabolic disease with high blood glucose levels⁽⁵⁾ Hyperglycemia may affect bone through enhanced expression of pro-inflammatory cytokines such as TNF α , which reduces osteoblast differentiation, and osteoblast activity and increases osteoblast apoptosis⁽⁶⁾. thus, the present study aims to evaluate radiographically and histologically the healing capacity induced by PRF in healthy and diabetics dogs at different periods.

II. Material And Methods

This interventional randomized control study was designed according to the ARRIVE guidelines and approved by the ethics committee of the Faculty of Dental Medicine, Al-Azhar University with Ref No: 115/137.

Study Design: interventional randomized control study

Study Location: General veterinary hospital in Al Abbassia, Cairo, Egypt.

Study Duration: October 2020 to April 2023.

Sample size: 16 dogs.

Sample size calculation: According to the power analysis of the study the minimum sample size was 8 dogs in each of the two main groups which have a 95 % power to detect a difference between means of 0.099 with a significance level (alpha) of 0.05 (two-tailed).

selection of dogs: sixteen healthy adult male purpose-bred dogs within the same age range and weighing 15–20 kg were used. The animals had no systemic diseases and were vaccinated. They were bred and housed under similar conditions at 22 °C room temperature, 40% humidity, and 12 h daylight cycle with Proper nutrition which is an important aspect to provide complete, balanced nutrition for dogs. Dogs were fed raw bones regularly as a part of a balanced diet and for good dental health. Meals were provided in a separate food bowl for each dog and maintained in a clean condition. Dogs always had access to clean drinking water at all times. Water containers were checked daily and maintained in a clean condition. The animals underwent clinical and radiographic evaluations in cooperation with the veterinary team of the general veterinary hospital in Al Abbassia, Cairo, Egypt.

Inclusion criteria:

1. Adult male dogs
2. Dogs with bilateral fourth premolars fully erupted with complete root formation.

Exclusion criteria:

1. Dogs have teeth with open apex
2. Dogs have teeth with pulp stones
3. Dogs have teeth with root resorption.
4. Dogs with congenital missing fourth premolar
5. Dogs with any intra-oral soft tissue laceration

Grouping of the selected dogs

Randomization of the dogs was done in which each dog was given number from 1 to 16 then using a randomizer software (www.randomizer.org) the selected dogs were assigned blindly and randomly into 2 main groups according to their medical status into two main groups:

Group A: Healthy dogs

Group B: Diabetic dogs

In which diabetes mellitus was induced in 8 of this 16 dogs while the other 8 dogs were kept in healthy condition.

Procedure methodology

Induction of diabetes in the diabetic group:

Diabetes mellitus was induced in 8 of the selected dogs by intraperitoneal injection of a solution of alloxan (Research-Lab Fine Chem, Industries, Mumbai, India) 50 mg/kg body weight, given on three consecutive days according to the protocol⁽⁷⁾. The preparation was used immediately after dissolution in 0.1 M acetate buffer at pH 4.4. Diabetes mellitus was confirmed by measuring blood glucose level using a blood glucose meter and the dogs were considered diabetic when blood glucose level was above 120 mg/ml as the normal blood glucose level is about 88-120mg/dL.

Preparation of the dogs

For good hygiene and reduced chances of infection, the dogs were bathed the day before surgery and all dogs were fasted 12 hours prior to anesthesia and were premedicated with a subcutaneous injection of 0.01 mg/Kg atropine immediately prior to surgery (atropine sulfate; ADWIA Co., Cairo, Egypt), followed by intramuscular injection of 1.2mg/Kg Xylaject (xylazine hydrochloride; ADWIA Co., Cairo, Egypt.) and intramuscular injection of ketamine HCL 15mg/Kg body weight (EIMC. Pharmaceuticals co, Egypt).

Animal anesthetization:

The dogs were placed on the operating table in a supine position with tilted heads to provide an unblocked air-way, after that A cannula, 18-20 gauges, was fixed in the radial vein, and general anesthesia of the dogs was maintained by 25mg/Kg intravenous incremental doses of 2.5% solution of thiopental sodium (EIPICO, Cairo, Egypt). One-third of the estimated dose was injected within 15 seconds, the remainder was administered slowly until loss of pedal and corneal reflexes, and development of shallow regular respiration.

PRF preparation

PRF preparation was performed in accordance with the PRF protocol prepared by Choukroun⁸. A 10 ml of dog's blood was extracted and placed in two 5 ml sterile pre-vacuumed plain glass tubes. The tubes were centrifuged at 3000 rpm for 10 min. After centrifugation, the blood in the tube was separated into three distinct zones: the upper layer of platelet-poor plasma, PRF in the middle, and red blood cells at the bottom. The tubes were maintained until the bony cavities were prepared

Preparation of the operative field:

All procedures were conducted under a clean aseptic protocol. Isolation of the field for endodontic treatment of the mandibular 4th premolar teeth was conducted on both sides. obturation of root canals using cold lateral compaction technique. The access cavity was filled with resin-modified glass ionomer filling material (Dentsply Maillefer, Ballaigues, Switzerland).

Surgical Procedure: Prior to surgical intervention, 1.8 ml of 2% lidocaine with 1: 100,000 norepinephrine (Amriya Pharm Industries, Alexandria, Cairo, Egypt) was injected into the surgical area. three-sided rectangular full-thickness mucoperiosteal buccal flaps were raised over the 4th mandibular premolar teeth on each side. Following flap elevation, a 7 × 7 mm metallic template was fixed opposite to the apical 1/3 of the distal roots of the 4th premolar teeth on each side. The position of the metallic template was confirmed radiographically. Then, a modified surgical bur with a metallic stopper welded at 8 mm from the tip of the bur was used to create the bone defect through the template. After creating the outlines of the bony cavity, the bone in between, including the apical 3 mm of the root, was removed with the periosteal elevator. Immediately after bony cavity creation, Retrograde cavity preparation using an ultrasonic tip was done followed by retrograde filling of the root with MTA material.

Sub Grouping of the Selected Dogs:

After grouping of the selected dogs into 2 main groups (group A: healthy dogs and group B: diabetic dogs) further subgrouping of each main group was done according to the bony cavity filling materials into 2 subgroups:

1-PRF on the bone cavity related to the fourth premolar on the right side (2 dogs for each scarification period)

2-Blood clot on the bone cavity related to the fourth premolar on the left side(2 dogs for each scarification period)

On the right side the bone cavity filled with prf while on the left side, the bone cavity was left empty(blood clot) as control after that the flaps were repositioned and sutured with 3-0 resorbable suture vicryl (polyglactin 910, E, Ethicon, Inc 2018).

Postoperative Care:

Non-steroidal, anti-inflammatory medications and antibiotics were recommended to decrease inflammation and pain so the dogs received amoxicillin and flucloxacillin (flummox: E.I.P.I.co, 10th of Ramadan city-industrial area, Egypt) as antibiotics at a dose of 50 mg/ kg per lean body weight per day and Zyleject, 3ml intramuscularly every 12 hours, for 5 days to control pain and infection under supervision of the vet physician. Dogs were kept on a soft diet composed of milk, rice, meat, liver, and bread for the first postoperative week. On the second postoperative week, dogs were able to eat the usual diet. All the dogs were evaluated clinically for assessments of their general health until sacrifice. Also, a daily examination was carried out for the presence of signs of infection such as redness, hotness, and the ability of the mouth to open, eat, and swallowing was conducted.

Scarification and sample harvesting:

Euthanasia was scheduled at the timetable of **1, 5, 9, and 13** weeks after surgery in which four dogs (two healthy and two diabetics) were sacrificed at each time. Euthanasia was done under general anesthesia provided by intravenous injection of pentobarbital (Socumb, Butler Company, Columbus, Ohio) at 30 mg/kg. The carotid arteries were exposed and cannulated then the dogs were euthanized with additional pentobarbital at a dose of 90 mg/kg. The dogs were perfused with 10% buffered formalin (Fisher Scientific, Fair Lawn, New

Jersey). The mandible was surgically removed and divided at the midline into two halves right and left then maintained in 10% buffered formalin until the time of bone density measurement.

Densitometric analysis:

The two mandibular halves of each dog were referred for bone density examination at the bone defect site by using dual-energy X-ray absorptiometry (DEXA) after sacrifice at each examination period. The measurements were performed using three sites axial scanner, and a bone mineral analyzer (lunar prodigy primo) at the Radiology Center of Raba Hospital, Nasr City, Cairo, Egypt. The bone mineral density (BMD) of each bone defect was measured at the 7×7 mm² region of interest by DEXA. This device was calibrated with a phantom of known mineral content. On the monitor, partial acquisition of images was shown while the scanner precede to analysis mode. When the scan finished the densitometric images saved and printed.

Fixation and Decalcification:

After completion of the densitometric analysis, specimens of mandibular blocks were sectioned and collected including the experimented teeth and half of the neighboring teeth on each side with the full thickness of the mandibular bone using an orthopedic electrical saw (tech, UK) under copious irrigation with normal saline. Specimens were replaced in 10% buffered formalin for fixation for up to 5 days at room temperature. Decalcification was performed by immersion of the bony specimens in equal volumes of 20% sodium citrate and 5% formic acid (Decal Chemical Corporation, Congers, New York) for a period of 2 months and the solution was renewed once per week.

Histologic Preparation and Evaluation:

Upon removal from the decalcifying solution, the specimens were placed under a running tap water wash for 20 minutes followed by immersion in 70% ethyl alcohol. The specimens were dehydrated through ascending gradations of ethanol and processed on a Leica TP 1020 dip n' dunk processor (Leica, Wetzlar, Germany) at 45 minutes per station in the following manner: one cycle of 70% ethanol, two cycles of 80% ethanol, two cycles of 95% ethanol, two cycles of 100% ethanol, two cycles of xylene and two cycles of paraplast paraffin (Kendall, Mansfield, Massachusetts) at 58°C. The tissues were removed from the storage cassettes, embedded in paraffin, and sectioned on a Leica Jung RM 2045 microtome (Wetzlar, Germany). Sections were made longitudinally in mesial-distal direction every 5 μ m starting from the occlusal surface to the inferior border of the mandible, then placed on the probe on plus slides. Tissues were stained with Hematoxylin and Eosin (H &E), then rinsed in cool running double-distilled water for 5 minutes, dipped in 0.5 eosin for 12 times, dipped in distilled water, and dehydrated in ascending concentrations of ethanol. The sections were dipped in xylene several times, mounted on slides, and covered with a coverslip with Cytoseal (Thermo Fisher Scientific, Waltham, MA). Finally, the slides were evaluated under light microscopy at up to 400 X magnification.

Histologic evaluation:

Histologic evaluation was conducted on the healing sites, in which three digital images were captured at 100 \times magnification for each HE-stained slide to describe the stage of new bone formation in the tested groups at each time.

Data management and analysis:

Data were collected, tabulated, and statistically analyzed using independent sample T to compare the two groups. The mean and SD values were calculated for each group in each test. The significance level was set at $P \leq 0.05$. Statistical analysis was performed using SPSS for Windows 25 software.

III. Result

Bone density results:

Effect of the testing materials

Healthy animal:

- 1- **1 week:** There was a significant difference between prf and control. (0.173 ± 0.003 & 0.111 ± 0.001)
- 2- **5 weeks:** There was a significant difference between prf and control. (0.566 ± 0.008 & 0.279 ± 0.006)
- 3- **9 weeks:** There was a significant difference between prf and control. (0.830 ± 0.003 & 0.372 ± 0.009)
- 4- **13 weeks:** There was a significant difference between prf and control. (1.087 ± 0.037 & 0.433 ± 0.015)

Bone Density	Healthy animal	Treatments	1 week	5 weeks	9 weeks	13 weeks
		platelet rich fibrin (prf)	Mean	0.173 ^a	0.566 ^a	0.830 ^a
SD	0.003		0.008	0.003	0.037	
Control	Mean	0.111 ^b	0.279 ^b	0.372 ^b	0.433 ^b	
	SD	0.001	0.006	0.009	0.015	
Sig.			**	**	**	**
P-value			0.000	0.000	0.000	0.000

Table (1): The mean, standard deviation (SD) values of bone density for treatments under time for healthy animals.

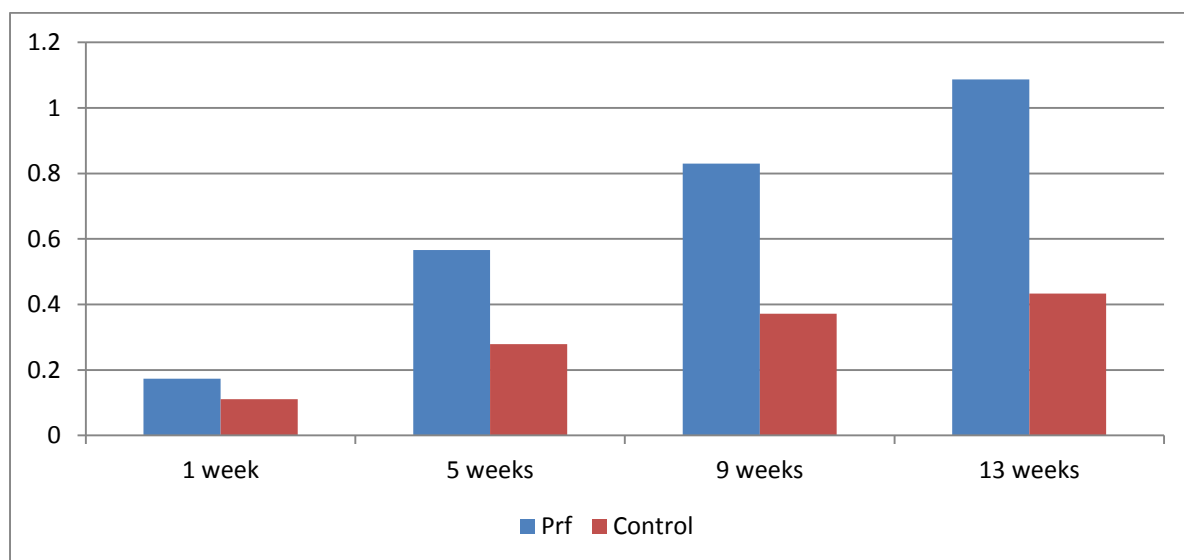


Fig 1. Bar chart for bone density for healthy animal under treatments effect.

Diabetic animals:

- 1- **1 week:** There was a significant difference between prf and control. (0.147 ± 0.009 & 0.089 ± 0.003)
- 2- **5 weeks:** There was a significant difference between prf and control. (0.432 ± 0.012 & 0.204 ± 0.013)
- 3- **9 weeks:** There was a significant difference between prf and control. (0.614 ± 0.007 & 0.254 ± 0.009)
- 4- **13 weeks:** There was a significant difference between prf and control. (0.751 ± 0.010 & 0.396 ± 0.005)

Bone Density	Diabetic animal	Treatments	1 week	5 weeks	9 weeks	13 weeks
		platelet rich fibrin (prf)	Mean	0.147 ^a	0.432 ^a	0.614 ^a
SD	0.009		0.012	0.007	0.010	
control	Mean	0.089 ^b	0.204 ^b	0.254 ^b	0.396 ^b	
	SD	0.003	0.013	0.009	0.005	
Sig.			**	**	**	**
P-value			0.000	0.000	0.000	0.000

Table (2): The mean, standard deviation (SD) values of bone density for treatments under time for diabetic animal.

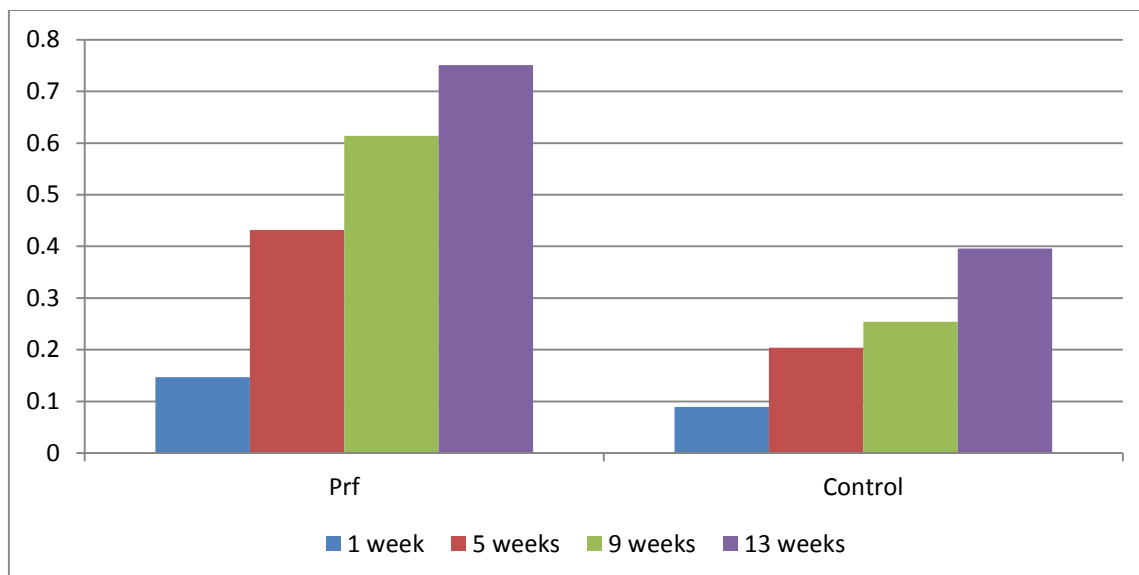


Fig 2. Bar chart for bone density for diabetic animal under treatments effect.

Effect of the general health of the animals:

A- platelet rich fibrin (prf):

1- 1 week : There was no statistically significant difference between Healthy animals (0.173±0.003) and Diabetic animals (0.147±0.004)

2- 5 weeks: There was a statistically significant difference between Healthy animals (0.566±0.012) and Diabetic animals (0.432±0.012) groups.

3- 9 weeks: There was a statistically significant difference between Healthy animals (0.830 ±0.003)and Diabetic animals (0.614±0.007)

4- 13 weeks: There was a statistically significant difference between Healthy animals (1.087 ±0.037)and Diabetic animals (0.751±0.010)

Bone Density									
platelet rich fibrin (prf)									
Variable	1 week		5 weeks		9 weeks		13 weeks		Mean
	Mean	SD	Mean	SD	Mean	SD	Mean	SD	
Healthy animal	0.173 g	0.003	0.566 e	0.008	0.830 b	0.003	1.087 a	0.037	0.664 a
Diabetic animal	0.147 g	0.009	0.432 f	0.012	0.614 d c	0.007	0.751 c	0.010	0.486 b
Sig.	*								**
P-value	0.010								0.005

Table (3): The mean, standard deviation (SD) values for bone density under time for healthy and diabetic animal for platelet rich fibrin (prf)

B- Control:

1- 1 week : There was no statistically significant difference between Healthy animals (0.111±0.001) and Diabetic animals (0.089±0.003)

2- 5 weeks: There was a statistically significant difference between the Healthy animals (0.279±0.006) and Diabetic animals (0.204±0.013) groups.

3- 9 weeks: There was a statistically significant difference between Healthy animals (0.372 ±0.009)and Diabetic animals (0.254±0.008)

4- 13 weeks: There was a statistically significant difference between Healthy animals (0.433 ±0.015)and Diabetic animals (0.395±0.005)

Bone Density									
Control									
Variable	1 week		5 weeks		9 weeks		13 weeks		Mean
	Mean	SD	Mean	SD	Mean	SD	Mean	SD	
Healthy animal	0.111 g	0.001	0.279 d	0.006	0.372 c	0.009	0.433 a	0.015	0.299 a
Diabetic animal	0.089 h	0.003	0.204 f	0.013	0.254 e	0.008	0.395 b	0.005	0.236 b
Sig.	**								**
P-value	0.000								0.000

Table (4): The mean, standard deviation (SD) values for bone density under time for healthy and diabetic animal for control.

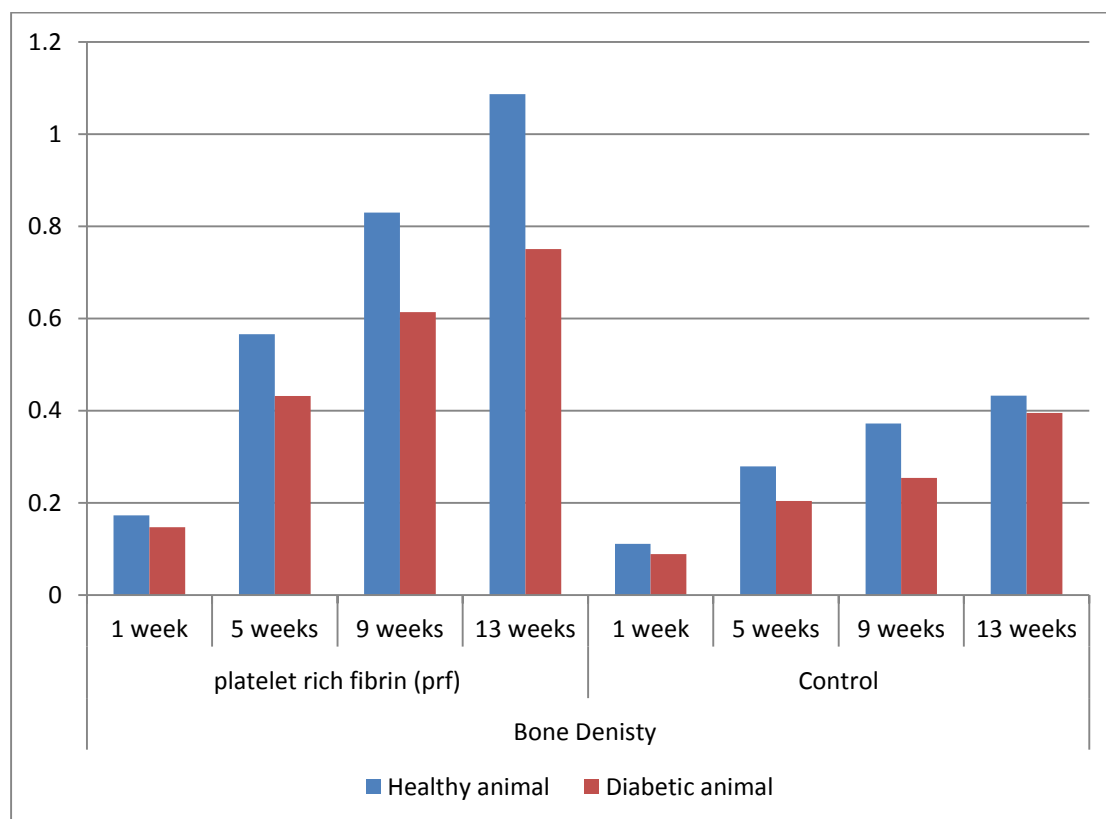


Fig 3. Bar chart for bone density for healthy and diabetic animal comparison.

Histologic results:

Histological examination of sections stained with H&E (at 1 week) showed that, the presence of blood clot infiltrated with inflammatory cell mainly PNL and macrophages, well organized granulation tissues which characterized by multiple diluted blood capillaries regarding highly angiogenic activity. There was recruitment of osteoblast with early formation of islands of thin bone trabeculae. Histological examination of section stained with H&E(at 5 weeks) revealed that, the presence of well organized granulation tissues which characterized by multiple diluted blood capillaries. There was osteoblast with early formation of islands of thick bone trabeculae with variable bone marrow spaces., Histological examination of section stained with H&E(at 9 weeks) revealed that, the presence of multiple blood capillaries formation of islands of very thick bone trabeculae with variable bone marrow spaces. woven bone formation ,at some areas there was the same dramatic appearance of trabeculation with spread of bony trabeculae from the center .most ares of the slides reflects formation of lamellar , at this stage woen bone (non- lamellar bone) still present with low grades however the most dominant features was replacement of no-lamellar(woven bon) by lamellar one . Histological examination of section stained with H&E(at 13 weeks) revealed that, the presence of multiple blood capillaries however replacement of no-lamellar(woven bon) by lamellar one appears clearlyly at this section ,haversian system, circum frenal lamellae also ppears .

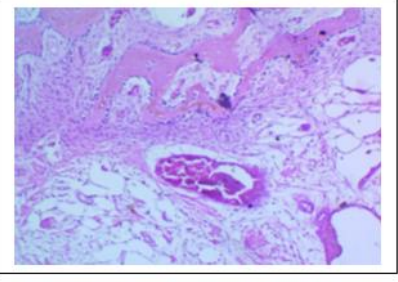
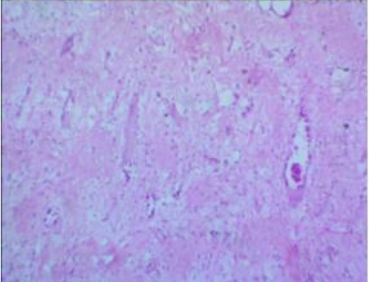
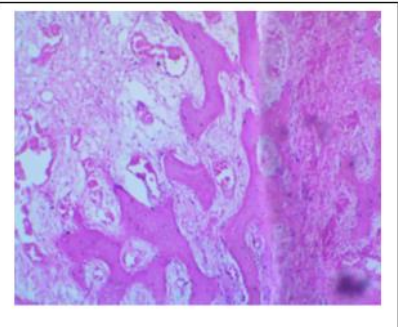
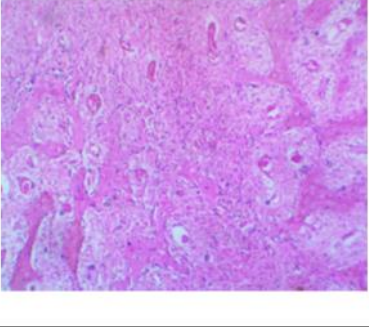
One week	Healthy	Diabetic
Control		
PRF		

Table (5) contains photo histograms at 1 week sacrifice period in healthy and diabetic dogs

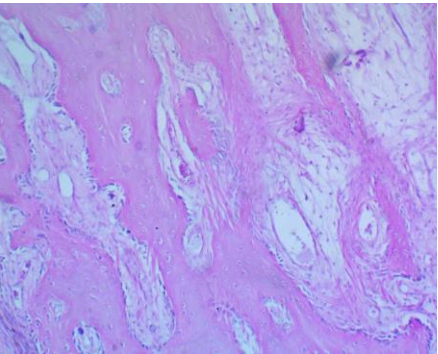
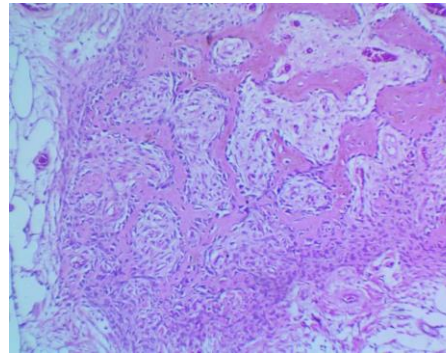
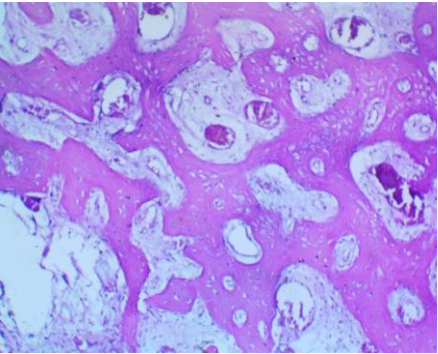
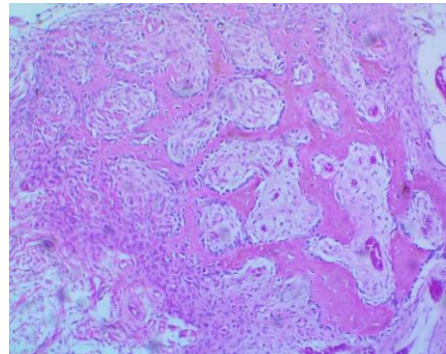
	Healthy	Diabetic
Control		
PRF		

Table (6) contains phot histograms at 5 weeks sacrifice period in healthy and diabetic dogs

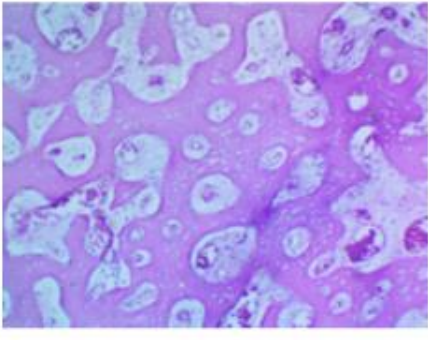
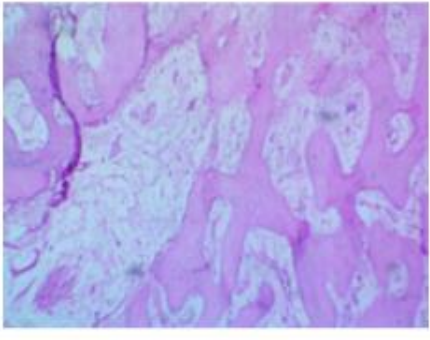
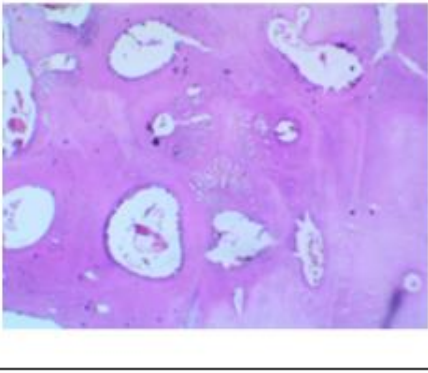
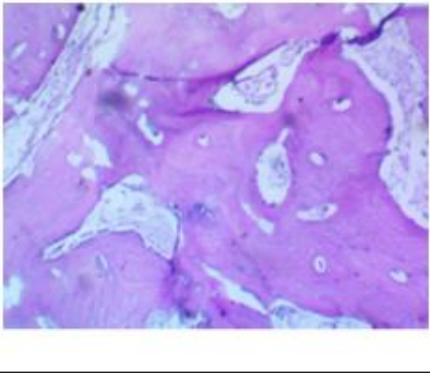
<i>Nine weeks</i>	Healthy	Diabetic
Control		
PRF		

Table (7)) contains phot histograms at 9 weeks sacrifice period in healthy and diabetic dogs

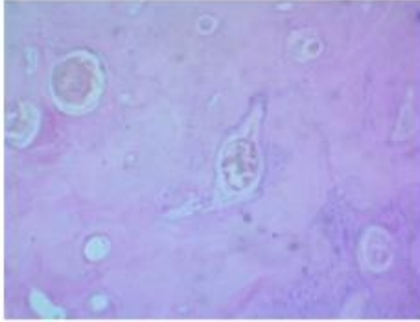
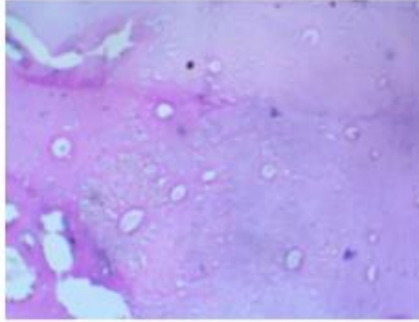
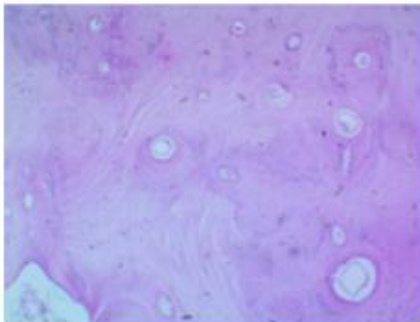
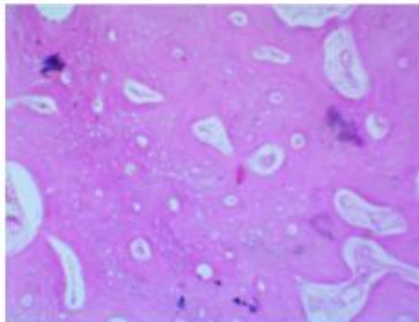
<i>Thirteen weeks</i>	Healthy	Diabetic
Control		
PRF		

Table (8)) contains phot histograms at 13 weeks sacrifice period in healthy and diabetic dogs

IV. Discussion

The bone regeneration following periapical surgery can be facilitated by placing a bone graft into the periapical defect. Different types of bone grafts are available for dental surgical procedures. These include autografts, allografts, xenografts, and alloplasts. The ideal bone replacement material should be clinically and biologically inert, noncarcinogenic, easily maneuverable to suit the osseous defect, and should be dimensionally stable. It should serve as a scaffold for bone formation and slowly resorb to permit replacement by new bone⁽⁹⁾.

The present study evaluated the effect of PRF on bone healing in healthy and diabetic dogs.

Selection of the dogs as an animal model in the present study is based on the anatomical, physiological, and bio-mechanical similarity to human beings with better ability to perform root canal treatment followed by periradicular surgery which will be difficult in rodents^{10,11}. sixteen dogs were used with eight dogs per group depending on a power study analysis to provide a power of 95% confidence with a significance level (alpha) of 0.05 (two-tailed) considering the use of the smallest number of dogs, which does not disturb the results. Randomization of the dogs was done using a randomizer software to avoid bias. efforts were made to minimize the number of times the dogs were exposed to general anesthesia as reported, exposure to general anesthesia may affect the general health of the dogs, so root canal treatment and periradicular surgery were made in a single appointment⁽¹²⁾.

the rectangular flap was performed opposite to the fourth premolar on each side with two vertical releasing incisions placed mesial to the interdental papilla between the third and fourth premolars in the mesial side and distal to the interdental papilla between the fourth premolar and 1st molar tooth to allow better exposure to the surgical field.

The metallic template was used in this study for the purpose of standardization of the bone cavity, in which different sizes may heal differently. The metallic template was replaced with a new one when the old one was affected by cutting. Thus, a 7 mm × 7 mm × 7 mm bone defect was created followed by resection of the apical 3mm of the root by fissure surgical bur with no bevel. Retrograde cavity preparation using an ultrasonic tip was done followed by retrograde filling of the root with MTA material as it exhibits the highest apical healing (90.4%) compared with other root-end filling materials¹³. MTA also prevents leakage than other root-end filling materials¹⁴

Measuring the bone mineral density using the DEXA method because it is a simple method, suitable for all ages, not dependent on other measurements, and the associated x-ray dose is very low⁽¹⁵⁾ in addition Excellent accuracy and precision of DXA⁽¹⁶⁾. Histological examination was done to explain the healing power of different materials at different times as it is directly related to the newly formed bone.

Regarding the effect of time on bone mineral content, BMD, and woven bone formation, 13 weeks period showed the highest result in relation to other time periods, and this result is logical in that bone density will be increased gradually as the time for healing increases. A potential explanation for the extended time required for apical lesions to heal may be the persistence of an activated state of macrophages and lymphocytes within the lesion. Activated macrophages and activated lymphocytes are the primary sources of IL-1 β and TNF β cytokines, which represent the main osteoclast-stimulating activity in the apical lesion¹⁷ Such an activated state may outlive its biological purpose as an essential element of the host's defensive response in the area of the lesion. As long as such activation persists and these cytokines are produced, the osteoclastic potential of the lesion persists, keeping the vast surrounding osteogenic potential at bay. When the osteoclastic activity subsides, the lesion finally heals^{18, 19} With regard to the effect of material on both healthy and diabetic dogs, There was a significant difference between PRF and control This result may be due to the effect of PRF which gradually increases the osseous healing at every follow-up period²⁰. The results of this study were in agreement with other studies and showed that PRF acts as an appropriate scaffold with a strong fibrin structure that optimally supports the transplanted mesenchymal cells and allows for the gradual release of growth factors over a long period ranging from 7 to 28 days^{(21),(22),23,24,25)}. Also, it was found that PRF has a role in phosphorylated extracellular signal-regulated protein kinase expression and suppresses osteoclastogenesis by promoting the secretion of osteoprotegerin in osteoblasts cultures⁽²⁶⁾.

Regarding the effect of health status, the highest bone mineral content, bone mineral density, and newly formed woven bone was found with the healthy group as diabetes may affect wound healing by locally increasing Pro-inflammatory mediators including TNF- α , IL-1 β , IL-6, and IL-18 which thought to contribute to diabetic complications^(27,28). Increased levels of TNF may decrease the ability of diabetics to downregulate other inflammatory genes and increase apoptosis, which has been shown to reduce bone coupling in diabetic animals⁽²⁹⁾

Uncontrolled diabetes increases and prolongs inflammation, which may lead to enhanced osteoclastogenesis. Hyperglycemia may affect bone through enhanced expression of pro-inflammatory cytokines such as TNF α , which reduces osteoblast differentiation, and osteoblast activity and increases osteoblast apoptosis^(30,31).

Diabetes decreases hemostasis, inflammation, and angiogenesis. Wounds in diabetic patients showed altered blood flow, impaired neutrophil anti-microbial activity, and a dysfunctional inflammatory state associated with abnormal chemokine expression. Also, it was found that the number of growth factors essential for wound healing, including FGF-2 and PDGF-B, have also been found to reduced in experimental diabetic wounds^(32,33,34, 35). Insulin binds to receptors on osteoblasts and stimulates anabolic effects⁽³⁶⁾. It is possible that the reduced insulin levels or reduced insulin signaling in osteoblasts negatively affects bone and contributes to reduced bone formation caused by diabetes⁽³⁷⁾.

V. Conclusion

Under the limitations of the present study, Platelet-rich fibrin is a promising biomaterial that accelerates bone regeneration after Peri radicular Surgery in Healthy and Diabetic Dogs

References

- 1 Naik B, Karunakar P, Jayadev M, Marshal VR. Role of Platelet rich fibrin in wound healing: A critical review. *Journal of conservative dentistry: JCD*. 2013 Jul;16(4):284.
- 2 Abramovitz I, Better H, Shacham A, Shlomi B, Metzger Z. Case selection for apical surgery: a retrospective evaluation of associated factors and rationale. *J Endod* 2002;28:527—30.
3. Albrektsson T, Johansson C Osteoinduction, osteoconduction and osseointegration. *Eur Spine J* 2001: S96-101.
- 4 Moseley KF. Type 2 diabetes and bone fractures. *Curr Opin Endocrinol Diabetes Obes*. 2012; 19:128–135.
- 5 Gonzalez Y, Herrera MT, Soldevila G, et al. High glucose concentrations induce TNF-alpha production through the down-regulation of CD33 in primary human monocytes. *BMC Immunol*. 2012; 13:19.
- 7 Rohilla A, Ali S. Alloxan induced diabetes: mechanisms and effects. *International journal of research in pharmaceutical and biomedical sciences*. 2012;3(2):819-23
- 8 Saluja H, Dehane V, Mahindra U. Platelet-Rich fibrin: A second generation platelet concentrate and a new friend of oral and maxillofacial surgeons. *Annals of maxillofacial surgery*. 2011;1(1):53.
- 9 Molvan O, Halse A, Grung B. Incomplete healing (scar tissue) after periapical surgery: Radiographic findings in 8-12 years after treatment. *J Endod*. 1996;22:264–8
- 10 - Liao HT, Marra KG, Rubin JP. Application of platelet-rich plasma and platelet-rich fibrin in fat grafting: basic science and literature review. *Tissue Engineering Part B: Reviews*. 2014; 20:267-76
- 11 - Black HE, Rosenblum IY, Capen CC. Chemically induced (Streptozotocin-Alloxan) diabetes mellitus in the dog: Biochemical and ultrastructural studies. *The American Journal of Pathology*. 1980; 98:295.
- 12- Murashima Y, Yoshikawa G, Wadachi R, Sawada N, Suda H. Calcium sulfate as a bone substitute for various osseous defects in conjunction with apicectomy. *Int Endod J*. 2002; 35: 768– 74.
- 13 Von Arx T, Penarrocha M, Jensen S. Prognostic factors in apical surgery with root-end filling: a meta-analysis. *Journal of Endodontics*. 2010;36(6):957-73.
- 14 Eliyas S, Vere J, Ali Z, Harris I. Micro-surgical endodontics. *Br Dent J* 2014; 216(4):169-77.
- 15 - Heymsfield SB, Wang J, Heshka S, Kehayias JJ, Pierson RN. Dual-photon absorptiometry: comparison of bone mineral and soft tissue mass measurements in vivo with established methods. *The American Journal of clinical nutrition*. 1989; 1:4:1283-9.
- 16 Mazess R, Chesnut CH, McClung M, Genant H. Enhanced precision with dual-energy X-ray absorptiometry. *Calcified tissue international*. 1992 Jul;51:14-7.
- 17 Wang CY, Stashenko P. Characterization of bone-resorbing activity in human periapical lesions. *Journal of endodontics*. 1993 Mar 1;19(3):107-11.
- 18 Metzger Z. Macrophages in periapical lesions. *Dental Traumatology*. 2000 Feb;16(1):1-8.
- 19 Metzger Z, Abramovitz I. Periapical lesions of endodontic origin. *Ingle's Endodontics*. 6th ed. Hamilton, Canada: BC Decker. 2008:494-519.
- 20- Kumar YR, Mohanty S, Verma M, Kaur RR, Bhatia P, Kumar VR, Chaudhary Z. Platelet-rich fibrin: the benefits. *British Journal of Oral and Maxillofacial Surgery*. 2016; 54:57-61.
- 21 - Dohan DM, Choukroun J, Diss A, Dohan SL, Dohan AJ, Mouhyi J, Gogly B. Platelet-rich fibrin (PRF): A second-generation platelet concentrate. Part III: leucocyte-activation: a new feature for platelet concentrates? *Oral Surg Oral Med Oral Pathol Oral Radiol Endod* 2006c; 101: e51-52.
- 22 - He L, Lin Y, Hu X, Zhang Y, Wu H. A comparative study of platelet-rich fibrin (PRF) and platelet-rich plasma (PRP) on the effect of proliferation and differentiation of rat osteoblast in vitro. *Oral Surg Oral Med Oral Pathol Oral Radiol Endod*. 2009;108:707-13.
- 23- Ehrenfest DM, Diss A, Odin G, Doglioli P, Hippolyte MP, Charrier JB. In vitro effects of Choukroun's PRF (platelet-rich fibrin) on human gingival fibroblasts, dermal pre-keratinocytes, preadipocytes, and maxillofacial osteoblasts in primary cultures. *Oral Surg Oral Med Oral Pathol Oral Radiol Endod* 2009; 108:341–52.

- ²⁴- Mazor Z, Horowitz RA, Del Corso M, Prasad HS, Rohrer MD, Dohan Ehrenfest DM. Sinus floor augmentation with simultaneous implant placement using Choukroun's platelet- rich fibrin as the sole grafting material: a radiologic and histologic study at 6 months. *Journal of Periodontology*. 2009; 80:2056-64.
- ²⁵- Tsai CH, Shen SY, Zhao JH, Chang YC. Platelet-rich fibrin modulates cell proliferation of human periodontally-related cells in vitro. *J Dent Sci* 2009; 4:130-35
- ²⁶- Chang IC, Tsai CH, Chang YC. Platelet-rich fibrin modulates the expression of extracellular signal-regulated protein kinase and osteoprotegerin in human osteoblasts. *J Biomed Mater Res A* 2010; 95:327-32.
- ²⁷ . Graves DT, Kayal RA. Diabetic complications and dysregulated innate immunity. *Front Biosci*. 2008; 13:1227–1239.
- ²⁸ Nikolajczyk BS, Jagannathan-Bogdan M, Shin H, Gyurko R. State of the union between metabolism and the immune system in type 2 diabetes. *Genes & Immunity*. 2011 Jun;12(4):239-50.
- ²⁹ Pacios S, Andriankaja O, Kang J, et al. Bacterial infection increases periodontal bone loss in diabetic rats through enhanced apoptosis. *Am J Pathol*. 2013; 183(6):1928–1935.
- ³⁰ Lechleitner M, Koch T, Herold M, Dzien A, Hoppichler F. Tumour necrosis factor-alpha plasma level in patients with type 1 diabetes mellitus and its association with glycaemic control and cardiovascular risk factors. *Journal of internal medicine*. 2000; 248(1):67–76.
- ³¹ Gonzalez Y, Herrera MT, Soldevila G, et al. High glucose concentrations induce TNF-alpha production through the down-regulation of CD33 in primary human monocytes. *BMC Immunol*. 2012; 13:19.
- ³² Beer HD, Longaker MT, Werner S. Reduced expression of PDGF and PDGF receptors during impaired wound healing. *J Invest Dermatol* 1997; 109:132–38.
- ³³- Werner S, Breeden M, Hubner G, Greenhalgh DG, Longaker MT. Induction of keratinocyte growth factor expression is reduced and delayed during wound healing in the genetically diabetic mouse. *J Invest Dermatol* 1994; 103:469–73.
- ³⁴ - Bitar MS, Labbad ZN. Transforming growth factor-beta and insulin-like growth Factor-I in relation to diabetes-induced impairment of wound healing. *J Surg Res* 1996; 61:113–19.
- ³⁵- Brown DL, Kane CD, Chernausek SD, Greenhalgh DG. Differential expression and localization of insulin-like growth factors I and II in cutaneous wounds of diabetic and nondiabetic mice. *Is J Pathol* 1997, 151:715–24?
- ³⁶ Thomas DM, Hards DK, Rogers SD, Ng KW, Best JD. Insulin receptor expression in bone. *J Bone Miner Res*. 1996; 11(9):1312–1320
- ³⁷ Thraill KM, Lumpkin CK Jr, Bunn RC, Kemp SF, Fowlkes JL. Is insulin an anabolic agent in bone? Dissecting the diabetic bone for clues. *American Journal of Physiology-Endocrinology and Metabolism*. 2005; 289(5): 735–745.