

Gender Determination Based On Mandibular Parameters Using Cone Beam Computed Tomography-A Forensic Based Retrospective Study

Dr.Sarawathi.K.Gopal.MDS.,

Head & Professor, Department of Oral Medicine & Radiology, Faculty of Dentistry,
Meenakshi Ammal Dental College & Hospital, Meenakshi Academy of Higher Education
Research Institute, Chennai – 600095

Dr.Harini.B.K.

Post graduate, Department of Oral Medicine & Radiology, Faculty of Dentistry, Meenakshi
Ammal Dental College & Hospital, Meenakshi Academy of Higher Education Research
Institute, Chennai – 600095.

Abstract:

Aim: To Assess Gender Identification Using Osteometric Mandibular Measurements Performed On Cone Beam Computed Tomography (Cbct) Images.

Materials And Methods: The Sample Consisted Of 60 Cbct Scans Aged Between 18- 45 Years. The Collected Cbct Images Were Analyzed By Two Examiners To Test The Reliability Of Measurements. Three Measurements Were Used For Sexual Prediction Analysis As Follows: Gonial Angle, Coronoid-Gonion Length (The Distance Between Gonion And The Highest Lateral Point On The Coronoid Process), Ramus Length.

Results: Males Had Statistically Significantly Higher Mean Ramus Length(Mean Values; M=5.53,F=4.96), Coronoid -Gonion Length(M=5.49,F=5.06) Than Females. While Females Had A Statistically Significant Higher Gonial Angle Than Males(Mean Values;M=126.38,F=131.37) With The Overall Classification For gender Determination Using Prediction Equation was 81.7%.

Conclusion: The Present Study Suggested That The Gender Of Mandible Could Be Assessed Using Metrical And Angular Measurements Which Is Considered As An Additional Tool For Gender Identification.

Keywords: Gender Dimorphism, Ramus Length, Gonial Angle, Coronoid Gonion Length, Mandible, Cone Beam Computed Tomography.

Date of Submission: 17-06-2023

Date of Acceptance: 27-06-2023

I. INTRODUCTION:

Gender determination using human remains is considered to be an important concern in forensic anthropology practice. Human pelvis bone is considered to be the most important bony standards that involve remarkable sexual dimorphism, with accuracy up to 95 % followed by cranium and long bones with approximately 92% accuracy (1). The skull bone is taken into consideration as the second highest-quality after the pelvic bone in gender determination due to its higher retention of morphological capabilities and its sturdiness to changing environmental conditions. Sexual dimorphism constitutes a group of morphological characteristics which differentiates males from females (2). The mandibular bone is very important as one of the hardest, most durable of cranial bones and has more form variations according to sex (3).

Currently, computerized or virtual methodologies become a developing trend in forensic anthropology. The introduction of Cone Beam Computed Tomography (CBCT) era in the clinical management of patients has proven valuable in volumetric analysis. Therefore, gender determination using CBCT images has more advantages than conventional osteometric approaches (4,5,6,7,8).

II. MATERIALS & METHOD:

The present study comprises of 60 CBCT records of mandibles(120 rami and angles bilaterally).30 males and 30 females aged between 18-45 years. All the participants were scanned with CBCT for various purposes using a Planmeca Promax 3D Mid Proface CBCT device. The CBCT measurements were measured using Radiant Dicom viewer software with the distance and angle measurement tools. CBCT images with the following cases

were excluded: acquired or developmental deformation, severe asymmetry, old or new mandibular fracture & images with artifacts.

IMAGE STANDARDISATION:

Three parameters such as Ramus length, Coronoid gonion length & gonion angle were measured, the images were sliced at 10 mm size thickness. All the CBCT images were standardised prior to measurements such as, the images were tilted in such a way that the lower border of mandible is made parallel to the horizontal plane as shown in figure 1.a.

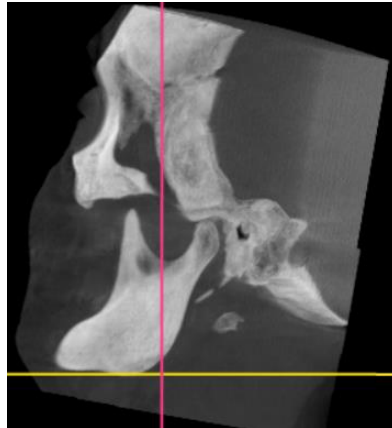


Figure 1.a.

The intersection point between horizontal and vertical line is placed in the deepest portion of sigmoid notch as shown in figure 1.b.

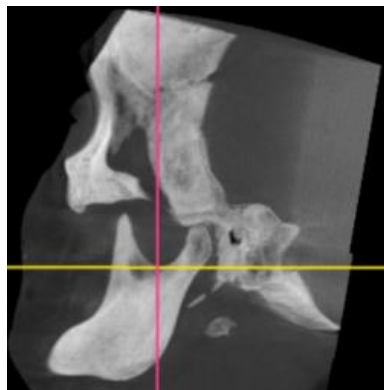


Figure 1.b.

The intersecting line has been cross checked in coronal and axial view. In coronal view, the intersecting line splits mandible body into two equal halves as shown in figure 1.c. In axial view, the intersecting line divides condyle head into two equal halves in figure 1.d.

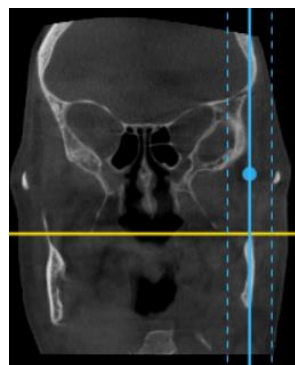


Figure 1.c.

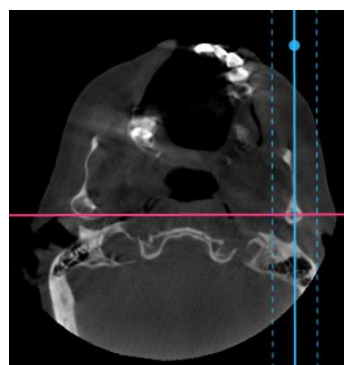


Figure 1.d.

METHODOLOGY:

Step 1: For Ramus length and coronoid-gonion length, the measurements were taken from condyion and from the highest point in coronoid till the gonion as shown in figure 2.a & 2.b respectively.

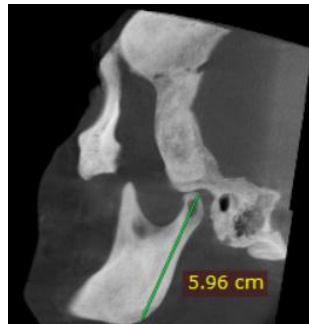

Figure 2.a

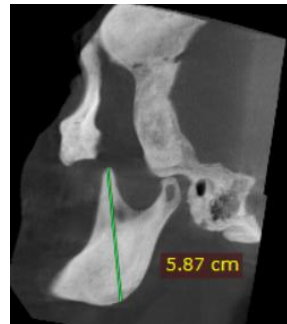

Figure 2.b.

Step 2: For measuring gonion angle, a tangential line was drawn from lower border of mandible and to the lateral border of head of condyle as shown in figure 2.c.

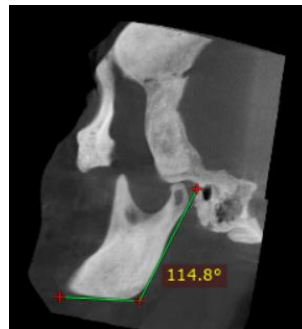


Figure 2.c.

Step 3 :

Gender determination formula = D = -2.822R (Ramus length) - 1.357CGL (Coronoid Gonion Length) - 0.066GA (Gonial Angle)+ 30.509

The data was compiled and analyzed using SPSS software and the results were tabulated.

III. RESULTS:

This study evaluated three parameters of mandible in CBCT images of male and female patients for gender determination. In analysing all the parameters between the right and left side, only minor differences were observed which shows either side measurement can be used to differentiate between genders.

A discriminant analysis was conducted to predict gender (Male or Female). The significant predictors for gender were: Ramus length, coronoid gonion length and gonial angle. The discriminate function was:

D = -2.822R (Ramus length) - 1.357CGL (Coronoid Gonion Length) - 0.066GA (Gonial Angle) + 30.509

The discriminate functions at group centroids (Group means) were 0.685 for males and -0.685 for females.

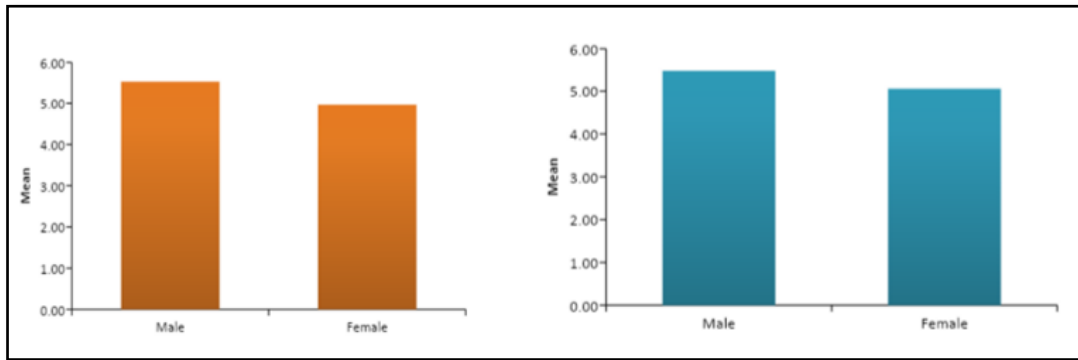


Figure 3.a. shows graphical representation of ramus length and coronoid-gonion length between males and females respectively.

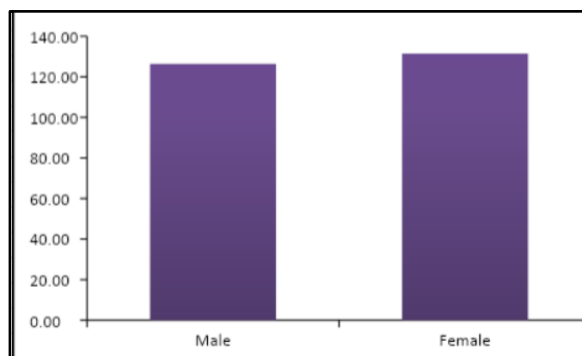


Figure 3.b. shows graphical representation of gonial angle between males and females.

PARAMETER	GENDER	MEAN(mm)	SD	p- VALUE
RAMUS LENGTH	MALE	5.53	0.46	.0005**
	FEMALE	4.96	0.41	
CORONOID-GONION LENGTH	MALE	5.49	0.47	.0002**
	FEMALE	5.06	0.37	
GONIAL ANGLE	MALE	126.38	6.84	.008**
	FEMALE	131.37	7.32	

P-value <0.01 - **highly significant

Table 1. shows the mean values of all the three parameters with p-values.

IV. DISCUSSION:

Forensic dentistry has long used specific methods for assessing gender dimorphism and identifying missing people through skeletal remains. Such estimations can be made using anthropometric measurements in the jaw. The mandible is one of the strongest and most durable skull bone in humans with a high degree of sexual dimorphic characters. This study describes an osteometric approach using mandibular measurements to determine gender.

The cranio-dentofacial size of males is significantly larger than that of females. Sexual differentiation of the cranio-dentofacial width dimensions are more pronounced in the zygoma, the mandibular angle and the condyles.

The Classification results revealed that 80% of the males were correctly classified while 83.3% of the females were correctly classified according to the prediction equation. Hence, the overall correct classification was 81.7%. A discriminant analysis was carried out for gender determination (Male or Female). The significant

predictors for gender were: coronoid gonion length, mandibular ramus length and Gonial angle. The discriminate functions at group centroids (Group means) were 0.685 for males and -0.685 for females.

The current study focuses on gender determination based on three mandibular parameters such as ramus length, coronoid gonion length and gonial angle with the help of CBCT. In this study all the three parameters were found to be statistically significant between both the genders which were in accordance with the study done by Okkesim et al.(2020) who conducted a retrospective study⁽⁹⁾ in which they reconstructed CBCT images of the mandible for coronoid height, condylar height, ramus height, and maximum and minimum ramus breadth determining gender, among which Ramus length had a statistically significant difference between males and females. It is also in accordance with the study conducted by Saraswathi Gopal, et.al(2018)⁽¹⁰⁾. The present study disagrees with study conducted by Ayoub et al.(2008)⁽¹¹⁾ showed that Gonial angle did not have significant statistical differences between males and females since the study was done in lateral cephalogram.

There is no statistical difference between the right and left side of the mandible hence either of the sides can be utilized for gender prediction by assessing minimal parameters.

V. CONCLUSION:

The present study suggested that the sex of mandible could be assessed using linear and angular measurements which is considered as an additional tool for gender identification.

Thus, the formula developed in this study can be used for sexual prediction in forensic dentistry. Further studies with a larger population can be performed for more accurate results. Immense interactions with the law enforcers, the judiciary and the forensic fraternity at various forums, such as hands-on workshops and conferences and continual education programs, have increased the subject's understanding, awareness and importance. There is considerable scope for further research investigating the role of CBCT in various dental and forensic applications, making it an invaluable asset with many feathers in its cap.

REFERENCES:

- [1]. Abofakher M. G. A, Owayda A, Al-assaf M, Hamadah O, Abdul-hak M, Nofal H. Mandibular Sexual Dimorphism Analysis in CBCT Scans in a Syrian Sample. *Cumhuriyet Dent J* 2020;23:2:124-128.
- [2]. Iman Dakhli, Omniya Abu El-Dahab. Sexual differentiation based on mandibular parameters utilizing cone beam computed tomography of a sample of Egyptian population. *IAIM*, 2020; 7(5): 24-31
- [3]. Ramakrishnan K, Sharma S, Sreeja C, Pratima DB, Aesha I, Vijayabanu B. Sex determination in forensic odontology: A review. *J Pharm Bioallied Sci* 2015;7:S398-S402.
- [4]. Saini V, Srivastava R, Shamal SN, Pandey AK, Tripathi SK. Sex determination using mandibular ramus flexure: A preliminary study on Indian population. *J. Forensic Leg.Med.*, 2011; 18: 208-212. 3.
- [5]. Gamba TDO, Corrêa Alves M, HaiterNeto F. Analysis of sexual dimorphism by locating the mandibular canal in images of cone-beam computed tomography. *J. Forensic Radio and Img.*, 2014; 2: 72-76. 4.
- [6]. Dong H, Deng M, Wang W, Zhang J and Mu J. Zhu G. Sexual dimorphism of the mandible in a contemporary Chinese Han population. *Forensic Sci Int.*, 2015; 255: 9-15.
- [7]. Angel JS, Mincer HH, Chaudhry J, Scarbecz M. (2011). Cone-beam computed tomography for analyzing variations in inferior alveolar canal location in adults in relation to age and sex. *J Forensic Sci.*, 2011; 56(1): 216-9. 7.
- [8]. Asifa KM, Nambiara P, Manib SA, Ibrahim NB, Khanb IM, Sukumaran P. Dental age estimation employing CBCT scans enhanced with Mimics software: Comparison of two different approaches using pulp/tooth volumetric analysis. *Journal of Forensic and Legal Medicine*, 2018; 54: 53-61.
- [9]. Okkesim A, Erhamza TS. Assessment of mandibular ramus for sex determination: Retrospective study. *Journal of Oral Biology and Craniofacial Research*. 2020 Oct 1;10(4):569-72
- [10]. Gopal SK. "‘Measure It Right’ - Mandible in Forensics as an Aid in Gender Determination: A Retrospective 3D Cone Beam Computed Tomographic Study." *International Journal of Current Advanced Research*. 2018;07(8):15143–15148.
- [11]. Ayoub F, Rizk A, Yehya M, Cassia A, Chartouni S, Atiyeh F, Majzoub Z. Sexual dimorphism of mandibular angle in a Lebanese sample. *Journal of forensic and legal medicine*. 2009 Apr 1;16(3):121-4.