

Cheilitis Granulomatosa Induced By Apical Periodontics: A Case Report

Min Zhao

*(Department of Stomatology, Shandong Provincial Hospital Affiliated to Shandong First Medical University,
Jinan 250021, China)*

Abstract

Background: Cheilitis granulomatosa (CG) is a chronic swelling of the lip due to granulomatous inflammation. The precise etiology of GG is unknown. Genetics, allergies (food, dental materials), microbiological agents, or immunology were suggested as potential causative agents. And it is important to identify the pathogen to improve treatment specificity.

Case presentation: This case report describes a rare case of the patient with swelling of lower lip for cheilitis granulomatosa induced by apical periodontics. With the treatment of the dental infection, the swelling of the lower lip was alleviated soon and without recurrence of swelling in 1-year follow up. And the diagnosis, causes and treatment of cheilitis granulomatosa were discussed.

Conclusions: In some cases of CG patients, the granulomatous inflammation of lips may be associated with dental infection especially apical periodontics. To successfully identify the pathogen and treat this disease entity individually, it is important to identify and treat the associated dental infection for CG patients as well. The treatment of dental infection for CG patients might not only alleviate the symptoms sooner but also reduce the dosage and duration of steroid treatment. And moreover, to reduce the possibility of recurrence.

Keywords: Swelling of the Lip; Cheilitis Granulomatosa; Apical Periodontics; Case Report

Date of Submission: 21-05-2023

Date of Acceptance: 01-06-2023

I. Background

Cheilitis granulomatosa (CG) is characterized by chronic swelling of one or both the lips due to granulomatous inflammation. Typically, CG presents as labial swelling that persist or recur. It is a rare inflammatory disorder first described by Miescher in 1945 [1]. It is a monosymptomatic form or an incomplete variant of Melkersson-Rosenthal syndrome: a triad of recurrent orofacial edema, recurrent facial nerve palsy and

fissuring of the tongue. CG is also considered a subset of an uncommon disease orofacial granulomatosis, which was introduced by Wiesenfeld in 1985 [2].

The etiology of CG continues to remain a mystery. Reports suggest that a wide range of causes including genetics, allergic reactions, microbiological agents, autoimmune mechanism, as an association with manifestation of systemic diseases [1-2]. The diagnosis of CG is made by the clinical presentation of recurring labial swellings that histologically consist of non-caseating granulomas [1-2]. Local and systemic conditions characterized by granulomatous inflammation must be excluded by appropriate clinical and laboratory investigations.

This case report describes a rare case that the 61-year-old male patient with swelling of lower lip for cheilitis granulomatosa induced by apical periodontics. With the treatment of the dental infection, the swelling of the lower lip was alleviated soon and without recurrence of swelling in 1-year follow up. And the differential diagnosis, causes and treatment of cheilitis granulomatosa were discussed.

II. Case Presentation

A 61-year-old male patient presented with persistent, painful lower lip swelling for about 10 months. Upon clinical examination the lower lip and perioral area showed blush and swelling. Figure 1 showed the manifestations of the lower lip. Neither facial nerve palsy nor fissuring of the tongue nor lymph node involvement was present. No such lesions were seen intraorally. The left mandibular second molar (tooth #37) were painful for several years. Figure 4 showed the manifestations of the tooth #37. Periapical film of tooth #37 showed apparent periapical radiolucency suggestive of apical periodontitis of the left mandibular second molar (tooth #37). Figure 5 showed apparent periapical radiolucency suggestive of apical periodontitis of the tooth #37. The patient had no history of systemic diseases and denied any food or drug allergy.

Laboratory examination revealed complete blood count (CBC), liver and kidney function, blood lipid and blood glucose were normal. In other investigations, chest radiograph showed no abnormalities, and a Mantoux test was non-reactive. Evaluation for food allergies was normal. HIV testing were negative. The fungal smear of the oral mucosa tested negative.

Biopsy of the lower lip on Hematoxylin-Eosin staining section demonstrated granulomatous inflammation. Figure 6 showed the Histological manifestations of granulomatous inflammation.

III. Diagnosis

The diagnosis of cheilitis granulomatosa was made according to the clinical manifestation and histopathological demonstration.

IV. Treatment

First, we advised the patient to immediately treat the tooth #37 with root canal therapy. And 14 days later, the lower lip swelling and blush apparently alleviated. Figure 2 showed the manifestations of the lower lip 14 days later (after the immediate treatment of the tooth #37 with root canal therapy for 14 days). The patient thought that although the swelling was relieved obviously and the lower lip was nearly normal, his lower lip was a little bit more swelling than normal.

Then we administrated combined triamcinolone acetonide 40mg and 1ml 2% Lidocaine for multi-point intralesional injection of the lower lip for once. And 10 days later, it showed a complete resolution of lower lip swelling. Figure 3 showed the manifestations of the lower lip after multi-point intralesional injection of the combined triamcinolone acetonide 40mg and 1ml 2% Lidocaine for 10 days.

V. Follow-up and outcomes

The patient was under regular follow-up every month. In his 1-year follow up, we reported no recurrence of swelling of lower lip.

VI. Discussion

The typical presentation of CG is a nontender, recurrent labial swelling that eventually becomes persistent. This swelling may affect one or both lips and initially soft. But after recurrent attacks and following fibrosis with time, the swelling becomes indurated and firmer. And then the labial swelling permanent results in significant cosmetic concern for CG patients [1-3].

CG is an increasingly recognized entity. However, its exact etiology remains unclear. In addition to the causes of allergies (food, dental materials), microbiological agents, in fact that CG may be the manifestation of a systemic condition such as Crohn's disease, sarcoidosis, tuberculosis, leprosy, systemic fungal infections, more rarely, Wegener's granulomatosis [2-4].

Spontaneous remission of CG is rare. Traditionally, the first-line treatment is to prescribe systemic corticosteroids. Corticosteroids have been shown to be effective in reducing facial swelling and preventing recurrences and are considered the mainstay of therapy [1-3].

The lower lip swelling of the CG patient induced by induced by apical periodontics achieved rapidly alleviated due to immediately and effectively removed causes responsible for CG. The 10 months lower lip swelling and blush apparently alleviated after the treatment of apical periodontics in 14 days. And then we administrated combined triamcinolone acetonide 40mg and 1ml 2% Lidocaine for multi-point intralesional injection of the lower lip only for once, it showed a complete resolution of lower lip swelling 10 days later and

without recurrence of swelling. There no doubt that it is important for clinicians to identify the causes responsible for CG patients individually and select clinically rational treatment protocol. It might not only alleviate the symptoms sooner but also reduce the dosage and duration of steroid treatment.

VII. Conclusions

In some cases of CG patients, the granulomatous inflammation of lips may be associated with dental infection especially apical periodontics. To successfully identify the pathogen and treat this disease entity individually, it is important to identify and treat the associated dental infection for CG patients as well. The treatment of dental infection for CG patients might not only alleviate the symptoms sooner but also reduce the dosage and duration of steroid treatment. And moreover, to reduce the possibility of recurrence.

VIII. List of abbreviations

CG: Cheilitis Granulomatosa

IX. Declarations

1. Ethics approval and consent to participate

Not applicable

2. Consent for publication

Written informed consent was obtained from the patient for publication of this case report and any accompanying images. A copy of the written consent is available for review by the Editor of this journal.

3. Availability of data and materials

The datasets used and/or analyzed during the current study available from the corresponding author on reasonable request.

4. Competing interests

The author has declared that no competing interest exists.

5. Funding

No funding was received in association with this article.

6. Authors' contributions

Min Zhao performed the physical examination, oral cavity examination, the treatment and follow-up visits of the patient with granulomatosa cheilitis. Min Zhao was the contributor in the biopsy of the lower lip and writing the manuscript.

7. Acknowledgements

The author would like to thank Dr. Cheng Hongxia for his contribution in histological examination.

References

- [1]. Vibhute NA, Vibhute AH, Daule NR. Cheilitis granulomatosa: a case report with review of literature. *Indian J Dermatol.* 2013 May;58(3):242. doi: 10.4103/0019-5154.110858. PMID: 23723497; PMCID: PMC3667309.
- [2]. Rana AP. Orofacial granulomatosis: A case report with review of literature. *J Indian Soc Periodontol.* 2012 Jul;16(3):469-74. doi: 10.4103/0972-124X.100934. PMID: 23162350; PMCID: PMC3498725.
- [3]. Critchlow WA, Chang D. Cheilitis granulomatosa: a review. *Head Neck Pathol.* 2014;8(2):209-213. doi:10.1007/s12105-013-0488-2.
- [4]. Sasaki R, Suzuki K, Hayashi T, Inasaka H, Matsunaga K. Improvement of Cheilitis granulomatosa after Dental Treatment. *Case Rep Dermatol.* 2011 May;3(2):151-4. doi: 10.1159/000330731. Epub 2011 Aug 9. PMID: 21941479; PMCID: PMC3177833.

Figure legends

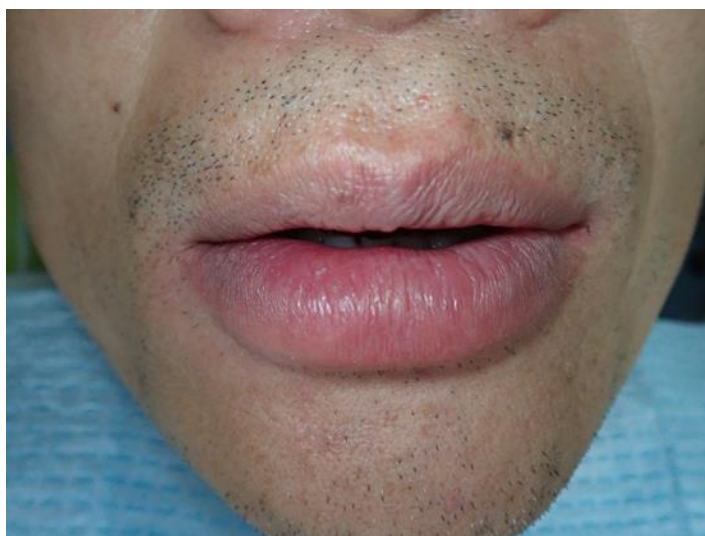

Figure1 showed the manifestations of the lower lip

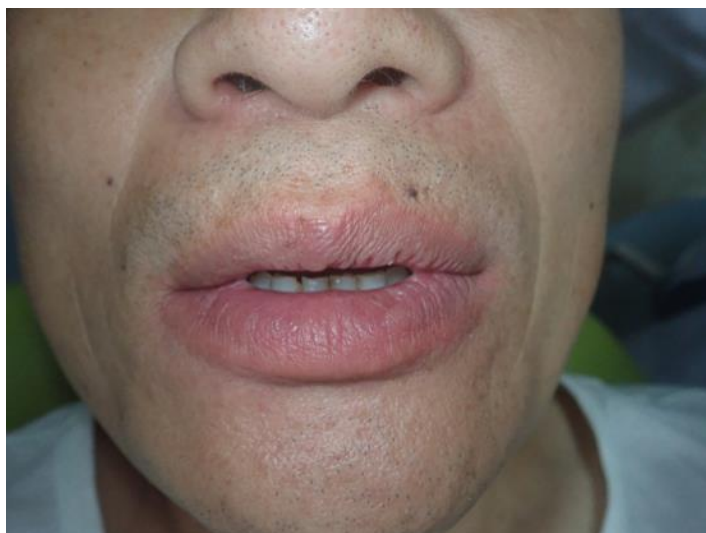

Figure 2 showed the manifestations of the lower lip 14 days later (after the immediate treatment of the tooth #37 with root canal therapy for 14 days)

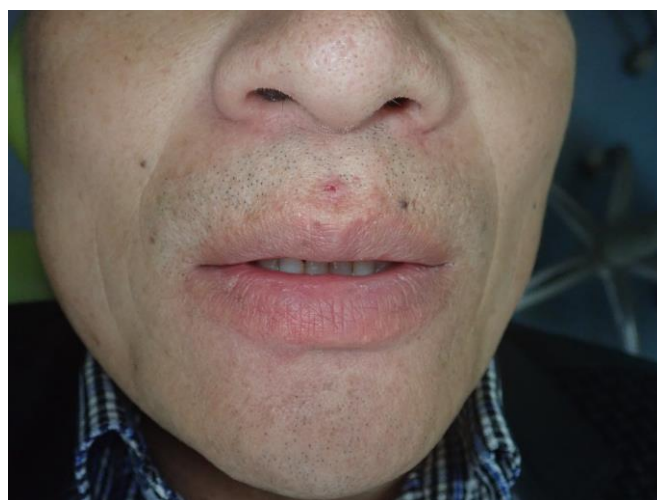

Figure 3 showed the manifestations of the lower lip after multi-point intralesional injection of the combined triamcinolone acetonide 40mg and 1ml 2% Lidocaine for 10 days

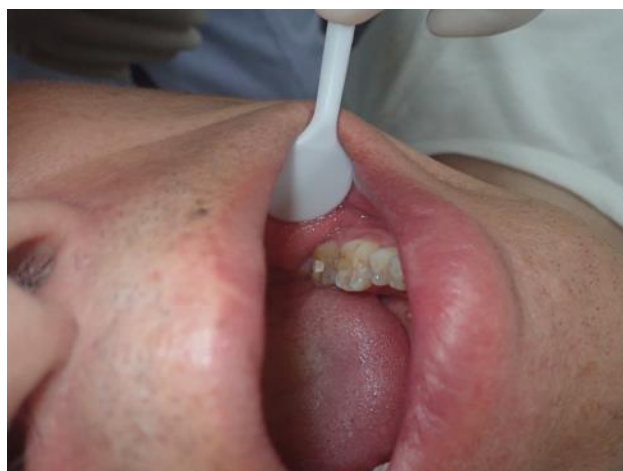

Figure 4 showed the manifestations of the tooth #37

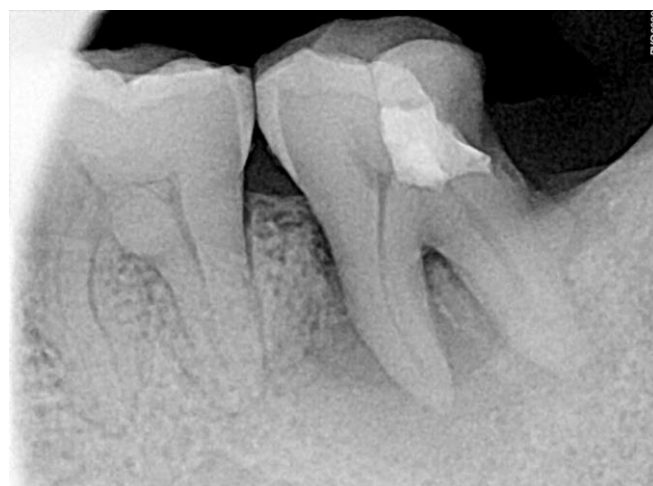

Figure 5 showed apparent periapical radiolucency suggestive of apical periodontitis of the tooth #37

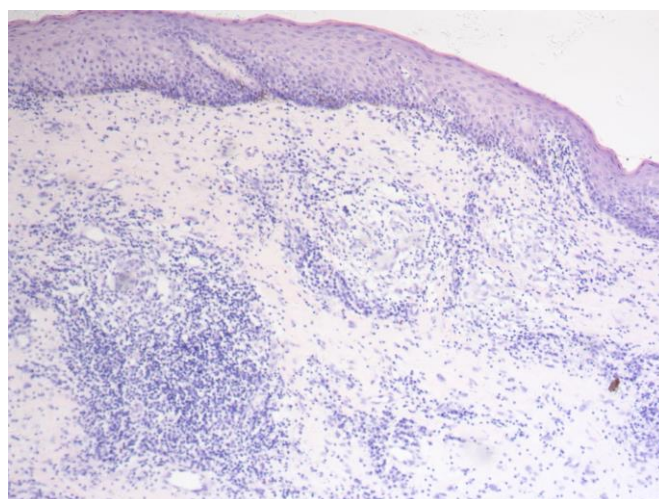


Figure 6 showed the Histological manifestations of granulomatous inflammation