

Tracheoesophageal Fistula In Two Adolescents: Delayed Diagnosis Case Reports And Literature Review

Ornela Nuredini MD, Alma Teferici MD, Anxhela Karati MD,
Eni Allmuca MD, Ilir Peposhi MD.PhD
University Hospital "Shefqet Ndroqi" Tirana Albania

Date of Submission: 28-04-2023

Date of Acceptance: 09-05-2023

I. Introduction

Congenital tracheoesophageal fistula (TEF) results from the failure of lateral septation on the digestive and respiratory tracts during the embryonic stage of development. TEF is usually diagnosed during infancy, because >98% of patients with TEF are associated with atresia of the esophagus which may have potential life-threatening complications. The isolated fistula without esophageal atresia, termed as H-type, accounts for approximately 4% of tracheoesophageal malformations. Early diagnosis of H-type TEF can be difficult because of nonspecific symptoms. Recurrent respiratory tract infections and chronic cough with unexplained etiology should alert physicians for this diagnosis.

Case 1

A 17-year-old female patient was referred with recurrent pulmonary infections, chronic cough, respiratory distress following nutrition and bibasal bronchoectasis. On physical examination, she had bilateral crackles and rhonchi in the lower zones of her chest. Chest X-ray revealed bilateral bronchial infiltration. Computed tomography (CT) scan of the chest demonstrated bilateral bronchial infiltrations at the basal zones and bilateral bronchiectasis. The flexible bronchoscopy confirmed the diagnose of TEF. (Figure 1).

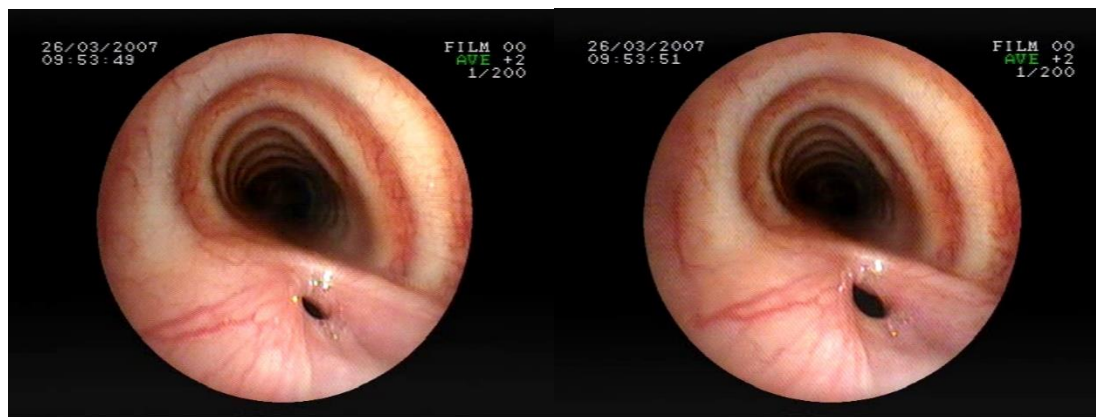


Fig .1 Tracheoesophageal fistula 17-year-old female

Case 2

A 15 -year-old female patient was referred with chronic cough and recurrent bouts of pneumonia. On physical examination, she had crackles and rhonchi at the lower zone of the right lung. Chest X-ray showed consolidation in the same location. A CT scan of the chest demonstrated a fistula at the level of the first and second thoracic vertebrae. Bronchoscopy confirmed the fistula measuring 2 cm long located proximal to the carina (Fig .2). In both cases, immunoglobulin levels, peripheral blood lymphocyte subsets, and sweat tests were normal. Tuberculosis tests were negative and sputum culture was sterile. Pulmonary function test and echocardiography were normal. In both cases, the fistulas were determined via guidewire exploration in bronchoscopy and repaired successfully by surgery.

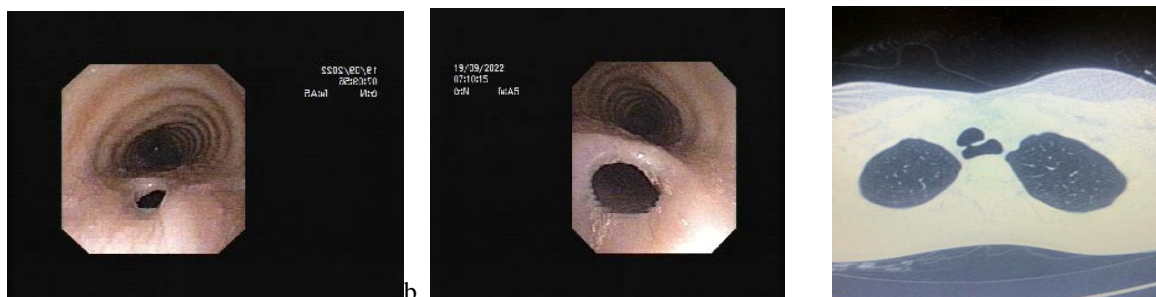

Fig .2 Tracheoesophageal fistula 15-year-old female

II. Discussion

TEF is a common congenital anomaly of the respiratory tract, with an incidence of approximately 1 in 3000 e 4500 live births. It is associated with vertebral, cardiovascular, and renal anomalies in addition to anal atresia and limb defects, known as VACTERL, which occur in 30e50% of cases.³ Isolated abnormalities of the trachea and esophagus such as tracheomalacia, and tracheal and esophageal stenosis are also present. TEF can disrupt the physiological development of the myenteric plexus of the esophagus in utero and cause peristalsis disorders and defective lower esophageal sphincter function.⁴ The most common localization of the congenital TEF is near the thoracic inlet, as observed in our cases. TEF was first described in 1929 by Negus⁵ as an incidental postmortem finding in an adult patient who died from lung carcinoma. TEF is rarely congenital in adult patients, instead it is usually secondary to malignancy, external and surgical trauma, nasogastric tube, and inflated cuffed endotracheal tube. TEF without atresia, termed as H-type, is the least severe form. If the defect is large, patients may present early in the newborn period with abdominal distension and respiratory symptoms after feeding due to aspiration through the fistula. The time of early diagnosis is between 26 days and 4 years.⁶ The delay in diagnosis has been reported from 15 years to 63 years in adults as patients can have asymptomatic intervals. The contractions of the muscle wall of the fistula or the oblique localization of the fistula tract between the trachea and esophagus may protect the airway from aspiration of food during swallowing. The small size and mucosal fold of the fistula that acts as a valve can lead to late presentation.^{1,2,7} A strong clinical suspicion is needed to achieve the diagnosis. Diagnosis of isolated TEF is challenging. Although not diagnostic, chest X-ray is helpful in suspected cases, which may demonstrate air in the lower esophagus. The fistulas can also be demonstrated with barium swallow tests, particularly in the prone position. Chest CT scan is recommended to assess lung parenchymal damage and identify the exact location of the fistula. Bronchoscopy allows direct observation of the fistula, documentation of the presence of tracheomalacia, and identification of the correct location of its origin, which helps to determine whether a cervical approach to the fistula is appropriate intraoperatively. In summary, H-type TEF is rare in adolescents but can present with chronic lung disease because of repeated aspirations. This case report emphasizes considering the diagnosis of TEF for any age group with recurrent cough and pulmonary infections.

References

- [1]. Zacharias J, Genc O, Goldstraw P. Congenital tracheo-oesophageal fistulas presenting in adults: Presentation of two cases and a synopsis of the literature. *J Thorac Cardiovasc Surg* 2004; 128:316e8.
- [2]. Fahmy FE, Lancer JM, Ahmed A. Late presentation of congenital tracheo-oesophageal fistula. *Eur Arch Otorhinolaryngol* 2007; 264:81e4.
- [3]. Bednarczyk D, Sasiadek MM, Smigiel R. Chromosome aberrations and gene mutations in patients with esophageal atresia. *J Pediatr Gastroenterol Nutr* 2013; 57:688e93.
- [4]. Kovesi T, Rubin S. Long term complications of congenital esophageal atresia and/or tracheoesophageal fistula. *Chest* 2004; 126:915e25.
- [5]. Negus VE. Specimen: Oesophagus from a middle-aged man, showing a congenital opening into the trachea. *Proc R Soc Med* 1929; 22:527.
- [6]. Karnak I, Senocak ME, Hic,so`nmez A, Bu`yu`kcamuk, u N. The diagnosis and treatment of H-type tracheoesophageal fistula. *J Pediatr Surg* 1997; 32:1670e4.
- [7]. Upperman SJ, Gaines B, Hackam D. H-type congenital tracheoesophageal fistula. *Am J Surg* 2003; 185:599e600.