

Management Of Tooth With Internal Root Resorption: Case Reports

Dr. Amrita Ghosh¹, Dr. Anusree R², Dr. Monideepa Mitra³

1. Assistant Professor, Dept. of Conservative Dentistry and Endodontics, RADCH, WBUHS, India

2. Post graduate student, Dept. of Conservative Dentistry and Endodontics, RADCH, WBUHS, India

3. Housestaff, Dept. of Conservative Dentistry and Endodontics, RADCH, WBUHS, India

Abstract:

Injuries to or irritation of the tooth pulp or periodontal ligament can result in tooth resorption. Internal resorption, a pathological process, makes it technically challenging to thoroughly clean and seal the root canal. It is impossible to define the anatomical extent clinically or radiographically due to numerous complicated abnormalities. Periodontal bleeding, discomfort, and trouble in obturation are additional problems that arise when internal resorption progresses through the tooth into the periodontium. Both nonsurgical and surgical methods can be used to treat internal resorption. Purpose of this paper is to describe two cases of internal resorption, where lesion has perforated the dentin in one case. Two cases were treated successfully using nonsurgical method.

Key Word: Internal resorption Perforation, Thermoplasticized gutta-percha, MTA, Non-surgical treatment.

Date of Submission: 22-04-2023

Date of Acceptance: 04-05-2023

I. Introduction

Root Resorption is a condition associated with either a physiologic or a pathologic process resulting in a loss of dentin, cementum and/or bone and Internal resorption is a defect of the internal aspect of the root following necrosis of odontoblasts as a result of chronic inflammation and bacterial invasion of the pulp tissue.⁽¹⁾ Internal root resorption (IRR) was first described in a mandibular molar in 1830⁽²⁾. It is a form of root resorption that originates in and affects the root canal wall. It can be classified into inflammatory and replacement resorption. Inflammatory resorption as the name suggests is associated with an inflammatory reaction resulting in dentin loss while replacement resorption is associated with deposition of mineralized tissue in the root canal space after initial loss of dentin⁽³⁾. Etiologic factors include trauma, caries and periodontal infections, vital root resections, excessive heat generated during restorative procedures on vital teeth, orthodontic treatment, calcium hydroxide procedures, anachoresis, cracked teeth, or simply idiopathic dystrophic changes in normal pulps^(4,5,6,7).

Odontoclasts are involved in non-specific cellular immune response to pathological and physiological stimuli, and they mediate the resorption process in dentin. Odontoclast progenitor cells can express cathepsin D, tartrate-resistant acid phosphatase (TRAP), and matrix metalloproteinase 9 and are found in the periodontal ligament and dental pulp^{8,9,10,11}. Receptor activator of nuclear factor kappa-B (RANK)/RANK ligand (RANKL) receptors mediate their function¹². They attach to mineralized dentine and create a very acidic environment with a pH of around 4.5 to start the resorptive process after being stimulated and fused to odontoclasts⁹. The clastic cells and their nutrition are provided by the pulp tissue apical to the resorptive lesion, and the infected necrotic coronal pulp tissue stimulates those clastic cells, allowing IRR to progress¹³.

The majority of teeth with IRR have no symptoms when they are first clinically identified by routine radiography. It can be easily distinguished as a radiolucent, symmetrical expansion of the root-canal space. Oval and asymmetrical shapes may also be seen because IRR does not always occur in the same way¹².

This paper presents 2 cases of non-perforating IRR treated with a nonsurgical approach.

II. Material And Methods

Case Report I:

A 32 year old male patient reported to the Department of Conservative Dentistry and Endodontics with the chief complaint of mild pain in 22. On clinical examination sinus opening was present in relation to 21 which was also slightly discoloured (Fig 1A). Both 21 and 22 were tender on percussion. IOPAR (Fig 1B) and CBCT (Fig 1C) evaluation revealed a radiolucent lesion in the coronal and middle third of root of 22. Calcified

canal and periapical pathology in relation to 21. There was history of trauma in childhood. Tooth showed no response to electric pulp tester and to cold test.

A diagnosis of necrotic pulp with chronic periapical lesion in #21 and non perforating internal root resorption in #22 was made and conventional root canal treatment was planned for both.

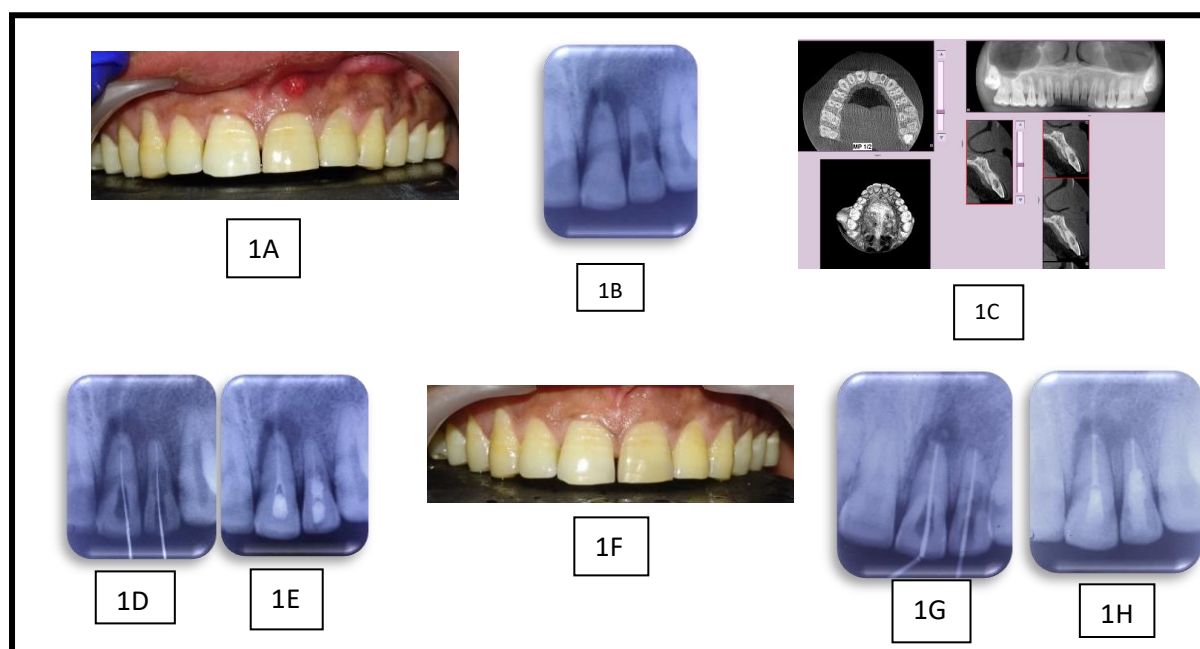
The teeth were anaesthetized using lidocaine 2% with adrenaline 1:80,000 anesthetic solution. After rubber dam placement access opening was done and working length was established with apex locator.(Dentsply Propex Pixi)(Fig 1D). The canals were biomechanically prepared using K & H files and active irrigation was done with Endoactivator and 3% Sodium Hypochlorite solution(Prime Dental,India). Calcium hydroxide(Ultracal XS of Ultradent, USA) dressing was placed for I week(Fig 1E).

Sinus opening had healed after one week(Fig 1F). At the next appointment calcium hydroxide was rinsed out with saline. Canals were irrigated with 5.25% NaOCl followed by saline and 17% EDTA(Desmear,Anabond,India). #21 was obturated by lateral condensation of Gutta percha. In #22 apical third was obturated using sectional method using AH Plus sealer (Dentsply, DeTrey, Konstanz, Germany) and Guttapercha (Fig 1G). Remainder of the canal was filled with thermoplastic gutta-percha (System B Kerr Endodontics,USA.) Coronal restoration was done with composite (Te-Econom Plus Ivoclar Vivadent Liechtenstein) (Fig 1H). 3 months recall radiograph showed satisfactory healing.

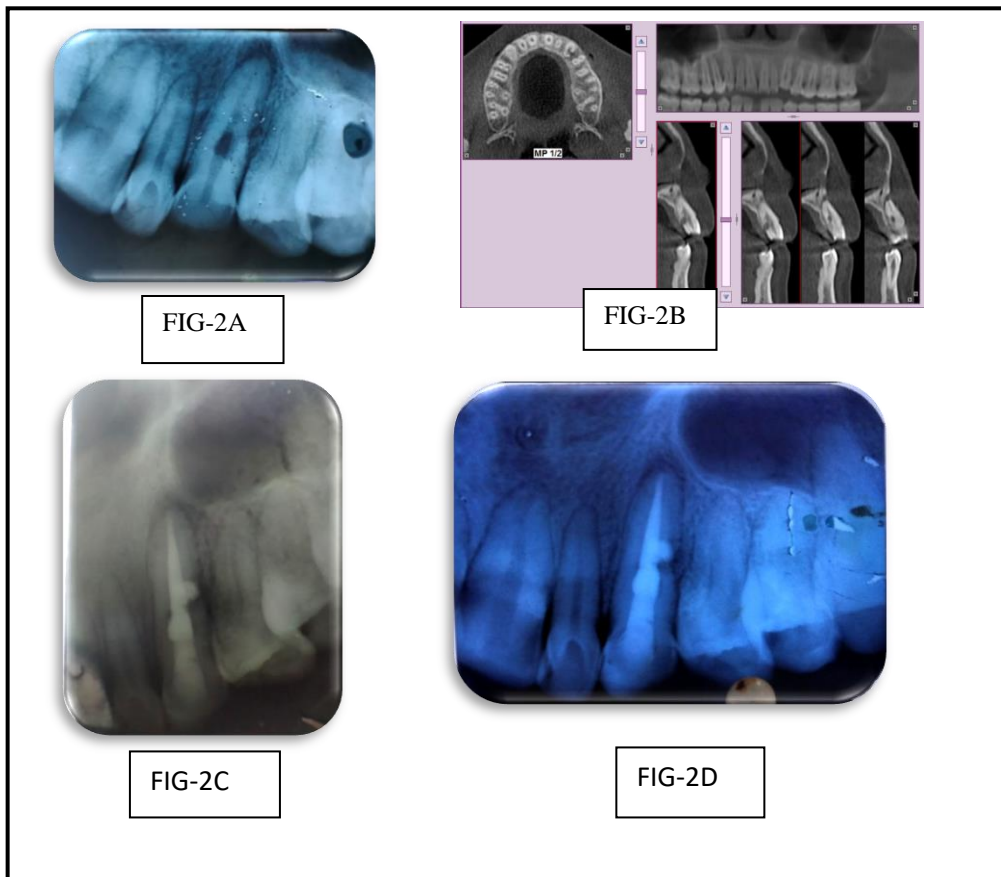
Case Report 2:

A 32 year old female patient reported to the Department of Conservative Dentistry and Endodontics with the chief complaint of mild pain in #23. On clinical examination #23 was tender on percussion. Radiographic examination revealed a radiolucent lesion in the middle third of the root canal of #23 and periapical radiolucency(Fig-2A). Tooth showed no response to electric pulp tester and to cold test. Patient gave no previous history. CBCT of #23 revealed perforating internal root resorption in #23(Fig-2B). Non surgical endodontic treatment with MTA and obturation with thermoplasticised guttapercha was planned.

Endodontic treatment in #23 was carried out similar to the previous case. On the final visit, the apical third of #23 was obturated using the sectional method, canal perforation repaired with MTA and remainder of the canal was filled with thermoplasticised gutta-percha followed by restoration with composite(Fig-2C).3 months recall radiograph showed satisfactory healing(Fig-2D).



A.Pre op clinical photo with sinus opening, B.Pre op IOPAR,C.CBCT , D.Working length IOPAR, E.Ultracal placement IOPAR, F.Clinical photo at second appointment showing healed sinus lesion. G.MasterconelIOPAR. H.Post op IOPAR



2A-Pre op IOPAR,2B- pre op CBCT,2C-Post op IOPAR,2D-3 month follow up IOPAR

III. Result

In follow up visits, both the patients were assessed clinically and radiographically. There was no complaint of pain, swelling, discharging sinus, sensitivity due to cold or hot food substances. Teeth were not tender to percussion or palpation also. Radiograph of first case revealed the gradual healing of peri apical pathology as evident through gradual elimination of radiolucency in relation to 21 (Fig 3A). IOPAR and CBCT of 2nd case showed healing of periapical pathology and lesion in relation to middle third of root in 23(Fig 3B & 3C).

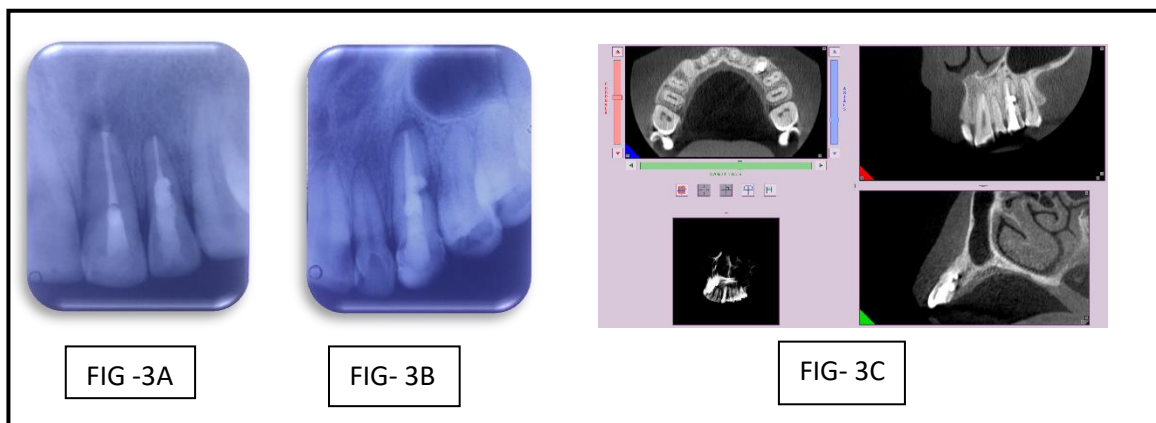


FIG- 3A: Follow up IOPAR of 1st case, 3B-Follow up IOPAR of 2nd case ,3C- Follow up CBCT of 2nd case

IV. Discussion

Teeth with internal root resorption do present a endodontic challenge and a dilemma to the clinician due to its questionable prognosis. But properly done treatment can help the patient successfully retain the tooth for prolonged period. Treatment option in tooth without perforation is endodontic therapy and in cases with perforation is a combination of endodontic therapy and surgery where required. Destruction rate of internal resorption can be fast or slow. Spontaneous repair happens quite infrequently. As a result, urgent root canal therapy is the preferred course of action as this will interrupt the resorptive process^{13,14}. Nonsurgical repair is favoured in situation when the damage is not severe, defect is apical to epithelial attachment and bleeding from the site is manageable¹⁴.

Hypochlorite use helps in reducing bleeding from perforation sites. Also, it disinfects the resorption region. In large perforations, it is better to use low-concentration hypochlorite solutions and other additional irrigants such chlorhexidine. Internal resorptions are treated with Ca(OH)₂ to stop the bleeding, necrotize the remnant pulp tissue, and make the necrotic tissue more soluble in NaOCl. Chemical methods are required to clean the canal since instruments cannot reach all parts of a resorption cavity¹³.

In these case reports we have used thermoplasticized gutta-percha, AH plus sealer and MTA to seal the resorption area. AH plus sealer has good push out strength¹⁶. Several writers have recommended different obturation methods to obturate internal resorption. Lateral and vertical condensation was suggested by Fvand and Weine. Thermafil obturation technique has been recommended by Gutman et al. The use of thermomechanical compaction is advised by Weine. Thermoplasticized guttapercha has been proven to be the best of these as it can fill the resorption defect three dimensionally¹⁷. Recently, in several studies sectional obturation was done with calcium silicate materials such as MTA, Biodentin to repair the perforation site because of its good biocompatibility, sealing ability, less leakage, lower overfilling tendency, and non-cytotoxicity. They also helps in dentin bridge formation¹⁸.

Treatment outcomes for internal tooth resorption are influenced by the degree of perforation, amount of remaining tooth structure and experience of the clinician. Based on diagnosis, the clinician must choose the mode of treatment that offers the best chance of success. The remaining tooth structure should be strong enough to support restoration. The prognosis for a perforating resorption may be favourable, but it also depends on the perforation's size, location, and possibility to be repaired. Internal tooth resorption treatment outcomes are anticipated to be favourable with appropriate care and the application of contemporary endodontic procedures and materials¹⁸.

V. Conclusion

Accurate diagnosis and an extensive understanding of the biological processes that the treatment will support are essential for success. For effective therapy, it is important to identify the location and extent of resorption lesion. And the method of treatment is selected based on this. Thus, it can be said that the development of MTA and thermoplasticized gutta percha has made it feasible to successfully treat the resorptive defect.

References

- [1]. American Association of Endodontists, "Glossary of endodontic terms," 2012, <http://www.aae.org/glossary/>.
- [2]. Bell T. The anatomy, physiology, and disease of the teeth. Philadelphia, PA: Carey and Lee Publishing; 1830:171-2.
- [3]. Andreasen JO, Andreasen FM: Root resorption following traumatic dental injuries, Proceedings of the Finnish Dental Society 88:95, 1991.
- [4]. Andreason JO: Luxation of permanent teeth due to trauma: a clinical and radiographic follow up study of 189 injured teeth, Scand J Dent Res 19:273, 1970.
- [5]. Ashrafi MH, Sadeghi EM: Idiopathic multiple internal resorption: report of case, J Dent Child 47:196, 1980
- [6]. Cabrini R, Maisto O, Manfredi E: Internal resorption of dentine: histopathologic control of eight cases after pulp amputation and capping with calcium hydroxide, Oral Surg Oral Med Oral Pathol 10:90, 1957.
- [7]. Rabinowitch BZ: Internal resorption, Oral Surg Oral Med Oral Pathol 33:263, 1972.
- [8]. Furseth R. The resorption processes of human deciduous teeth studied by light microscopy, microradiography and electron microscopy. Arch Oral Biol 1968; 13:417-31.
- [9]. Hasselgren G, Strömberg T. Histochemical demonstration of acid hydrolase activity in internal dentinal resorption. Oral Surg Oral Med Oral Path 1976;42:381-5. Journal Pre-proof
- [10]. Götz W, Quondamatteo F, Ragotzki S, et al. Localization of cathepsin D in human odontoclasts. A light and electron microscopical immunocytochemical study. Connect Tissue Res 2000;41:185-94.
- [11]. Haapasalo M, Endal U. Internal inflammatory root resorption: the unknown resorption of the tooth. Endod Topics 2006;14:60-79.
- [12]. Gunra MN. Dental root resorption. Oral Surg Oral Med Oral Pathol Radiol Endod 1999;88:647e53.
- [13]. Smulson MH, Sierask SM Histopathology & diseases of dental pulp: Weinl
- [14]. Hasselgren G, Olsson B, Harrisun JW Effects of calcium hydroxide & sodium hypochlorite on the dissolution of necrotic porcine muscle tissue. Journal of Endodontics 1988;14:125-7.
- [15]. Palekar Aparna, Maria Rahul, Jindal Varun, Perforating internal resorption: Review and case reports, Journal of Pierre Fauchard Academy (India Section), Volume 22, Issue 4, 2008, Pages 147-151, ISSN 0970-2199,
- [16]. Tanalp J, Dikbas I, Malkondu O, Ersev H, Gu'ngo'r T, Bayırlı G. Comparison of the fracture resistance of simulated immature permanent teeth using various canal filling materials and fiber posts. Dent Traumatol 2012;28:457e64

- [17]. Aggarwal M, Raj Kumar K, Lakshminarayanan L Obturation of internal resorption cavities with 4 different techniques. An invilrucumparartive study. Endodontology 2002; 14:3-8
- [18]. Li FC, Hung WC. Repair of a perforating internal resorption: two case reports. J Dent Sci. 2016 Sep;11(3):338-342. doi: 10.1016/j.jds.2013.02.030. Epub 2013 May 2. PMID: 30894993; PMCID: PMC6395144.
- [19]. Caliskan MK, Turkun M. Prognosis of permanent teeth with internal resorption: a clinical review. Endod Dent Traumatol1997;13:75e81

Dr. Amrita Ghosh. et.al.” Management Of Tooth With Internal Root Resorption: Case Reports ”.
IOSR Journal of Dental and Medical Sciences (IOSR-JDMS) 22(5), 2023, pp. 16-20.