

A Case Report of Preoperative, Intraoperative and Postoperative Complications in THR Secondary AVN Due To Sickle Cell Anemia

1). Dr. Bommiti Srinivasa ravi teja

Junior resident

Department of orthopaedics, Andhra medical college
Vishakapatnam , Andhrapradesh-530002

2). Dr KAGANA AVINASH (corresponding author)

Junior resident,

Department of Orthopaedics, Andhra medical college, vishakapatnam
, Andhrapradesh-530002

3)Dr. P V SHYAM PRASAD , M.S. ORTHO, Mch ortho

Professor of Orthopaedics

Department of Orthopaedics, Andhra medical college
Andhrapradesh-530002

ABSTRACT

BACKGROUND

AVN of the proximal femur is a one of the most common causes of proximal femur and total hip arthroplasty is the gold standard treatment . among the various causes of AVN , sickle cell anemia requires a multidisciplinary approach and has its spectra of medical and surgical complications

MATERIALS AND METHODS

This is a case report of a 27 year old male patient with arthritis of left hip secondary AVN due to sickle cell anemia was operated with uncemented total hip arthroplasty

CONCLUSION

THR in a AVN due to sickle cell disease requires a multi disciplinary approach adequate hydration , preoxygenation , appropriate vaccination , pain management and meticulous surgical procedure . THR in sickle cell anemia

KEY WORDS – avascular necrosis , total hip replacement , sickle cell anemia

Date of Submission: 26-03-2023

Date of Acceptance: 08-04-2023

I. INTRODUCTION

- ◆ Sickle cell disease is a autosomal recessive hemoglobinopathy
- ◆ Caused by point mutation in beta chain of hemoglobin
- ◆ Glutamine is replaced by valine in 6th position
- ◆ It affects the shape of the RBC (tactoids), which causes reduced Oxygen carrying capacity under low oxygen tension and impend the blood supply to the vital organs of the body

SPECTRUM OF SICKLE CELL DISEASE

Anaemia , vasocclusive crisis , chronic organ failure

◆ SKELETAL MAIFESTATIONS

avascular necrosis

Osteoporosis

Pathological factors

Infections - osteomyelitis , septic arthritis

Bony hyperplasia

Thinning of the trabeculae and cortices , marrow hyperplasia

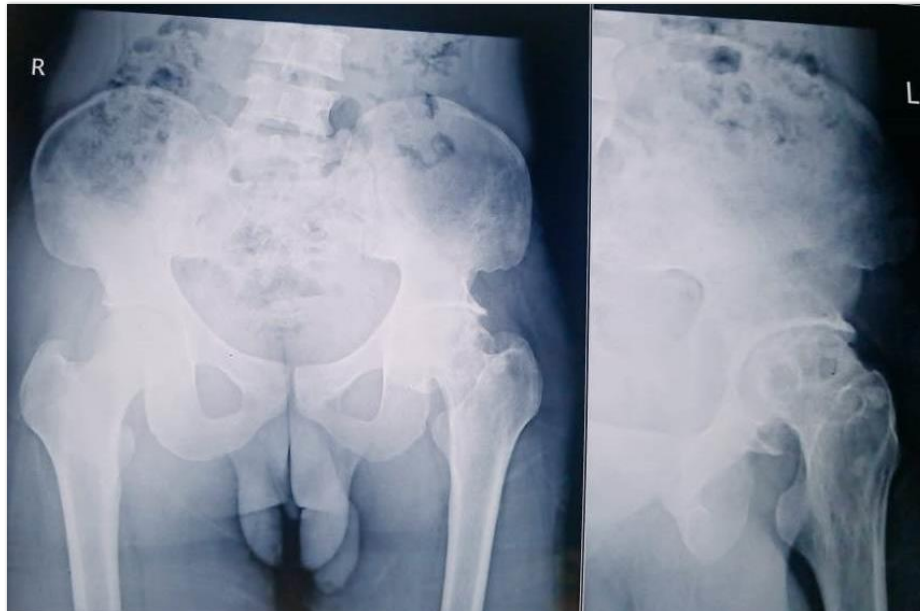Osteosclerosis (bone within a bone appearance)
Sickle cell is a one of the most common causes of AVN in the childhood
High chances of progression into osteoarthritis by 3 or 4 decade of life

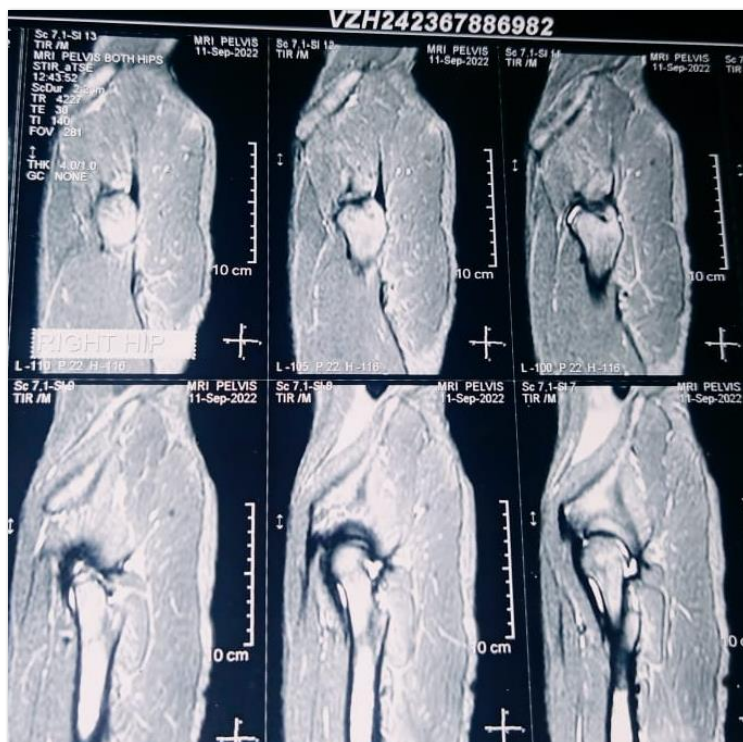
II. MATERIALS AND METHODS

This is a case report of a 27 year old male patient
Known case of sickling since child hood , with 2 episodes
General examination
Pallor + (hb – 6 gm / dl) - around 6 episodes of blood transfusion since childhood
Icterus + (Total bilirubin - 7 gm with indirect hyperbilirubunaemia)
Autosplenectomy
History of surgery for retinal detachments right eye

LOCAL EXAMIATION

Skin and soft tissue appears normal
No active signs of local infection
Tenderness over the left hip
Global restriction of movements
2cm limb shortening



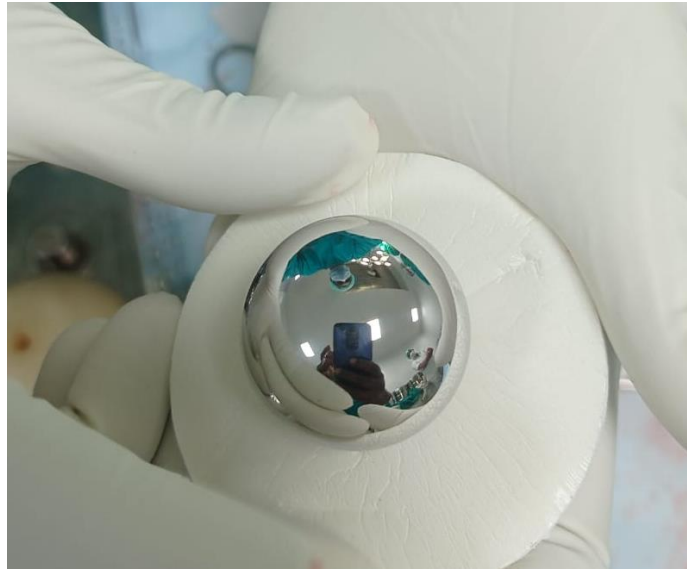


◆ **PREOPERATIVE WORK UP AND IMPLANT DATA**

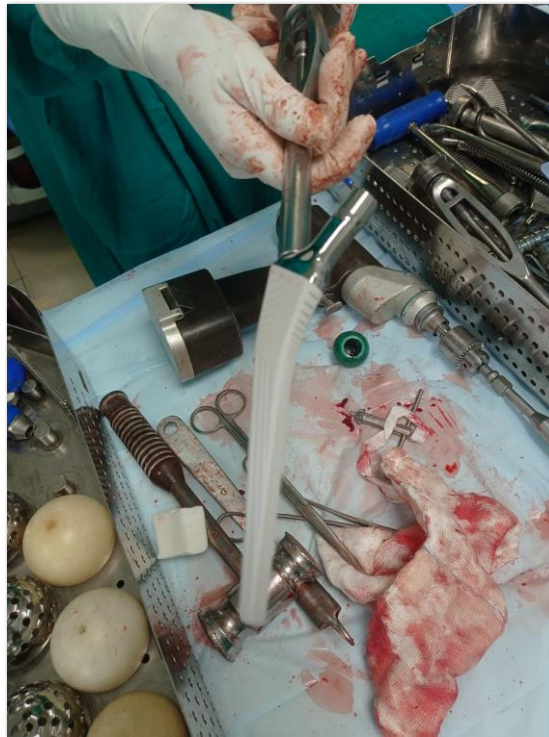
- ◆ Pre operative work up - optimize the blood and liver parameters
- ◆ Preoperative and intraoperative oxygenation 4 litres of oxygen
- ◆ Adequate hydration to the patient
- ◆ Preoperative prophylactic vaccination of pneumococcal , hepatitis - b , hempphilus influenza - b
- ◆ Hydroxy urea dose - 15 – 20 mg / kg body weight
- ◆ Oral zinc adminstartion
- ◆ Hydroxyapaptite coated stem is used due to the osteoporotic nature of the bone
- ◆ PRBC , 3 units FFP should be made available intraoperatively
- ◆ COUNSEL the patient regarding the complications

III. DISCUSSION

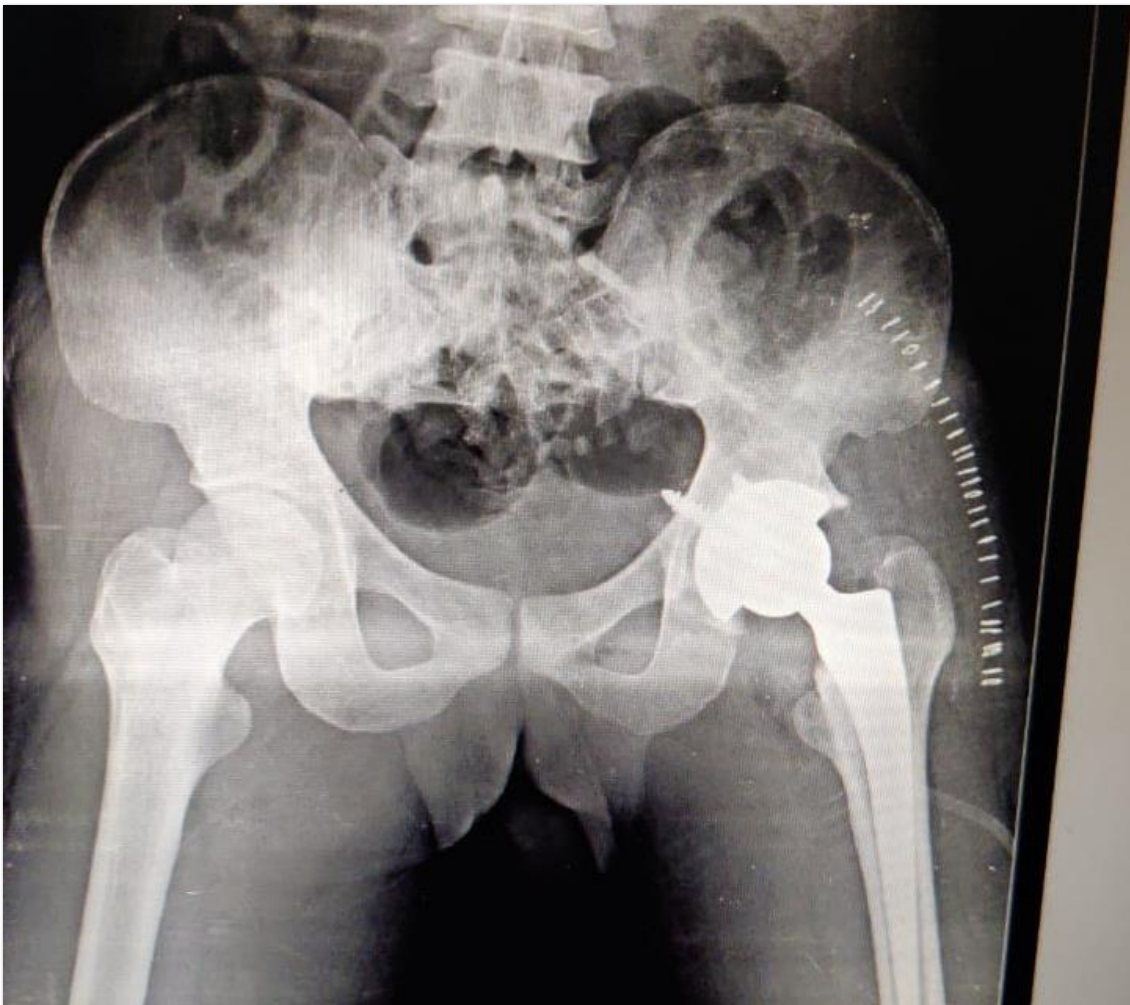
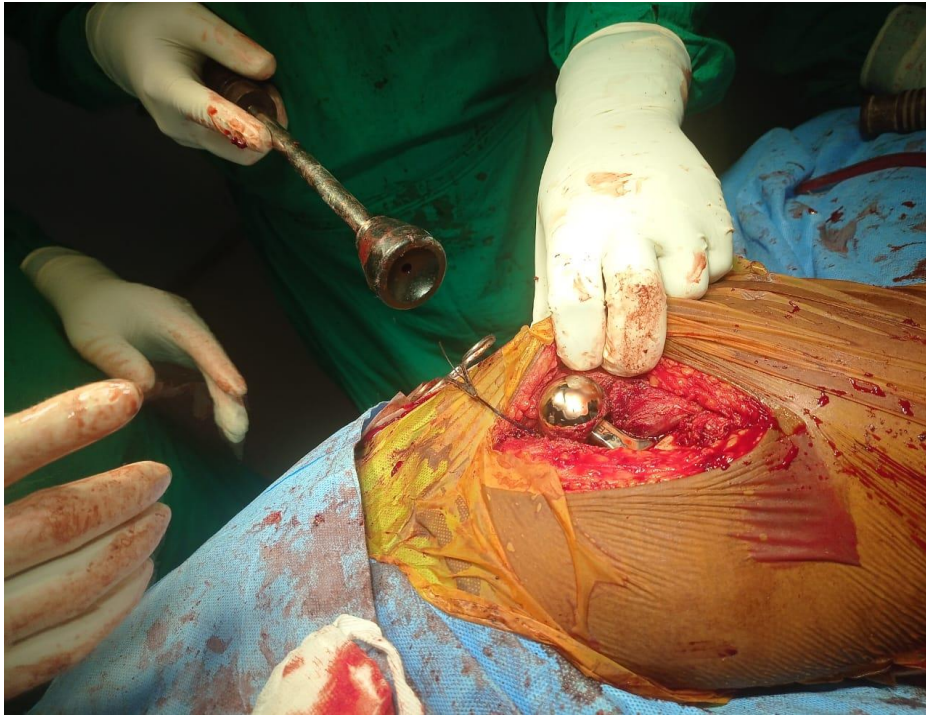- ◆ The primary THR in patients suffering from sickle cell related AVN has high percentage of medical , intraoperative and postoperative complications
- ◆ Sickle cell crisis and transfusion related are the most common medical complications
- ◆ Intraoperative complications include – vasoocclusive crisis spectra and sudden death , iatrogenic # , difficult intraoperative reaming due to osteosclerosis
- ◆ Post operative complications include – infection and aseptic loosening of the prosthesis high incidence of the revision rates
- ◆ Loosening of prosthesis can be prevented by hydroxyapatite coated stem for better ossous integration and acetabular screws to prevent acetabular component loosening
- ◆ Despite of all the complication total hip arthroplasty remains the gold standard for the avascular necrosis secondary to sickle cell disease
- ◆ Total hip arthroplasty significantly improves the range of movement , quality of life , and daily activities of living .
- ◆ Thus we should be aware of the complications before executing a total hip arthroplasty in a sickle cell anemia patient



Ceramic on poly acetabular cup



hydroxyapatite coated proximal fitting femoral stem



Postoperative x ray showing THR with restoration of offset and acetabular screws for better stability

IV. CONCLUSION

- ◆ THR in sickle cell anemia needs a multi disciplinary approach with regard to high incidence of complications
- ◆ Adequate preoperative hydration , warming , pre and intraoperative oxygenation
- ◆ Exclusion of the infective focus from the entire body
- ◆ Adequate care in handling soft tissue and bony structures
- ◆ Written and informed consent regarding the complications

References

- [1]. Osunkwo I. An update on the recent literature on sickle cell bone disease. *Curr Opin Endocrinol Diabetes Obes* 2013;20:539–546.
- [2]. Kenanidis E, Kakoulidis P, Lepetsos P, Potoupnis M, Tsiridis E. Sickle cell disease. In: Tsiridis E, ed. *The adult hip: master case series and techniques*. Springer, Cham, 2018:339–350.
- [3]. Platt OS, Brambilla DJ, Rosse WF, et al. Mortality in sickle cell disease: life expectancy and risk factors for early death. *N Engl J Med* 1994;330:1639–1644.
- [4]. Rees DC, Williams TN, Gladwin MT. Sickle cell disease. *Lancet* 2010;376: 2018–2031
- [5]. Vanderhave KL, Perkins CA, Scannell B, Brighton BK. Orthopaedic manifestations of sickle cell disease. *J Am Acad Orthop Surg* 2018;26:94–101.
- [6]. Thomas R, Dulman R, Lewis A, Notarangelo B, Yang E. Prospective longitudinal follow-up of children with sickle cell disease treated with hydroxyurea since infancy. *Pediatr Blood Cancer* 2019;66:e27816.
- [7]. Gulati Y, Sharma M, Bharti B, Bahl V, Bohra I, Goswani A. Short term results of cementless total hip arthroplasty in sicklers. *Indian J Orthop* 2015;49:447–451
- [8]. Kenanidis E, Kakoulidis P, Leonidou A, Tsiridis E. Osteonecrosis. In: Tsiridis E, ed. *The adult hip: master case series and techniques*. Springer, Cham, 2018:303–326.
- [9]. Bishop AR, Roberson JR, Eckman JR, Fleming LL. Total hip arthroplasty in patients who have sickle-cell hemoglobinopathy. *J Bone Joint Surg Am* 1988;70: 853–855.
- [10]. Hanker GJ, Amstutz HC. Osteonecrosis of the hip in the sickle-cell diseases: treatment and complications. *J Bone Joint Surg Am* 1988;70:499–506.
- [11]. Acurio MT, Friedman RJ. Hip arthroplasty in patients with sickle-cell haemoglobinopathy. *J Bone Joint Surg Br* 1992;74:367–371.
- [12]. Moran MC, Huo MH, Garvin KL, Pellicci PM, Salvati EA. Total hip arthroplasty in sickle cell hemoglobinopathy. *Clin Orthop Relat Res* 1993;294:140–148.

Dr. Bommiti Srinivasa ravi teja, et. al. “A Case Report of Preoperative, Intraoperative and Postoperative Complications in THR Secondary AVN Due To Sickle Cell Anemia.” *IOSR Journal of Dental and Medical Sciences (IOSR-JDMS)*, 22(4), 2023, pp. 31-36.