

## Complications of rectal cancer surgery review of the literature

Abdellah Moufid (1,2), MssrouriRahal(1,2)Mdaghri Jalil (1,2)  
khalidlahlou(1,2)Benamar Said (1,2), SettafAbdellatif(1,2),

<sup>1</sup>: Digestive Surgical Department B, Ibn Sina University Hospital. Rabat, Morocco

<sup>2</sup>: Faculty of Medicine and Pharmacy. Mohammed V University in Rabat. Morocco.

Corresponding author : Doctor AbdellahMoufid

Digestive Surgical Department C, Ibn Sina University Hospital. Rabat, Morocco

---

### Abstract :

*Cancer of the rectum is common worldwide; its treatment relies essentially on the surgery. It is a cumbersome process, burdened with per and postoperative complications.*

*These complications, whose study is the objective of our work, are mainly represented by per and postoperative hemorrhages, trauma of the ureter or digestive organs (hail, colon), postoperative peritonitis and wall infections, and anastomotic complications such as fistulas and stenosis. The operative complications may also be functional: digestive disorders grouped under the "low anterior resection syndrome", urinary disorders dominated by urinary incontinence and disorders of bladder drainage, and sexual disorders manifesting in men by erectile and ejaculatory dysfunctions or even sexual impotence, and in women by dyspareunia and a drop in libido.*

*Although rectal cancer has undergone enormous diagnostic and therapeutic advances, its diagnosis is often delayed and its surgical treatment is sometimes difficult with a significant complication's rate. Only prevention through a good knowledge of the anatomy of the pelvis, especially the rectum, a better control of the surgical technique and a close monitoring of the patient in the short, medium and long term avoids these complications.*

---

Date of Submission: 24-03-2023

Date of Acceptance: 06-04-2023

---

### I. Introduction:

Rectal cancer is very common throughout the world; however, it is often recognized at a late stage. The improvement of its prognosis is linked to an earlier diagnosis, it is therefore essential to know the clinical signs allowing to suspect it, and the complementary examinations useful for the diagnosis and the choice of the therapeutic protocol.

Surgery is the mainstay of treatment for rectal cancer. This has made great progress since the 1980s thanks to the advent of the technique of total excision of the mesorectum. Currently, it is no longer synonymous with abdominoperineal amputation and definitive artificial anus, sphincter preservation is possible while complying with the rules of oncological excision and preserving the patient's sexual and urinary functions.

And like any carcinological surgery, that of the rectum is also a heavy, delicate and enamelled surgery of many complications. The latter are haemorrhagic such as per and postoperative haemorrhages, traumatic especially involving the ureter but also the various digestive organs, particularly the small intestine and the colon, infectious dominated by postoperative peritonitis and wall infections, anastomotics represented by the anastomotic fistulas and stenoses, the most disabling and functional complications, digestive recognized under the "anterior resection syndrome of the rectum", urinary type of urinary incontinence and bladder emptying disorders, and sexual occurring in men by erection and ejaculation disorders or even sexual impotence, and in women by dyspareunia and a decrease in libido

### II. Methods:

The high rates of occurrence and mortality from complications of rectal cancer surgery have prompted surgeons to seek effective means of prevention by modifying operative techniques, introducing certain drugs and improving postoperative care protocols.

Our work consists of a review of the literature with the objective of studying these complications in order to better understand them and to deduce conclusions as to their means of diagnosis, management and prevention. We exclude from this work complications related to anesthesia and those common to all surgery,

namely thromboembolic, cardiovascular, respiratory complications, etc. And we mainly focus on the specific complications of rectal cancer surgery

### **III. Results and Discussion:**

#### **I – HEMORRHAGIC COMPLICATIONS:**

Rectal surgery for cancer carries a hemorrhagic risk, which even minimal, should not be neglected, this risk is mainly intraoperative (3% of presacral bleeding). It is a rare but potentially serious complication with a significant death rate.

Intraoperative hemorrhage is bleeding occurring in the middle of surgery in the operating room by lesion of a large vessel (during ligation of the inferior mesenteric artery, for example) or of a richly vascularized organ (the spleen, for example during lowering of the left colic angle) and which may be responsible for so-called major blood loss if the circulating blood mass decreases by more than 40% [1].

As for postoperative hemorrhage, it has long been defined as the need to transfuse two to six red blood cells in 24 hours. Currently, a more precise and universal definition has been proposed taking into account three important notions: the time to onset, the source of the hemorrhage and its clinical severity [2]. It allows to distinguish:

- Depending on the spawn time:
  - Early hemorrhage: occurring within the first 24 hours postoperatively and essentially testifying to a lack of hemostasis during the operation.
  - Late bleeding: occurring after 24 hours or more. It must evoke a postoperative complication that must be actively sought and identified.
- Depending on the location of the haemorrhage:
  - Intraluminal: which is expressed in the digestive lumen (anastomoses...)
  - Extraluminal: which is expressed in the abdominopelvic cavity (arterial or venous vessels, external sutures, etc.).
- Depending on the severity of the haemorrhage: ♦ Mild:
  - Weak or moderate blood loss (fall in hemoglobin less than 3 g/dl);
  - Blood transfusion of two or three red blood cells in the first 24 postoperative hours or one to three after these 24 hours;
  - Absence of significant clinical alteration of the patient;
  - Non-invasive treatment, no indication for embolization or reoperation.
- ♦ Severe if:
  - Significant blood loss (fall in hemoglobin beyond 3 g/dl);
  - Blood transfusion of more than three red blood cells;
  - Significant clinical deterioration of the patient (tachycardia, hypotension, oliguria, hypovolaemic shock, etc.);
  - Invasive treatment (arterial embolization or reoperation).

#### **II – TRAUMA OF THE URETER:**

Although rare, operative lesions of the ureter in rectal surgery and particularly cancer surgery are feared. They often go unnoticed during the operation and are potentially serious. Diagnostic delay can be the cause of significant morbidity. The means of prevention and diagnosis of these lesions must be well known by the surgeon. The treatment is generally simple when it comes to distal ureteral lesions, the most frequent case. In the event of a more proximal involvement, the treatment is often more difficult

In digestive surgery, the incidence of iatrogenic trauma to the ureter is around 15 to 23% [3]. A retrospective study was carried out from October 2003 to June 2014 in the Center Hospitalier Universitaire Gabriel-Montpied using a systematic review of the records of 43 patients who underwent pelvic surgery and in whom 46 ureteral wounds were found including 39% are due to digestive surgery. It appears that anterior resection of the rectum is the main provider of ureteral wounds with 10.9% followed by PAA with 4.4% [4].

The incidence of surgical lesions of the ureter has been constantly decreasing since the 1960s due to the increased vigilance of surgeons and progress in surgical techniques. However, a resurgence of these lesions has been observed since the end of the 1980s, mainly due to the development of laparoscopy. The growing experience of laparoscopic surgeons and the considerable progress made in the equipment used seem to be behind a further decline in the incidence of these lesions since the early 2000s [5].

The topography of ureteral wounds was divided between the pelvic ureter (80%), the iliac ureter (13%) and the lumbar ureter (6%) [6]. The majority of these lesions are unilateral.

These ureteral wounds were more frequent in the case of open surgery, around 0.3% according to the study by Preston, than during laparoscopy, with only 0.12% in a study by Han et al. In laparoscopy, lesions by coagulation affecting the ureteral vascularization were the most common [7].

a - Lesional mechanisms:

The ureter can be injured in different ways, depending on the type of surgery and the instrumentation used [8]: Ligation, haemostatic clips, Section, Crushing, Resection, Avulsion, Denudation Clotting [9].

b – Types of ureteral lesions:

Depending on the mechanism of occurrence of the ureteral lesion, the clinical picture is different and several consequences can be observed [8].

Ureteral obstruction: this is the type of lesion found in more than two-thirds of cases [3]. It can be partial or total and leading to more or less significant ureterohydronephrosis.

Immediate ureteral fistulization: the flow of urine out of the ureter results from an injury by section, resection, or avulsion. Urine drains through the drainage device, through the scar, into the peritoneum (uroperitoneum) or collects in the subperitoneal space (urinoma).

Secondary fistulization: it generally occurs in the days or weeks after surgery. It results from injury by crushing, ligation, denudation or coagulation.

Surgical treatment of ureter lesions will depend on their location and size. Certain specific conditions (cancer, infection, retroperitoneal fibrosis, history of ureteral dissection) must be taken into account. In addition, it will be appropriate [7]:

- to perform a tight and tension-free anastomosis, in non-irradiated tissue, away from any septic focus, any tumor or any fibrosis;
- to perform a perinastomoticomentum to reduce scar fibrosis, improve vascularization and peristalsis of the ureter;
- to avoid its complete mobilization by starting the dissection, limited to its anterior surface, directly above the iliac arteries;
- and always consider performing a preoperative decompression nephrostomy

several treatments can be used depending on the severity of the lesions, Section of ligature threads Uretero-ureteral anastomoses, Uretero-vesical reimplantations with anti-reflux route Ureteral replacement, Kidney mobilization and auto-transplantation, Nephrectomy

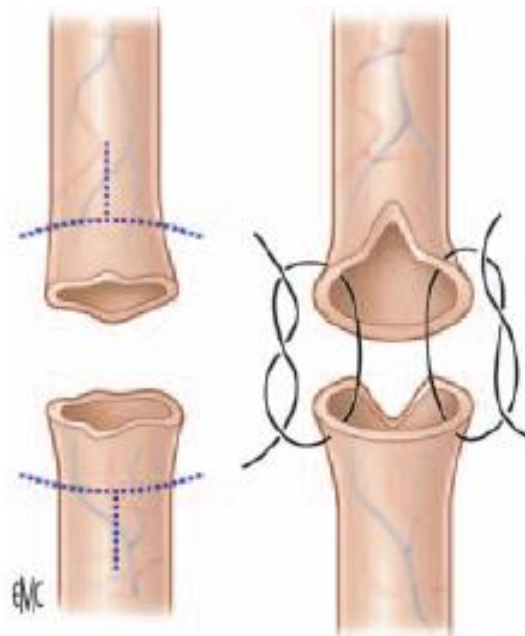


Fig 1 :Resection-anastomosis of the ureter[8].

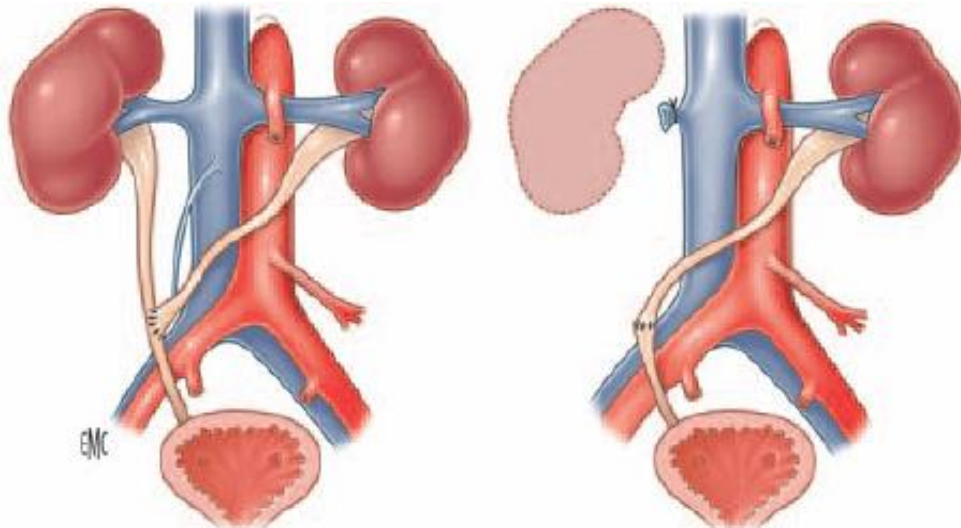


Fig 2 :End-to-side or end-to-end crossed uretero-ureterostomy[8].

### III – DIGESTIVE WOUNDS:

Digestive wounds can be seen during the different surgical approaches to rectal cancer, laparoscopy or laparotomy. It will be necessary to be particularly wary in the event of adherent pelvis. Their intraoperative diagnosis guarantees a lower rate of complications and the need for a second surgery. The organs most at risk of injury in rectal cancer surgery are mainly the small intestine and the colon. [10]

The main disorders that result from intestinal perforation are infection and hydro-electrolyte imbalance and their sequelae.

Intestinal juice and stool contain a variety of bacteria, such as *Escherichia coli*, *Enterococcus*, *Klebsiella*, *Proteus*, *Pseudomonas*, and *Clostridium*, to name a few. These bacteria produce toxins that facilitate their passage through the circulation and contribute to a downward spiral of infectious events, called “sepsis,” as well as intra-abdominal and pelvic abscesses.

Contamination of the abdominal cavity leads to inflammation of the peritoneum. In turn, the subperitoneal blood vessels become porous, promoting the leakage of interstitial fluid .

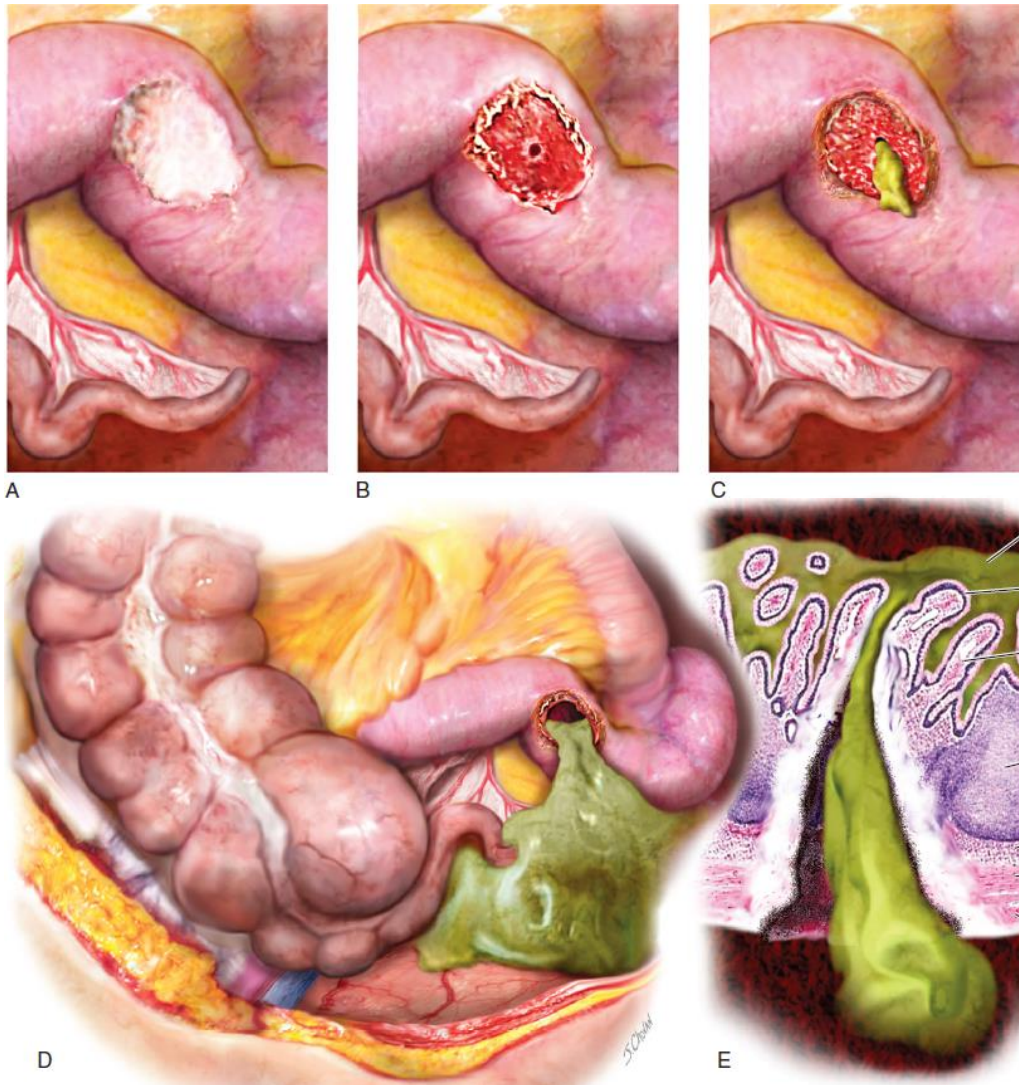

Fig 3 :A. Thermal injury creates a superficial wound in the ileum. B. Within 24 to 36 hours, the burnt eschar has detached, exposing a transmurular lesion and a small perforation. C.D. Flow of bile-stained digestive fluid through perforation, and E. Microscopic section showing transmurular perforation[22]

#### IV – INFECTIOUS COMPLICATIONS:

Infection is a major concern after rectal cancer surgery, it compromises the surgical act, is responsible for a significant additional cost, and often threatens the patient's vital prognosis. These infections are dominated by (PPO) and wall infections and explained by the fact that rectal surgery is a so-called dirty and contaminated surgery.

1 – Risk factors for postoperative infection: [11]

The interventions that most predispose to postoperative sepsis are those performed in an initial septic context. Thus, an increase in the frequency of postoperative infections in rectal surgery has been reported. The conditions of intervention (emergency situation) and the terrain of the patient (corticosteroid therapy, malnutrition, etc.) are also mentioned in the literature as contributing factors.

However, the local irradiation, the oncological pathology and the difficulty of the surgical procedure seem to be the most important elements as factors in the occurrence of postoperative sepsis.

The experience and quality of the operator are also to be taken into account in the occurrence of infection after cancer surgery of the rectum.

2 – Postoperative peritonitis:

PPOs are defined by the presence of an intraperitoneal septic focus. They are a serious complication of rectal cancer surgery, their frequency is less than 2%, and their mortality is around 30 to 50% depending on the series [12]. Disunion of a colorectal anastomosis is the main cause of PPO. These conditions pose the double problem of their recognition and their treatment.

Postoperative peritonitis:

PPOs are defined by the presence of an intraperitoneal septic focus. They are a serious complication of rectal cancer surgery, their frequency is less than 2%, and their mortality is around 30 to 50% depending on the series [12]. Disunion of a colorectal anastomosis is the main cause of PPO. These conditions pose the double problem of their recognition and surgical wound infection:

Infection of the surgical wound or surgical site is also not uncommon. It is favored by obesity and lack of asepsis [13]. Its prevention is based on a set of intraoperative care:

- The use of a 2% preparation of Chlorhexidine gluconate with isopropyl alcohol in a 70% aqueous solution for the skin. If the patient is allergic, povidone iodine is used.
- Maintenance throughout the operation of:
  - A temperature above 36°C (except for heart patients);
  - A hemoglobin saturation level (SaO<sub>2</sub>) above 95%, or as high as possible in the event of underlying respiratory failure;
  - A blood sugar level, for diabetic patients, of less than 1.98 g/l;
  - Administration of an additional dose of antibiotic if the surgical procedure is prolonged or if there is significant intraoperative blood loss (> 1.5 liters in adults);
  - Covering the surgical site with a sterile dressing at the end of the operation;

Treatment is based on regular local care and antibiotic therapy during their treatment.

#### **V – ANASTOMOTIC FISTULAS:**

The occurrence of AF in rectal cancer surgery is a major complication often associated with increased postoperative morbidity and mortality and lengthening of hospital stay [14]. The frequency and consequences of AF vary according to depending on the type of anastomosis. The risk of anastomotic disunity on a colorectal anastomosis varies between 5 and 20% [15,16].

It is usually an early complication, with multiple short- and long-term consequences. In the short term, AF can be life-threatening for the patient due to its septic but also hemorrhagic consequences. In the long term, AF exposes to the risk of anastomotic stenosis, with functional consequences that can alter the quality of life. Finally, the occurrence of AF is a predictive factor for reduced long-term overall survival [17]. Some authors have also reported a negative impact of AF on disease-free survival after rectal excision for cancer, thus compromising oncological results [18].

#### **VI – DIGESTIVE FUNCTIONAL DISORDERS:**

After rectal excision for cancer, if, for the patient, sphincter preservation is very much preferred to performing an APA with permanent colostomy, the functional result observed is sometimes poor to the point that it significantly alters the quality of life of the patients [19]. It is therefore important to know precisely the functional consequences of proctectomies for cancer in order to be able, when possible, to propose means of correcting the disorders observed.

#### **VII – SEXUAL AND URINARY DISORDERS:**

Sexual and urinary disorders after rectal cancer surgery are common. Before the introduction of the TME technique, the incidence of urinary and sexual dysfunction was high, with respective rates reported from 10 to 30% and 40 to 60%. Since the integration of autonomic nervous system preservation techniques in TME, the incidence of these complications has been reduced, with rates of urinary and sexual disorders ranging from 0 to 5% and 10 to 35% respectively [20]. Nevertheless, warning the patient preoperatively of the possibility of occurrence of these disorders is a necessity for acceptance and good postoperative care. The knowledge of the anatomy of the autonomic innervation of the pelvis is essential for the surgeon to minimize the risk of nerve damage. However, these sequelae are probably of multifactorial origin as shown in the literature [21].

#### **IV. Conclusion :**

Rectal surgery for cancer is a surgery fraught with many complications, both pre and postoperative, each of which needs to be recognized and treated as early as possible.

Hemorrhage, pre or postoperative, is one of these complications. Because it involves the vital prognosis of the patient, it is essential to diagnose it and take care of it before the installation of a possible state of hemorrhagic shock.

This surgery also causes ureteral wounds, the management of which is essentially based on early or even intraoperative detection, as well as correct initial knowledge of the level and size of the lesion.

The operative time is also led by a significant risk of injury to the digestive organs and mainly the small intestine and the colon, given their mobility and their proximity to the rectum. The prognosis of these wounds is directly linked to the time of discovery and the speed of treatment.

As for infectious complications, they are dominated by PPO whose prognosis is conditioned by the speed of diagnosis and the effectiveness of the treatment implemented. Wound infection is also a dreaded complication requiring rigorous postoperative care.

AF is a major complication in rectal cancer surgery, responsible for increased morbidity and postoperative mortality. Its diagnosis and its treatment must be early because it involves the vital prognosis by the state of septic shock that it can generate.

#### Data Availability Statement

The data that support the findings of this article are available from the corresponding author upon reasonable request.

#### Competing interests:

The authors have no conflicts of interest and source of funding. The subject of the article had no commercial interest, no financial or material support.

#### Ethics statement

Drs Abdellah Moufid, , Settaf Abdellatif, Benamar Said, Khalidlahlou, Mdaghri Jalil, Mssrouri Rahal declare no conflict of interest.

### Références

- [1]. **Gonzalez EA, Jastrow KM, Holcomb JB, Kozar RA.** Hemostasis, surgical bleeding, and transfusion [Chapter 4]. In : Brunicaardi FC, Andersan DK, Billiar TR, Dunn DL, Hunter JG, Matthews JB, et al., editors. Schwartz's principles of surgery. 9th ed. New York : McGraw- Hill; 2010.
- [2]. **Oumaima-Hily FADLI.** Thèse : Complications chirurgicales précoces de la DPC dans le traitement de l'adénocarcinome de la tête du pancréas. Rabat 2017, N° 04
- [3]. **Karmouni T, Patard JJ, Bensalah K, Manunta A, Guille F, Lobel B.** Prise en charge urologique des traumatismes iatrogènes de l'uretère. *Prog Urol* 2001;11:642-6.
- [4]. **Guandalino M et al.** Prise en charge en charge endoscopique des plaies urétérales de découvertepostopératoire. Etuderétrospectiveunicentrique d'octobre 2003 à juin 2014. *Prog Urol* (2016).
- [5]. **Al-Awadi K, Kehinde EO, Al-Hunayan A, Al-Khayat A.** Iatrogenic ureteric injuries: incidence, aetiological factors and the effect of early management on subsequent outcome. *Int Urol Nephrol* 2005;37: 235- 41.
- [6]. **Brandes S, Coburn M, Armenakas N, McAninch J.** Diagnosis and management of ureteric injury: an evidence-based analysis. *BJU Int* 2004;94:277—89.
- [7]. **Klap J, Phé V, Chartier-Kastler E, Mozer P, Bitker MO, Roupret M.** Etiologies et traitement des plaies iatrogènes de l'uretère: analyse de la littérature. *Progrès en Urologie* 2012 ; 22 :913-919.
- [8]. **Culty T, Leuret T, Botto H.** Lésionsopératoires de l'uretère. EMC (Elsevier Masson SAS, Paris) Urologie 2008 ; 18-160-A-10.
- [9]. **Ostrzenski A, Radolinski B, Ostrzenska KM.** A review of laparoscopic ureteral injury in pelvic surgery. *ObstetGynecolSurv* 2003;58:794—9.
- [10]. **Michael S. Baggish.** Major Complications Associated With Laparoscopic Surgery. Elsevier Inc 2017. Chapter 121 ; Part 5 ; Sestion 18 : 1283-1316
- [11]. **Parc Y, Frileux P, Dehni N, Ollivier J, Turet E, Parc R.** Réinterventions pour complications infectieuses intrapéritonéalespostopératoires. EMC ; 2003 : 40-80.
- [12]. **Roehrborn A, Thomas L, Potreck O, Ebener C, Ohmann C, Goretzki PE, et al.** The microbiology of postoperativeperitonitis. *Clin Infect Dis* 2002;33:1513—9.
- [13]. **Tang R, Chan HH, wang YL, et al.** Risk factors for surgical site infection after elective resection of the colon and rectum : a single center prospective study of 2809 consecutive patients. *Ann Surg* 2001; 234: 181-189.
- [14]. **Huebner M, Hübner M, Cima RR, Larson DW.** Timing of complications and length of stay after rectal cancer surgery. *J Am CollSurg* 2014;218:914—9.
- [15]. **Matthiessen P, Hallböök O, Rutegård J, Simert G, SjødahlR.** Defunctioning stoma reduces symptomatic anastomotic leakage after low anterior resection of the rectum for cancer: a randomized multicenter trial. *Ann Surg* 2007;246:207—14.
- [16]. **Gastinger I, Marusch F, Steinert R, et al.** Protective defunctioning stoma in low anterior resection for rectal carcinoma. *Br JSurg* 2005;92:1137—42.
- [17]. **Freeman RK, Vyverberg A, Ascoti AJ.** Esophageal stent placement for the treatment of acute intrathoracic anastomotic leak after esophagectomy. *Ann Thorac Surg* 2011;92:204—8 [discus-sion 208].
- [18]. **Mirnezami A, Mirnezami R, Chandrakumaran K, Sasapu K, Sagar P, Finan P.** Increased local recurrence and reduced survival from colorectal cancer following anastomotic leak : systematic review and meta-analysis. *Ann Surg* 2011;253:890—9.
- [19]. **Tuech JJ, Michot F.** Cancer du rectum: Préservationsphinctérienne et qualité de vie. *Ann Chirg* 130 (2005) 3-4.
- [20]. **Faucheron JL, Voirin D, Legros JR.** La préservation des nerfs du pelvis dans la chirurgie du rectum. e-mémoires de l'Académie Nationale de Chirurgie 2007,6 (1) : 17-26.
- [21]. **Alves A.** Recommendations for clinical practice. Therapeutic choices for rectal cancer. How can we reduce therapeutic sequelae and preserve quality of life? *Gastroenterol Clin Biol* 2007;31:1S52-62.
- [22]. **Michael S. Baggish.** Major Complications Associated With Laparoscopic Surgery. Elsevier Inc 2017. Chapter 121 ; Part 5 ; Sestion 18 : 1283-1316

Abdellah Moufid, et. al. “ Complications of rectal cancer surgery review of the literature.” *IOSR Journal of Dental and Medical Sciences (IOSR-JDMS)*, 22(4), 2023, pp. 14-20.