

# A Case Report On Triplet Pregnancy Complicated By Deep Venous Thrombosis

Dr Sreesubhageetha D, Dr Usha Vishwanath

Department of Obstetrics and Gynaecology

Sri Ramachandra Medical College, Chennai.

## ABSTRACT:

DVT is one of the rare and important causes of maternal morbidity and mortality. Since pregnancy is a hypercoagulable state, DVT occurs more frequently than nonpregnant females. The most common symptoms are swelling, pain and warmth in the affected limb. Anticoagulants form the first line and mainstay of treatment. Here we review a case of 31 years old, G2A1 at 29weeks+2days gestational age, DCTA triplets pregnancy, with acute DVT in the right leg.

**Keywords:** Deep Venous Thrombosis, DCTA Triplet Pregnancy, Anticoagulation.

Date of Submission: 16-04-2023

Date of Acceptance: 29-04-2023

## I. INTRODUCTION:

Deep venous thrombosis is one of the many causes of maternal mortality. Pregnancy increases the risk of venous thrombo-embolism 4-5 fold over that in the nonpregnant state. The two manifestations of VTE are deep venous thrombosis (DVT) and pulmonary embolism (PE). Sequelae of DVT and PE include complications such as pulmonary hypertension, post-thrombotic syndrome and venous insufficiency. The standard care of DVT is anticoagulation.

## II. CASE DESCRIPTION:

A 31 years old, G2A1 at 29weeks+2 days gestational age with Dichorionic Triamniotic triplet pregnancy resulted from Invitro Fertilisation which was done in a fertility centre. Prophylactic cervical encercilage was done at 20 weeks of gestation. She came to SRMC with complaints of breathlessness, pain over bilateral thighs and swelling of right thigh for one week.

### General Examination:

Patient is well nourished, averagely built, afebrile, Pulse rate-100 bpm, Blood pressure- 110/70mmHg, pedal oedema was present.

### Systemic Examination:

CNS: Patient was conscious, alert, and well oriented to time, place and person.

RS: Bilateral air entry present, Bilateral chest clear

CVS: S1 S2 heard, No murmur heard

P/A: Uterus overdistended for Gestational age, relaxed, multiple fetal parts felt, FHR 1 +/152bpm, FHR 2 +/135bpm, FHR 3 +/128bpm

P/V: No indication of p/v thus not performed

L/E:

Right thigh: 8x4cm indurated tender swelling at medial aspect of right thigh was noted. Tenderness was present. No warmth and no evidence saphena varix.

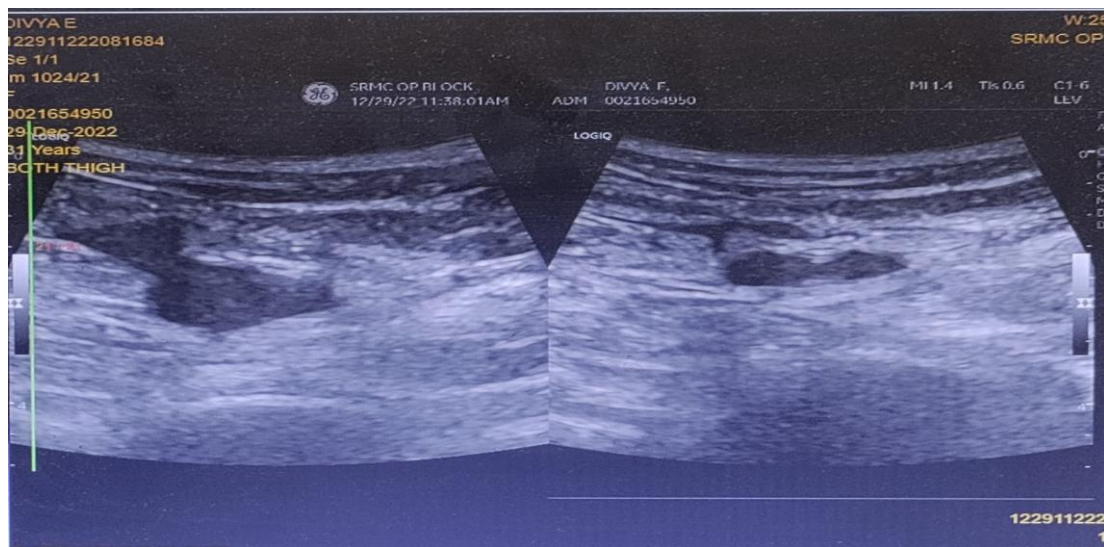
### Investigations:

Haemoglobin- 10.7gm/dl, TC- 11450cells/cu.mm, Platelet- 1.72Lakhs/cu.mm, Sodium- 135mmol/L, potassium- 4.5mmol/L, urea- 4mg/L, creatinine-0.4mg/L, SGOT- 33, SGPT-13, Total bilirubin-0.44mg/dl, Direct Bilirubin- 0.07mg/dl, PT- 12.3 seconds, INR- 1.04, APTT- 22.9 seconds, D-Dimer-4.75.

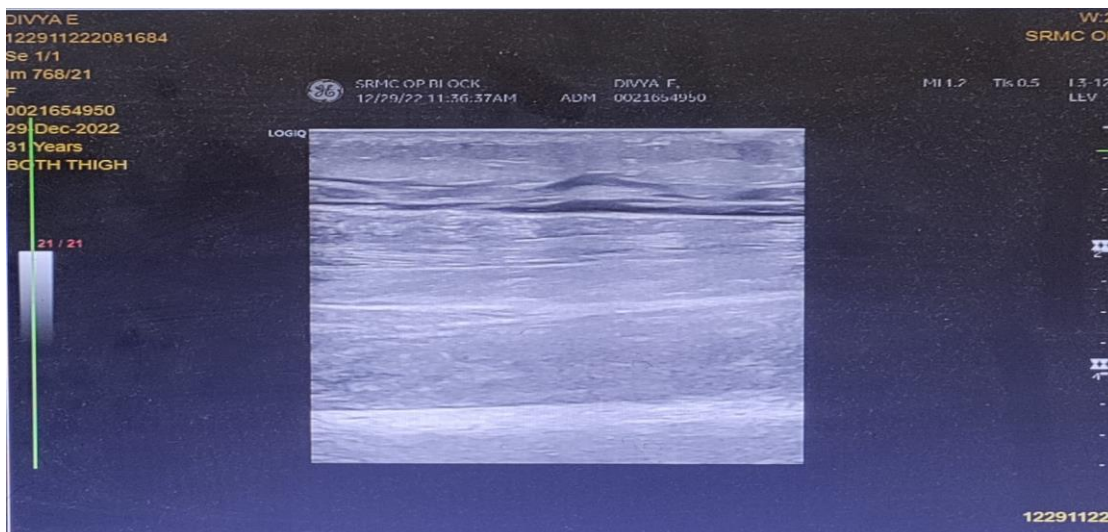
Her Antenatal scan at 29weeks+2 days showed DCTA triplets with 29weeks+3 days GA, with Estimated fetal weight of Fetus A-1249grams, Fetus B- 1655grams and Fetus C – 1723grams. Fetal doppler showed increased diastolic flow in Middle Cerebral Artery of Fetus A and Normal doppler findings in other fetuses B and C.

Her Doppler Ultrasound of bilateral lower limbs showed deep vein thrombosis of right common femoral, superficial femoral and deep femoral veins extending upto the popliteal veins, slow flow in left lower limb and subcutaneous edema in bilateral limbs.

She was admitted in ICU and PT/INR was monitored. She was started on Inj.Fragmin (LMWH) 5000IU S.C twice daily, advised to restrict mobility and compression stockings. Maternal steroid coverage was done to achieve fetal pulmonary maturity. Preterm counselling was given by neonatologists. Patient had complaints of calf pain for which lower limb venous doppler was repeated which showed no evidence of deep vein thrombosis. Inj.Fragmin was stopped 24 hours before surgery. In view of DCTA triplets complicated by DVT, Elective LSCS was done at 30 weeks+3 days. Birth weights of triplet 1, triplet 2 and triplet 3 were 1.260kg, 1.550kg and 1.630kg respectively. Inj.Fragmin 5000IU S.C once daily was started 12 hours after surgery. Coagulation profile done on postoperative day 2 showed PT-12.0seconds, INR – 1.02 and APTT-25.7 seconds. Inj.Fragmin 5000IU was stopped on Post operative day 7 and patient was started on oral anticoagulation. All the three triplet babies shifted to mother side on day 14 of life, all three babies were on room air and were given kangaroo mother care. Patient was discharged on postoperative day 15.



**Figure 1 : Doppler of right lower limb showing blood file changes suggestive of DVT**



**Figure 2 Doppler ultrasound of right thigh showed thrombosis in common femoral vein**

### **III. DISCUSSION:**

Pregnancy is a prothrombotic state in ultimate preparation for bleeding prevention at the time of delivery. Coagulation factors II, VII, VIII, IX, X, XII, von Willebrand factor, and fibrin increases, protein S decreases, and there is increased resistance to activated protein C. Decreased venous flow velocity, venous distention, and obstruction of venous return by an enlarging uterus lead to stasis of blood flow.

Important risk factors are previous history of VTE, Thrombophilia, Age >35 yrs, Body mass index >30 kg/m<sup>2</sup>, Immobility, Nulliparity, Multiple gestation, Gestational diabetes, Preeclampsia, Smoking, Sickle cell anaemia, SLE.

Diagnosis can be made by various investigation such as venous doppler while CECT and MRI can confirm the diagnosis and reveal the extent of thrombosis.

Pulmonary embolism is the most fatal complication occurring in 13% of cases.

In Triplet pregnancy, delivery has to be planned at 34 weeks or if the pregnancy is complicated by any other medical conditions, delivery can be planned earlier taking into consideration of fetus maturity, Gestational age, risks and benefits.

Essentially all pregnant patients diagnosed with DVT should be treated with systemic anticoagulant therapy. For patients who do not tolerate or who are not candidates for anticoagulation, inferior vena cava (IVC) filter may be an option.

Low Molecular Weight Heparin and Unfractionated Heparin are the most evidence-supported anticoagulant agents for treatment of DVT in pregnancy and they reduce VTE mortality and recurrence.

If a patient on continuous heparin infusion, it has to be stopped 4 to 6 hours before delivery to allow for normalization of partial thromboplastin time or the anti-Xa level. If a patient remains on LMWH, it should be discontinued 24 h prior to a scheduled delivery.

Following delivery, therapeutic LMWH or UFH can be restarted 24 hours after epidural catheter removal, 6 to 12 hours after a vaginal delivery, or 12 to 24 hours after Cesarean section, if there are no bleeding concerns. Therapeutic anticoagulant therapy should be continued for the duration of the pregnancy and for at least 6 weeks postnatally and until at least 3 months of treatment has been given in total. Before discontinuing treatment the continuing risk of thrombosis should be assessed.

In patients who have recurrent VTE while on full-dose medical therapy or have a contraindication to systemic anticoagulation, placement of an IVC filter is an option.

### **IV. Conclusion:**

Pregnancy-associated VTE is a leading contributor to maternal morbidity and mortality. Normal pathophysiological changes during pregnancy create a prothrombotic milieu, expanding baseline risk, and require risk stratification to determine those who will derive the greatest benefit from thromboprophylaxis. All pregnancies has to be screened for DVT and scoring has to be done to identify the pregnant women at high risk of developing thrombosis. Those who are at high risk has to monitored frequently and vigilantly. If pregnant mother develops deep venous thrombosis, the condition has to be managed in tertiary care setup with multidisciplinary approach. Anticoagulation in pregnancy have both maternal and fetal side effects. The preferred anticoagulant in pregnancy are heparin compounds and during lactation is warfarin.

### **REFERENCES:**

- [1]. Mishra A, Inamdar S. Deep Venous Thrombosis in Pregnancy. *J South Asian Feder Obst Gynae* 2020;12(1)48-50.
- [2]. *Data Journal of the American College of Cardiology*, ISSN: 0735-1097, Vol: 76, Issue:18, Page: 2128-2121.
- [3]. Dresang, Lee T et al. "Venous thromboembolism during pregnancy." *American family physician* vol. 77,12 (2008): 1709-16.
- [4]. Devis, Paola, and M Grace Knuttinen. "Deep venous thrombosis in pregnancy: incidence, pathogenesis and endovascular management." *Cardiovascular diagnosis and therapy* vol. 7, Suppl 3 (2017): S309-S319.