

Complex Imaging Diagnosis of Diffuse Liver Lesion

Sokolov V.N., Rozhkovskaya G.M., Tsvigovskiy V.M., Dorofeeva T.K., Korsun A.A., Dolgushyn O.A., Dius E.N., Sliusarenko A.D., Krupnik I.A., Arbatskaya A.S.

 Date of Submission: 12-04-2023

Date of Acceptance: 25-04-2023

I. Introduction

Liver disease can be acute (lasting less than 6 months) or chronic (lasting more than 6 months).

Acute diseases are dominated by hepatitis of viral origin (A and B), hepatitis caused by taking medications such as paracetamol, intoxication or other reasons. Most of the time they are benign, but some of them can cause serious consequences..

Chronic liver diseases are mainly of viral origin (hepatitis B and C), but they also arise from alcohol consumption, problems in the bile ducts of metabolic origin, autoimmune or vascular changes..

Sometimes these diseases progress to cirrhosis of the liver, leading to the loss of liver cells, with progressive fibrosis and severe distortion of the normal structure of this organ.

We set the task to study radiological research methods in diffuse liver diseases.

II. LEADING IMAGING IN DIFFUSED LIVER DISEASES

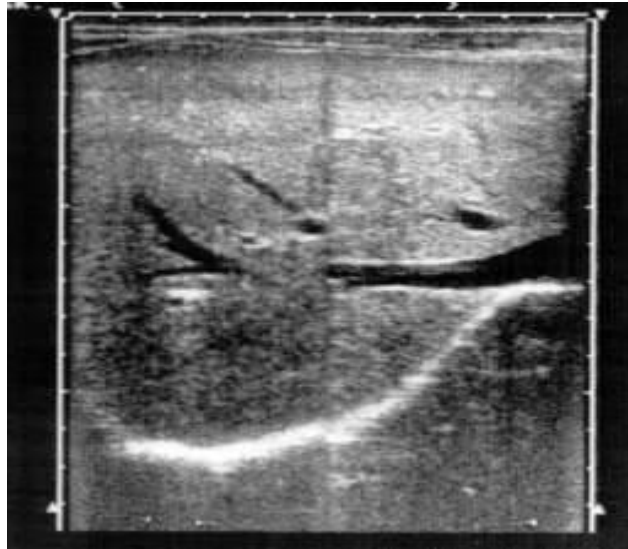<ul style="list-style-type: none"> • • Sonography, CT, MRI 	<ul style="list-style-type: none"> • overall assessment of liver morphology
<ul style="list-style-type: none"> • • Hepatoscintigraphy (HSG) 	<ul style="list-style-type: none"> • assessment of the macrophage system of the liver
<ul style="list-style-type: none"> • • Hepatobiliscintigraphy (HBSG) 	<ul style="list-style-type: none"> • biliary function of the liver
<ul style="list-style-type: none"> • • Doppler Flowmetry (DFM) 	<ul style="list-style-type: none"> • hepatic hemodynamics
<ul style="list-style-type: none"> • • RIA of the level of bile acids in blood serum 	<ul style="list-style-type: none"> • assessment of the degree of cholestasis
<ul style="list-style-type: none"> • • Celiacography, DFM 	<ul style="list-style-type: none"> • hepatic artery system
<ul style="list-style-type: none"> • • Celiacography, portography, contrast MR angiography 	<ul style="list-style-type: none"> • portal venous system
<ul style="list-style-type: none"> • CT 	<ul style="list-style-type: none"> • fatty hepatitis
<ul style="list-style-type: none"> • CT, GBSG 	<ul style="list-style-type: none"> • differentiation of hepatic and obstructive jaundice
<ul style="list-style-type: none"> • MRI 	<ul style="list-style-type: none"> • detection of malignancy and regeneration in liver cirrhosis

Acute hepatitis, viral hepatitis (A, B, C, D, E, F, G)

- Uniform increase in the size of the liver
- Diffuse decrease in echogenicity of the parenchyma, symptom protruding vessels
- Enlargement of the spleen (more often in children)
- Enlargement of lymph nodes in the gates of the liver, pancreatic region, lesser omentum
- Some increase in the average linear velocity of blood flow
- The diameter of the portal vein is moderately enlarged
- Reducing and slowing down the function of macrophages and hepatocytes, cholestasis

Ultrasound diagnosis of acute hepatitis

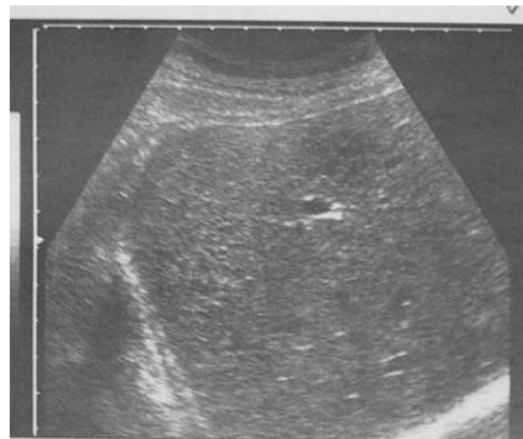Echogram of the liver is normal



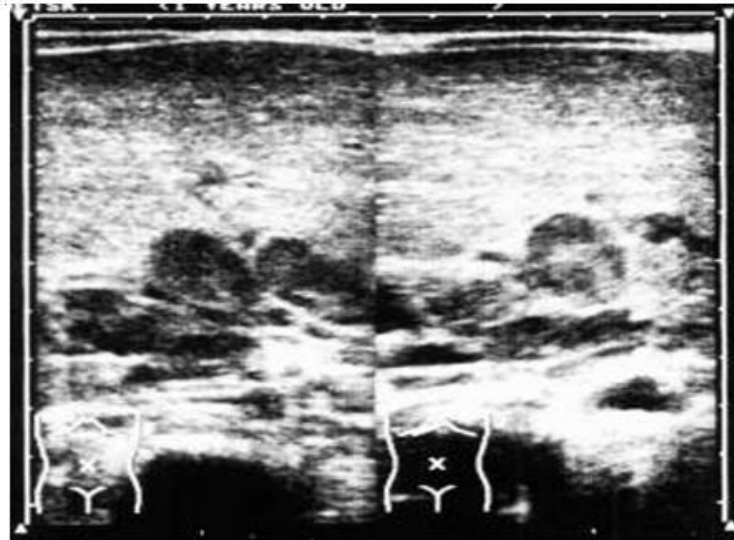
Acute hepatitis. Hepatomegaly. An uneven decrease in the echogenicity of the parenchyma, an indistinctly expressed heterogeneity of the structure due to the processes of protein degeneration, necrosis, regeneration, and edema of hepatocytes.

Acute viral hepatitis in a child, cholestatic variant. Prod. and poper. slices. Symptom "double-barreled", the size of the portal vein and the common bile duct are almost equal. Periportal hyperechogenicity, depletion of the vascular pattern. Increased echogenicity of the liver.

Ultrasound diagnosis of viral hepatitis

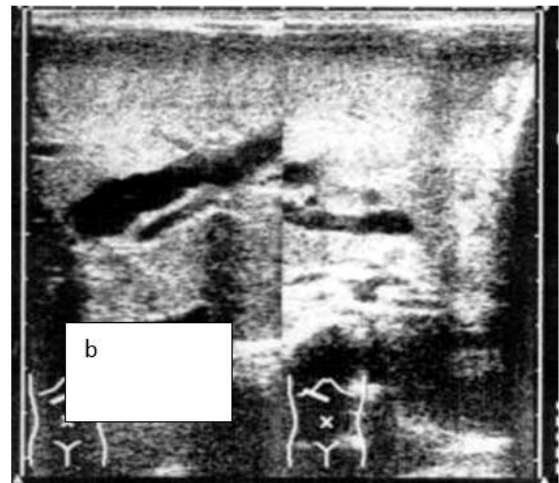
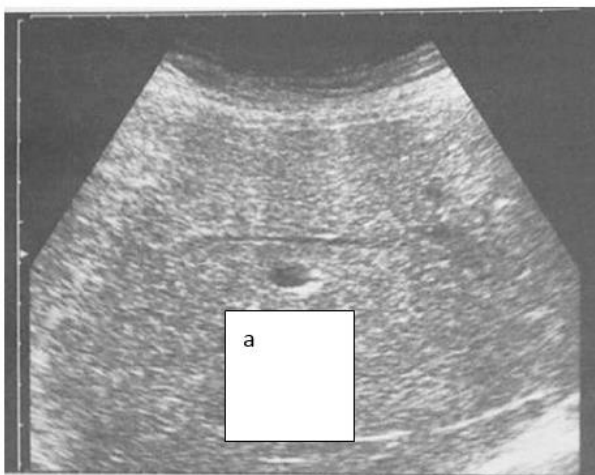

Acute viral hepatitis in a child. Cross section. Lymph nodes in the hilum of the liver, pancreatic region and lesser omentum are enlarged, heterogeneous (hyperechoic center, hypoechoic periphery). chronic hepatitis chronic recurrent destructive-inflammatory process with necrosis, fibrosis, but while maintaining the overall architectonics of the liver



- Enlargement of the liver, including the caudate lobe
- Diffuse heterogeneity of the echotexture of the parenchyma
- Thickening of the hepatic ligaments
- Persistent compaction and thickening of the vascular walls of the portal vein branches
- An increase in the diameter of the portal vein in the right lobe by more than 1.3 cm, a decrease in portal blood flow
- Narrowing of the lumen of the hepatic veins, impaired blood flow
- Thickening of the gallbladder wall
- Hepatomegaly, splenomegaly with HSG
- Heterogeneity of radiocolloid inclusion
- Reduced effective hepatic blood flow
- Decreased index of hepatic capture, increased proportion of the spleen
- Dyskinesia of the gallbladder, cholestasis

Ultrasound diagnosis of chronic hepatitis

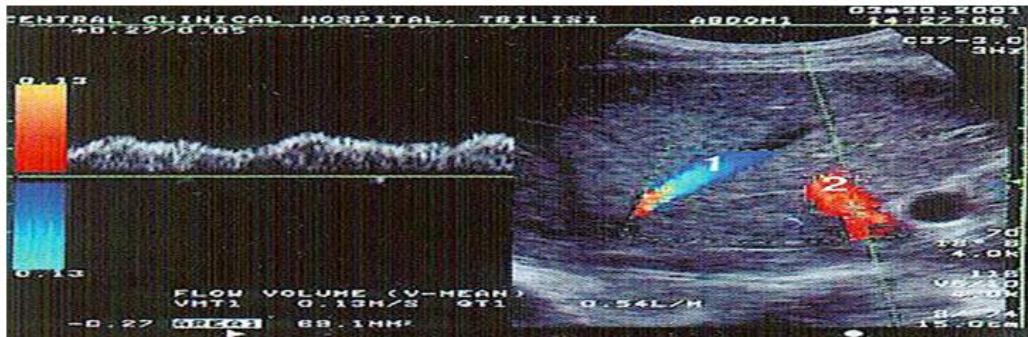


- a. chronic hepatitis. Uneven increase in echogenicity of the parenchyma, granularity of the structure, insulting the vascular pattern, without significant weakening in the deep sections of the right lobe of the liver.
- b. chronic hepatitis. Prod. and poper. slices.
- c. Expansion of the intrahepatic bile ducts.
- d. duplex doppler study

Different degree of blood flow disturbance in the hepatic veins in hepatitis:

- 1- biphasic hemodynamic curve with no short reverse current phase.
- 2 - plane wave without phase oscillations.

Radionuclide semiotics of chronic hepatitis



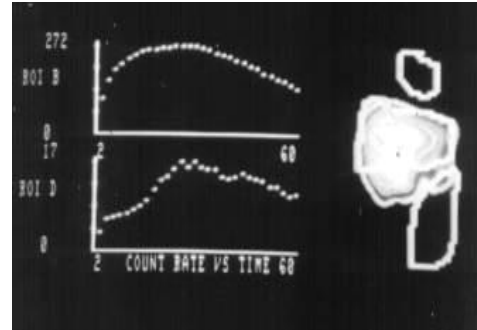
Polypositional hepatoscintigram. Enlargement of the liver, heterogeneity of the inclusion of radiopharmaceuticals.

According to the HSG and HBSG:

- persistent decrease in effective hepatic blood flow,
- low index of hepatic capture,
- increase in the proportion of the spleen,
- inhibition of hepatocyte function,
- dyskinesia of the gallbladder

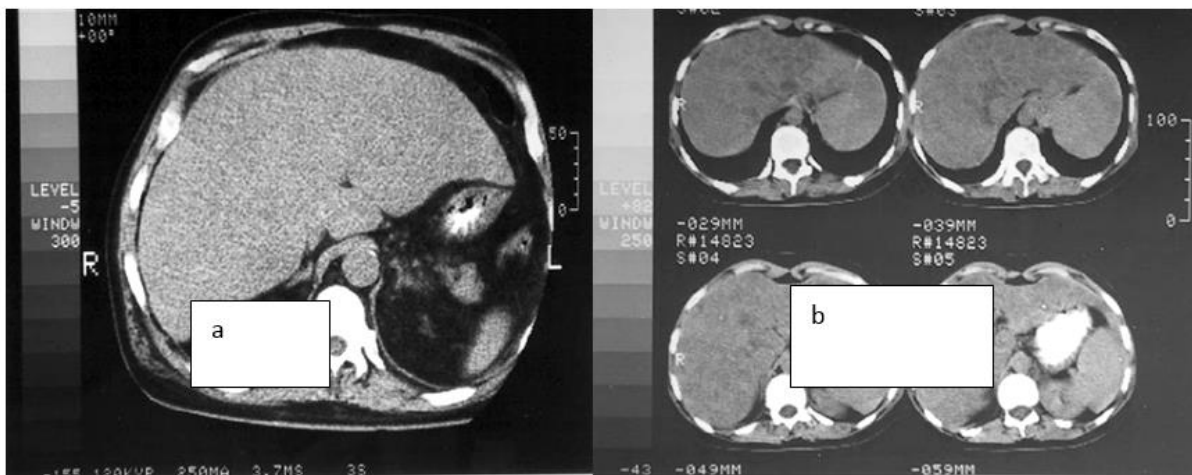
Functional state of the hepatobiliary system in chronic hepatitis

- a) HBSG. Histograms from the liver area and gallbladder. Decreased absorption-excretory functions of hepatocytes. Hypokinesia of the gallbladder (arrow).



- b) HBSG. Afunctional curve over the zone of the gall bubble (arrow).

CT semiotics of hepatitis



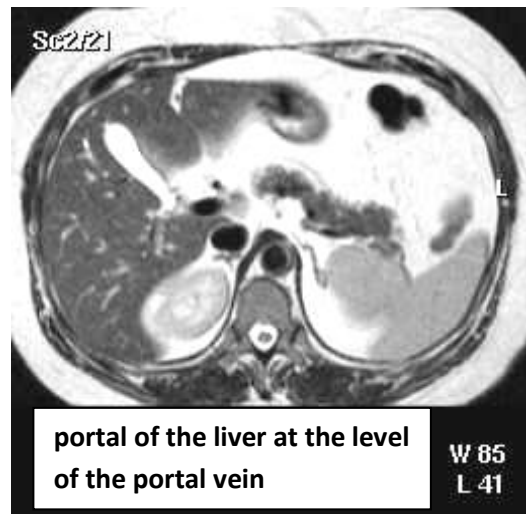
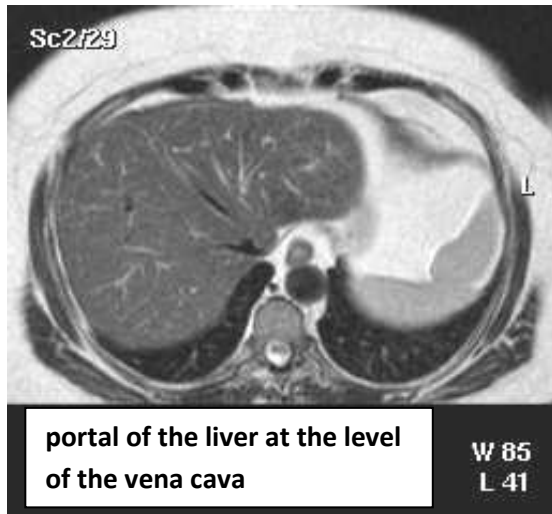
A) Toxic hepatitis.

Diffuse enlargement of the liver, the contours are even, clear, the parenchyma is homogeneous, the density of the parenchyma is reduced.

B) autoimmune hepatitis.

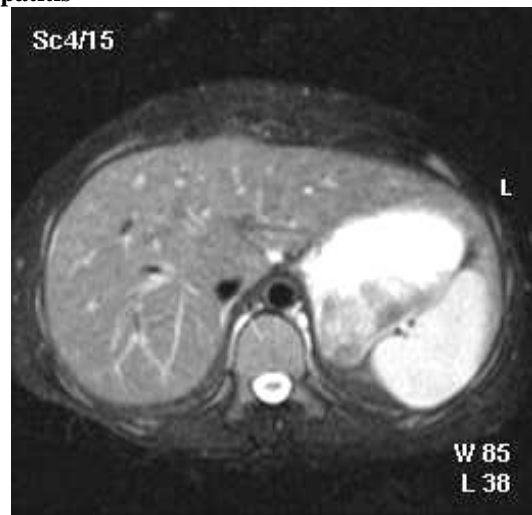
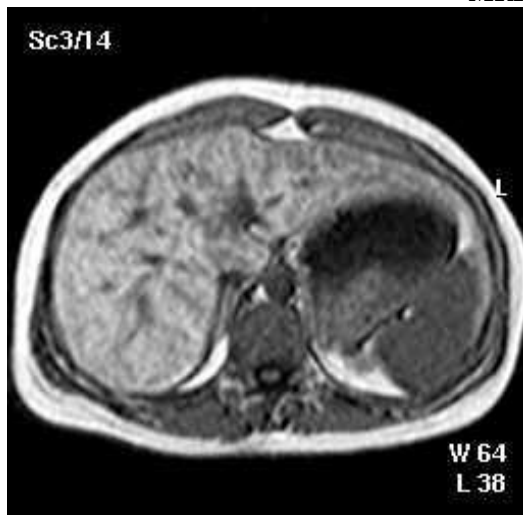
The liver is diffusely enlarged, its contours are even, the liver parenchyma is heterogeneous.

MRI - normal liver picture



- At T2 FWI, the liver has a low signal intensity.
- The liver has the shortest T1 time (short relaxation time) among the abdominal organs, thus appearing brighter (with signal intensity above skeletal muscle and spleen).
- The spleen at T2 VI has a higher signal intensity relative to the hepatic parenchyma.

MRI in chronic hepatitis

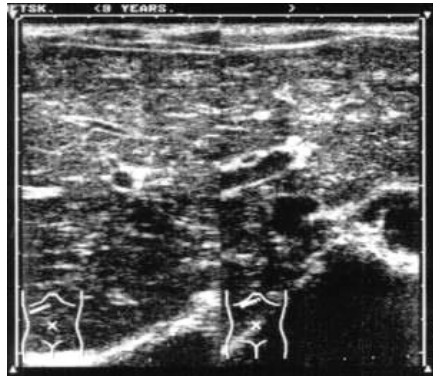

Chronic hepatitis. Diffuse enlargement of the liver, heterogeneity of the parenchyma, increased intensity of the signal from the parenchyma, the presence of separate hyperintense signals of small sizes, thickening of the vascular walls

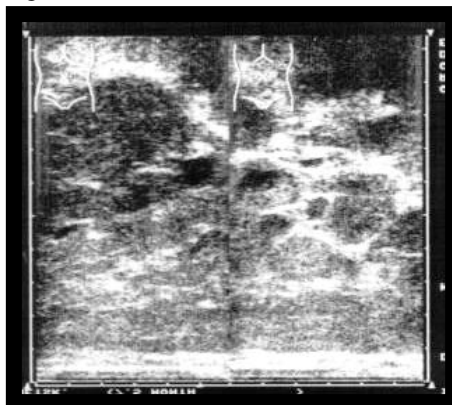
Ultrasound semiotics of liver cirrhosis

- Changing the size of the liver depending on the stage of cirrhosis
- Deformation of the organ, an increase in the ratio of the sizes of the caudate and right lobes
- Heterogeneity of the echostructure of the liver, coarse granularity, the presence of areas of regeneration (up to 2 cm in diameter)
- Roughness of the surface of the liver
- An increase in the diameter of the portal vein. Decrease in volumetric blood flow velocity (VBF) and increase in stagnation index (SI).
- Splenomegaly. Fluid in the abdominal cavity (transient and refractory ascites). Expansion of the splenic and portal veins - portal hypertension. Collaterals. Recanalization of the umbilical vein.

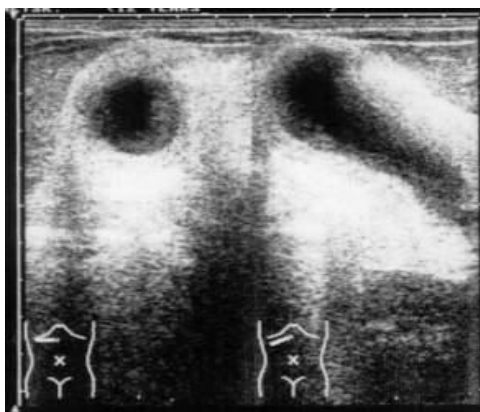
Ultrasound diagnosis of liver cirrhosis



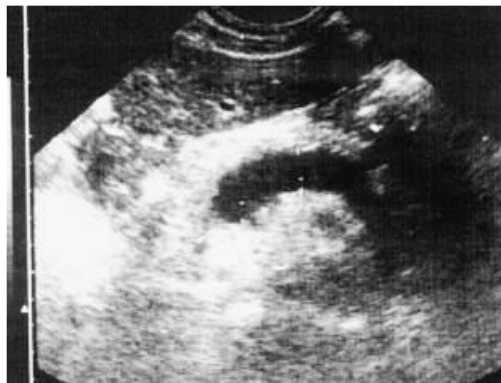Cirrhosis of the liver, the initial stage. Mosaic heterogeneity of parenchyma architectonics, compaction and thickening of the vascular walls. Longitudinal scan



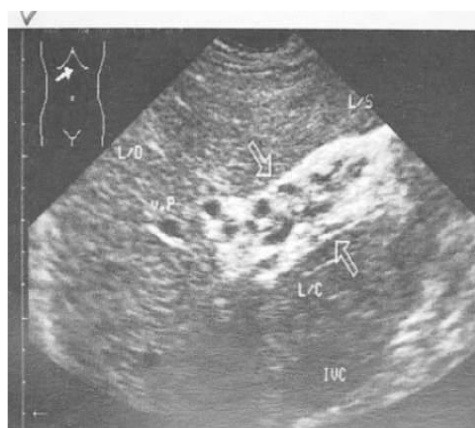Large-nodular cirrhosis of the liver. Large nodes in the parenchyma, proliferation of connective tissue. Longitudinal scan.



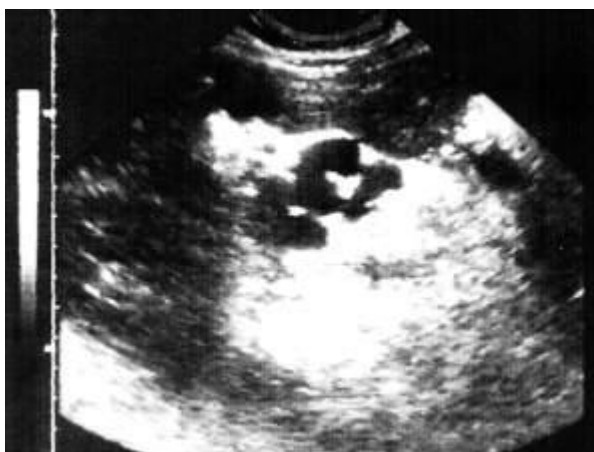Cirrhosis of the liver. portal hypertension. Sclerosis of the walls of the gallbladder.
Ultrasound diagnosis of portal hypertension
Decompensated portal hypertension in liver cirrhosis. Expansion of the portal vein.



Expansion of the splenic vein. Oblique scan in the epigastric region.

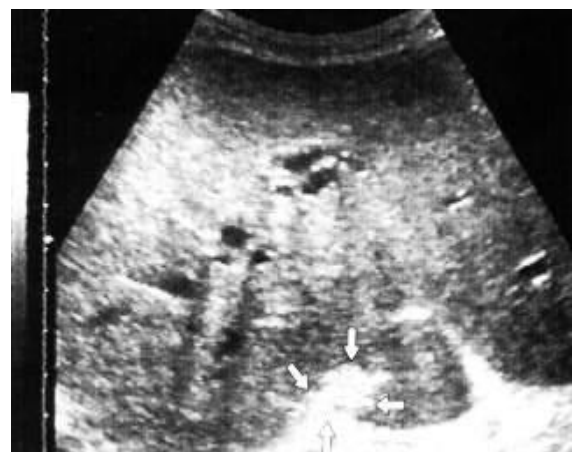

Porto-caval anastomoses in the hilum of the liver. Oblique scan along the costal arch.
Differential diagnosis of hepatic blood flow disorders



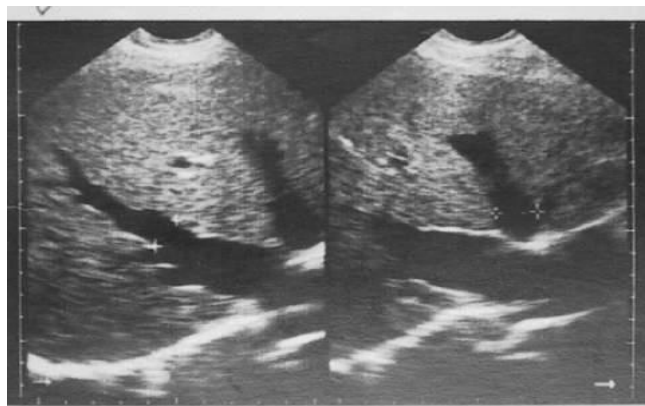
Первичный портальный фиброз.

Pronounced fibrosis and porto-portal
collaterals in the porta hepatis



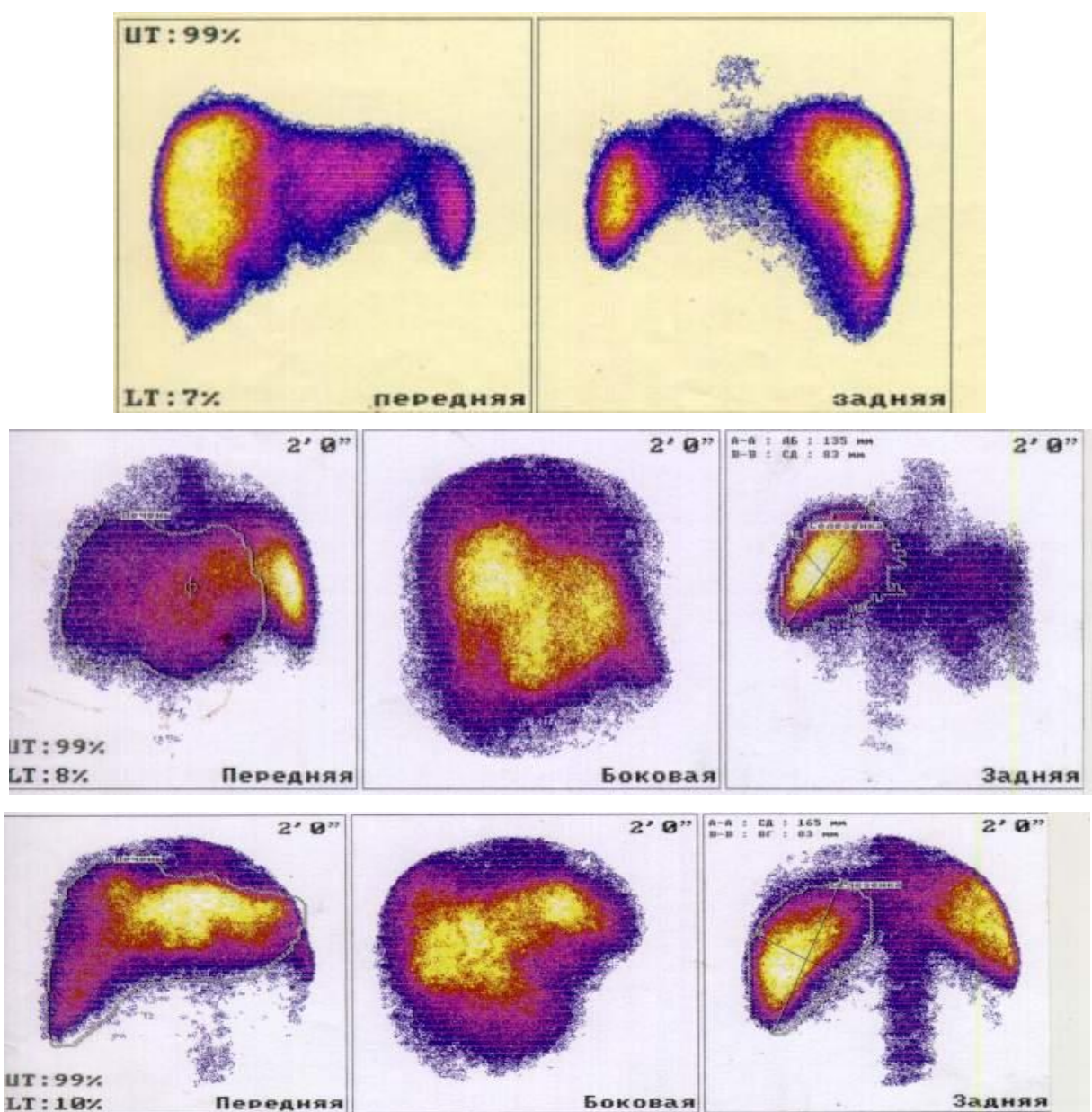
Синдром Бадда-Киари.

Obliteration of the inferior vena cava.
Endophlebitis of the hepatic veins.



Cardiac fibrosis of the liver. Deformation and expansion of the hepatic veins.

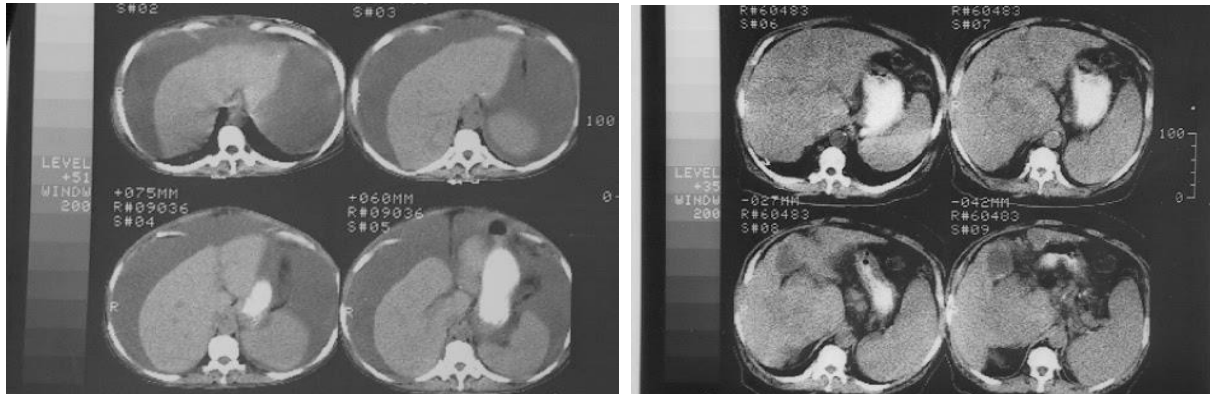
Radionuclide semiotics of liver cirrhosis



Повышение накопления радиоколлоида в селезенке, визуализация костей скелета.

- Deformation of the liver. Heterogeneity of radiopharmaceutical inclusion in the liver.
- A pronounced decrease in the function of macrophage and polygonal liver cells. cholestasis.
- Violation of intrahepatic hemodynamics.

CT semiotics of cirrhosis

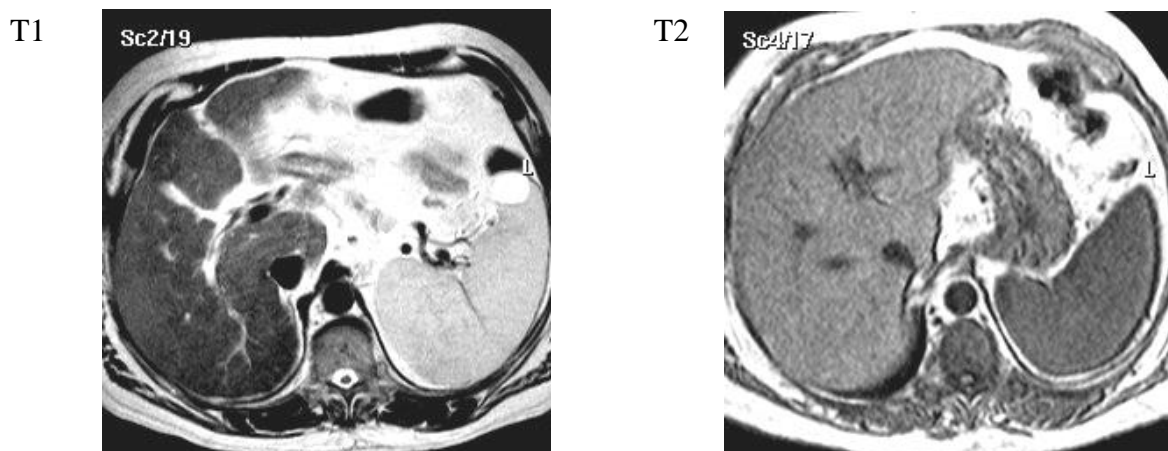


- Changing the size of the liver
- Deformation of the liver
- Relative increase in the size of the caudate lobe
- Roughness of the surface
- Heterogeneity of parenchymal density
- Enlargement of the spleen
- An increase in the diameter of the portal and splenic veins
- Free fluid in the abdominal cavity.

III. MRI semiotics of liver cirrhosis

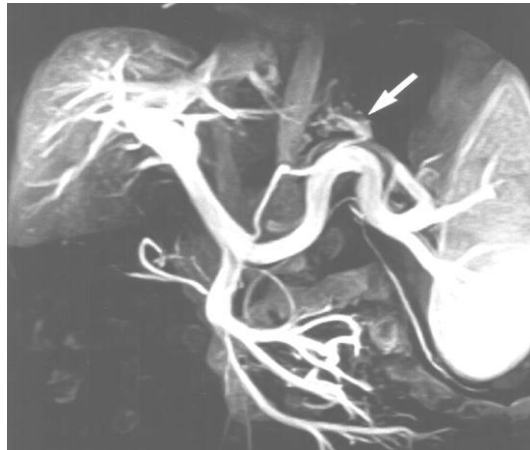
- Deformation of the liver
- Reduced signal intensity from the liver parenchyma
- Combination of hyperintensity on T1 and hypointensity on T2-WI during nodal regeneration
- The index of the ratio of the size of the caudate lobe to the right lobe is more than 0.65
- With contrast MRI - heterogeneity of the parenchyma
- Splenomegaly
- Expansion of the splenic vein and trunk of the portal vein, varicose veins of the stomach and esophagus with contrast MR angiography

Cirrhosis of the liver

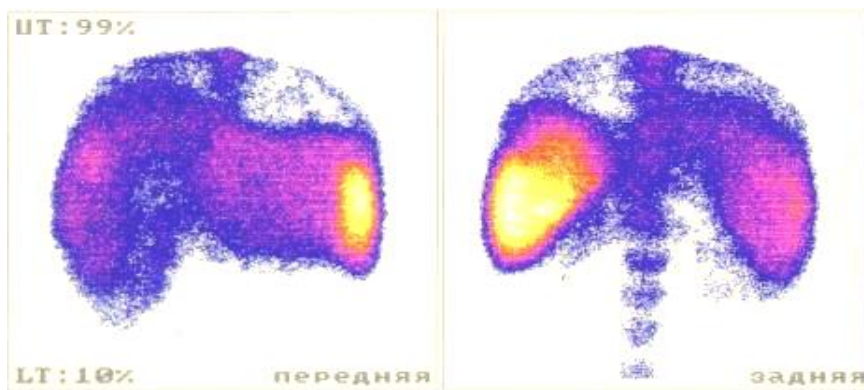
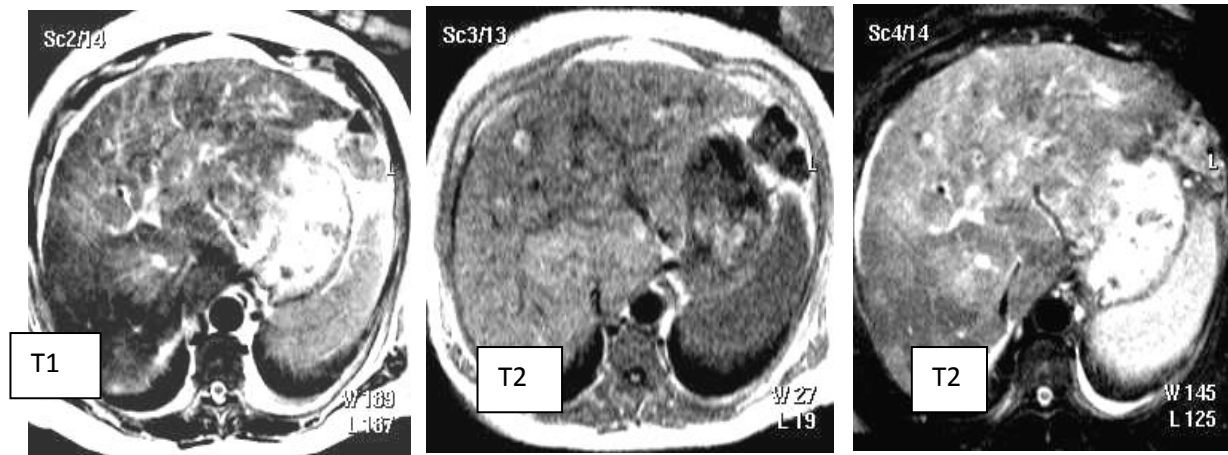


Cirrhosis of the liver . Deformation of the liver, an increase in the size of the caudate lobe, a decrease in the intensity of the signal from the parenchyma. Splenomegaly.

MR angiography.

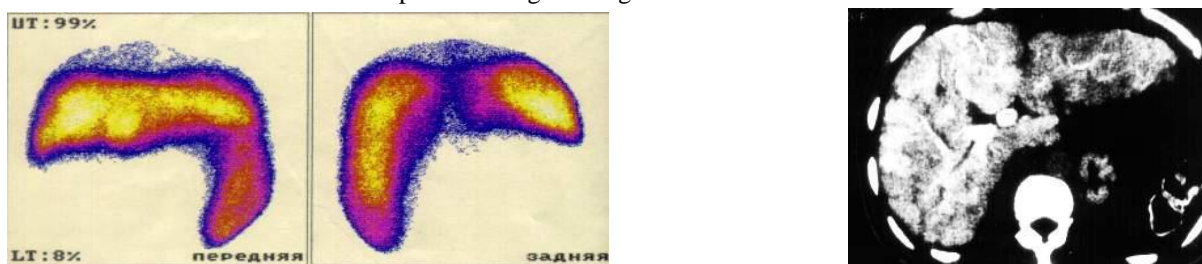


portal hypertension. Cirrhosis of the liver. Splenomegaly, gastric varices.



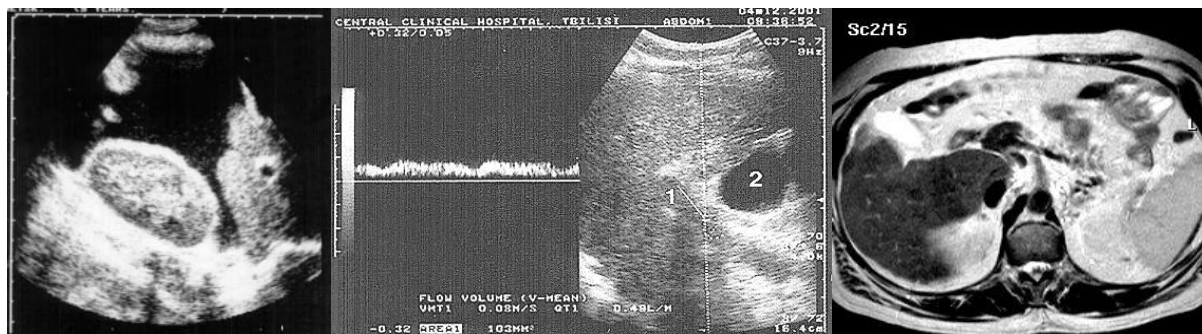
Against the background of severe hepatomegaly, MRI scans show well-distinguished tumor-like nodes of various sizes in the right and square lobes.

Complex radiological diagnosis of liver cirrhosis



HSG

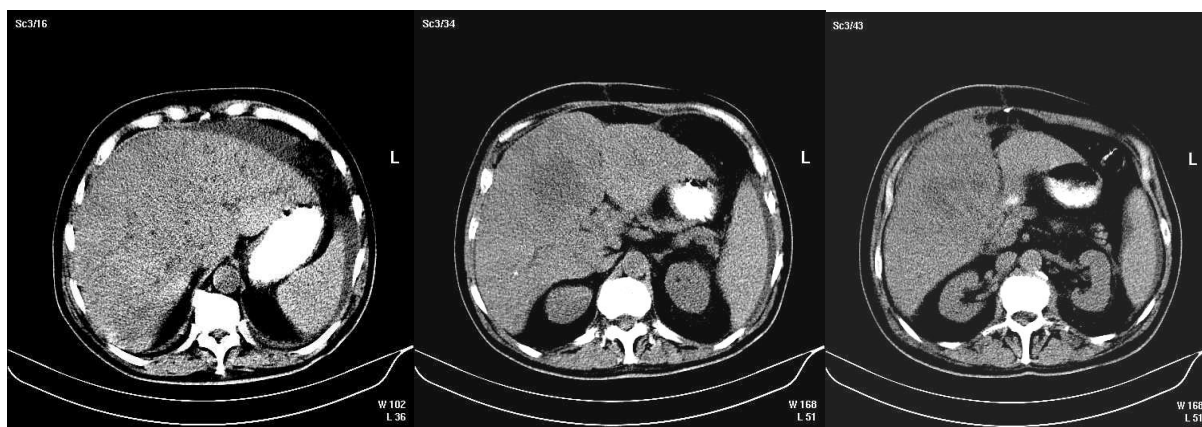CE



Sonogram

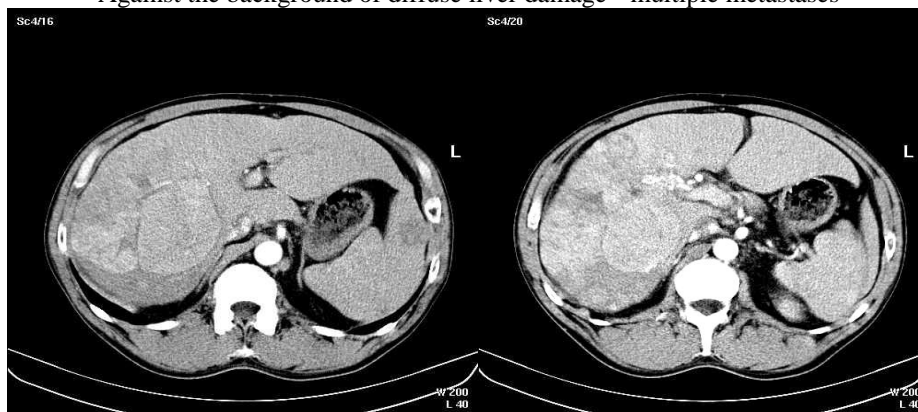Dopplerography of the portal vein

MRI

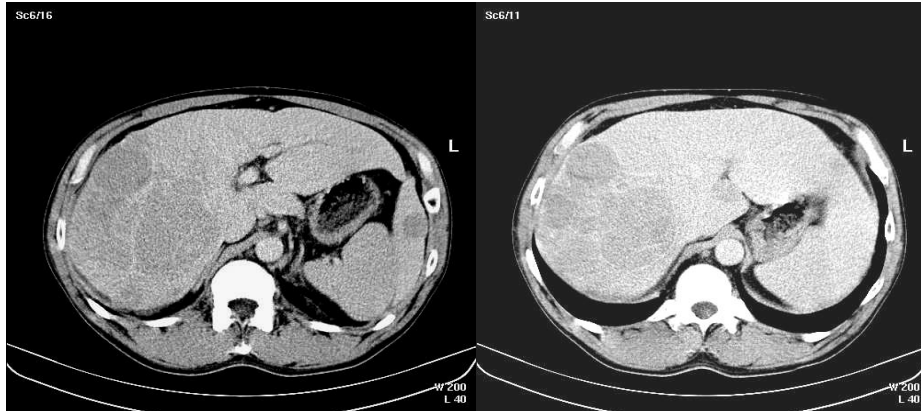


Differential diagnosis of diffuse focal lesions of the liver. MSCT

Against the background of diffuse liver damage - multiple metastases



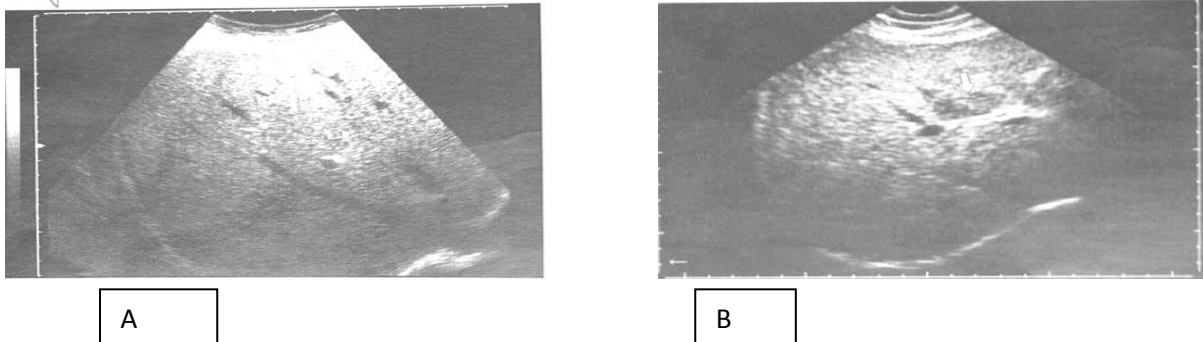
Spiral computed angiography (SCTA) for diffuse focal liver damage (hepatocellular cancer against the background of chronic hepatitis)



- SCTA.
- 1. Arterial phase.
- 2. Parenchymal phase
- 3. Venous phase.

Early accumulation of contrast in a hypervascular tumor of the right lobe.

Ultrasound semiotics of fatty liver degeneration



Diffuse form - dystrophic changes in almost the entire parenchyma.

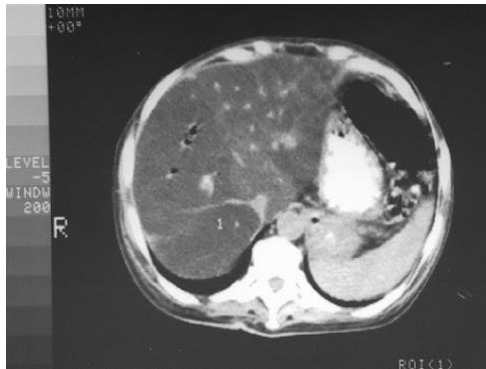Local - separate large areas of fatty infiltration (sometimes a whole share).

Focal - single areas of fatty infiltration.

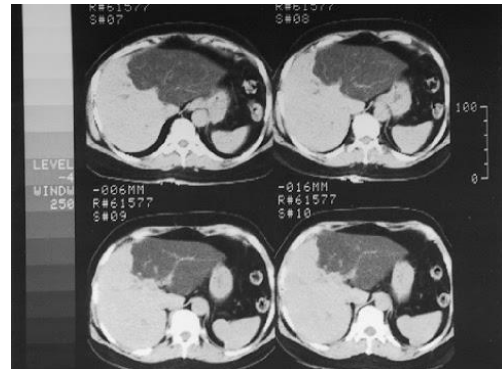
A) Fatty infiltration of the liver. Increased echogenicity of the parenchyma with the effect of weakening in the deep sections of the liver.

B) Diffuse form of fatty infiltration of the liver with a hypoechoic area of unchanged tissue in the region of the portal of the liver (arrow).

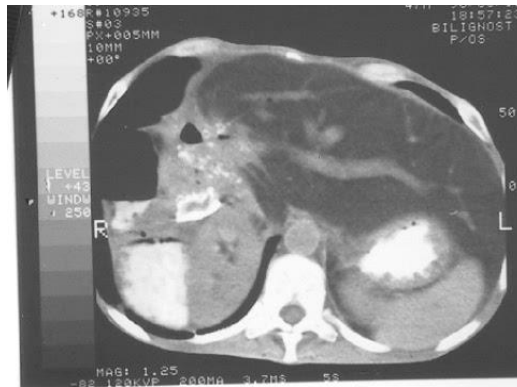CT diagnostics of fatty degeneration of the liver



Fatty degeneration of the liver. The liver is homogeneous, the density is reduced to 10 units. The hepatic veins are seen as denser cords against the background of the liver parenchyma.

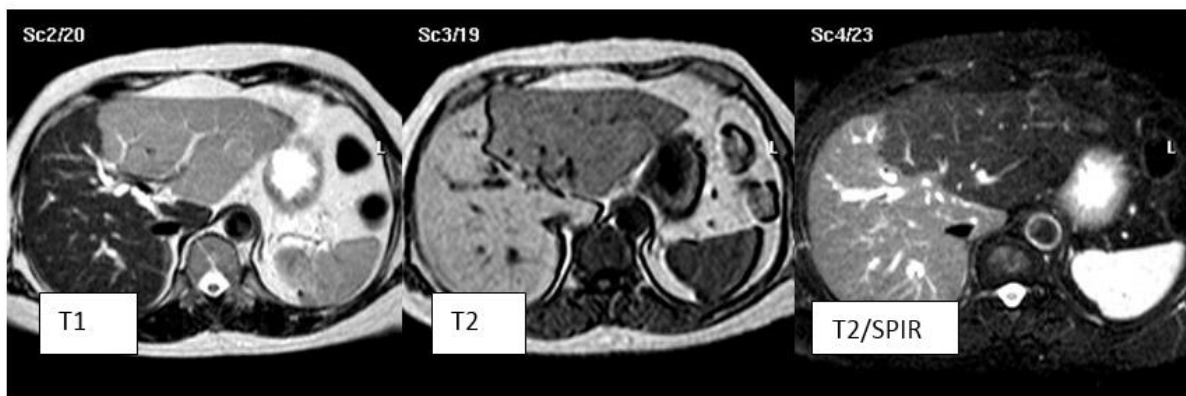

Fatty degeneration of the left lobe of the liver (increase in proportion, density reduced). Local form.



Condition after resection of the right lobe. Fatty degeneration of the liver.

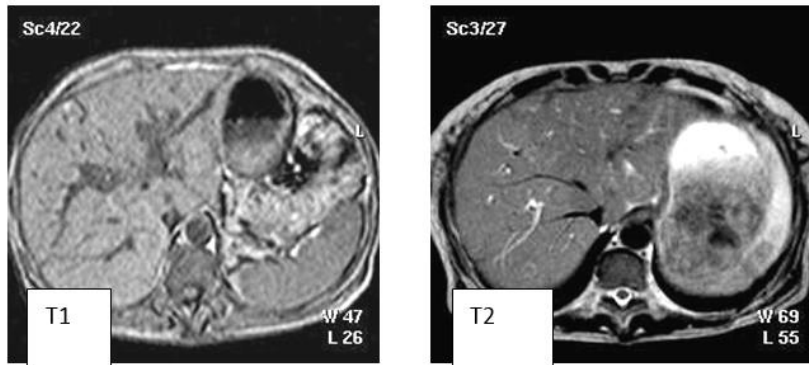
MRI for fatty degeneration of the liver



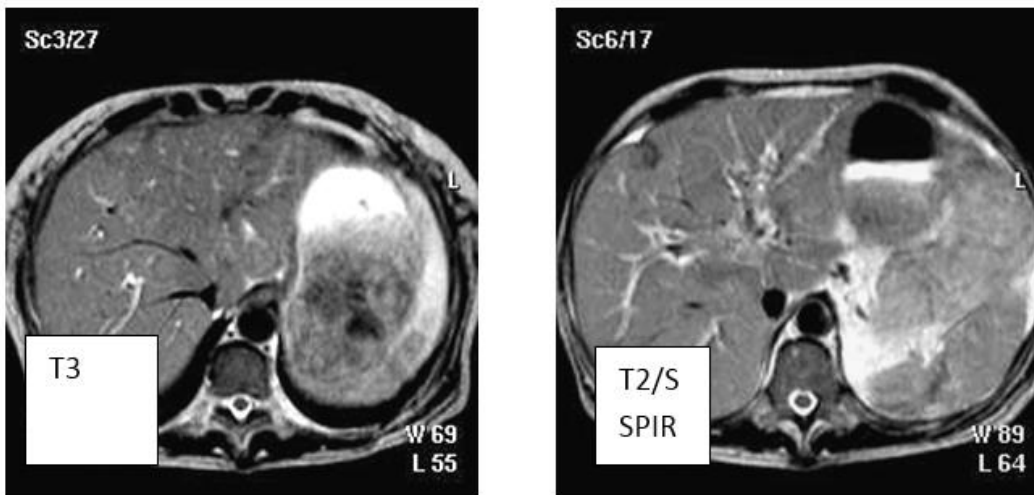
Fatty degeneration of the liver. local form. A significant increase in the signal from the tissue of the left lobe. Depletion of the vascular pattern, enlargement of the left lobe, heterogeneity of the parenchyma.

MRI for fatty degeneration of the liver

Increase in signal intensity on T2 and T1



Impoverishment of the vascular pattern, an increase in the size of the liver, some heterogeneity of the parenchyma with hyperintense point inclusions.



IV. Conclusion.

Radiation methods have great diagnostic capabilities in identifying the characteristic semiotics of diffuse liver lesions, they can determine the nature and stage of the disease, complications, cirrhotic transformation, the degree of hemodynamic disturbance, and regeneration processes.

In the diagnosis of liver cirrhosis, ultrasound is the most informative (DG parameters - volumetric blood flow velocity and stagnation index).

Highly specific tests:

- reducing the size of the liver; increase in the diameter of the portal vein;
- increase in the ratio of the caudate and right lobes;
- heterogeneity of the structure of the liver; surface roughness;
- fluid in the abdomen

CT and MRI significantly complement diagnostic information when detecting fatty degeneration, early signs of malignancy, processes regeneration and stages of diffuse liver disease. Radionuclide studies objectively assess hepatic hemodynamics, the functional state of the macrophage and hepatobiliary systems, opening up additional possibilities for diagnosis and differentiated therapy in chronic hepatitis and cirrhosis.

Literature.

- [1]. Evaluation of Abnormal Liver Chemis. The American Journal of Gastroenterology, 20 Dec 2016, 112(1):18-35. DOI: 10.1038/ajg.2016.517 PMID: 27995906.
- [2]. Evaluation of Abnormal Liver Chemis. Am J Gastroenterol 2017; 112:18-35; doi: 10.1038/ajg.2016.517; published online 20 December 2016. 1Division of Gastroenterology/Hepatology.
- [3]. Am J Gastroenterol 2017; 112:18-35; doi:10.1038/ajg.2016.517; published online 20 December 2016. Abstract.
- [4]. 2022 Volume 7 - Ukrainian Journal of Medicine, Biology and Sports

- [5]. Kwo PY, Cohen SM, Lim JK. ACG Clinical Guideline: Evaluation of Abnormal Liver Chemistries. *Am J Gastroenterol.* Jan 2017;112(1):18-35
- [6]. Chirsky V.S. Biopsy diagnosis of non-tumor diseases of the liver / Ed. V.S. Chirsky; ed. N.M. Khmelitsky.-SPb.:SPbMAPO, 2009.-80 p.
- [7]. Yakubchik, T.N. Clinical gastroenterology: a manual for students of medical, pediatric, medical and psychological faculties, interns, clinical residents, gastroenterologists and therapists / T.N. Yakubchik. - 3rd ed., add. and reworked. - Grodno: GrGMU, 2014. - 324 p. Oncology, ed. Chissova V. I., Daryalova S. L. - M.: GEOTAR-Media, 2007. - 560 p.
- [8]. Podymova S. D. "Liver Diseases: A Guide" - OJSC "Publishing House "Medicine", 2005. — 768 p. ISBN 5-225-04106-X.

Sokolov V.N, et. al." Complex Imaging Diagnosis of Diffuse Liver Lesion." *IOSR Journal of Dental and Medical Sciences (IOSR-JDMS)* 22(4), 2023, pp. 56-70.