

Conjunctival Nevus: A Case Report

Lakshmi Prasanna Peruri, Anees Fathima

(Sankara Eye Hospital, Guntur, Andhra Pradesh, India)

Abstract: Conjunctival nevi are the most common benign melanocytic tumor of the ocular surface with a mean diameter of 3.5mm. Large nevi with a basal diameter of more than 10 mm in diameter called giant conjunctival nevi (GCN) are rare and account for 5% of conjunctival nevi.

A 10 year old male presented with a pigmented spot in left eye which was there since 7 years, with a history of rapid growth in last 6 months.

AS-OCT suggestive of hyper refractive nodular, temporal ocular surface lesion and base of the lesion was well defined with no evidence of intra lesional cysts.

Excision biopsy was done with application of cryotherapy to the clear margins of the excised lesion and Amniotic membrane grafting was done. Histopathology reports suggestive of sharply circumscribed but asymmetrical lesion involving both, the epithelium and substantia propria. The lesion is melanocytic proliferation with maturation sequence maintained in past and lost elsewhere, features suggestive of atypical nevus.

Young children with conjunctival nevi with no ocular or systemic risk factors can be observed with emphasis on periodic evaluation. Periodic follow up is essential, considering the rare but definite risk of malignant transformation.

Date of Submission: 24-02-2023

Date of Acceptance: 05-03-2023

I. Introduction

Conjunctival nevi are the most common benign melanocytic tumor of the ocular surface with a mean diameter of 3.5mm. Large nevi with a basal diameter of more than 10 mm

in diameter called giant conjunctival nevi (GCN) are rare and account for 5% of conjunctival nevi.^[1] Large conjunctival nevi can cause further diagnostic and differential diagnostic difficulties as they can be confused with malignant melanoma or in amelanotic cases with lymphangioma.

II. Case Report

A 10 year old male presented with pigmented spot at limbus in left eye. The lesion was noticed by the parents when the child was 3 years old as fleshy spot on the conjunctiva. The lesion remained unchanged until approximately 6 months before recent admission, during these months there is a considerable increase in the size of the lesion with pigmentation and elevation.

Gross examination reveals ocular surface tissue lesion measuring 11*7mm.

The mucosal surface shows an elevated, pigmented nodular lesion in the left eye measuring around 6*4mm adjoining the temporal limbus extending from 2 to 4 o'clock position.

AS-OCT suggestive of hyper refractive nodular, temporal ocular surface lesion, base of the lesion was well defined with no evidence of intra lesional cysts.

UBM: UBM imaging of left eye suggesting corneal scleral involvement of lesion with out involvement of angle structures.

Systemic examinations were normal.

MANAGEMENT:

As there is significant increase in size of the lesion, surgical excision biopsy of the lesion was planned after obtaining consent. Surgical excision of the lesion was done with 4mm clear margins of conjunctiva and cryotherapy was applied to the excised margins and Amniotic membrane grafting was done.

Histopathological examination of the lesion reveals, multiple sections showing conjunctival tissue displaying a sharply circumscribed but asymmetrical lesion involving both, the epithelium and substantia propria. The lesion is melanocytic proliferation with maturation sequence maintained in past and lost elsewhere. The lesion is composed of nests of round spindle shaped to ovoid nevoid cells with relatively uniform nuclei. In other part the deeper nests display nuclear atypia with presence of large vesicular nuclei having prominent

nucleoli and displaying nuclear membrane irregularities. Some are hyperchromatic. Many cells in both population contain granular, intracytoplasmic melanin pigment, features suggestive of atypical nevus.

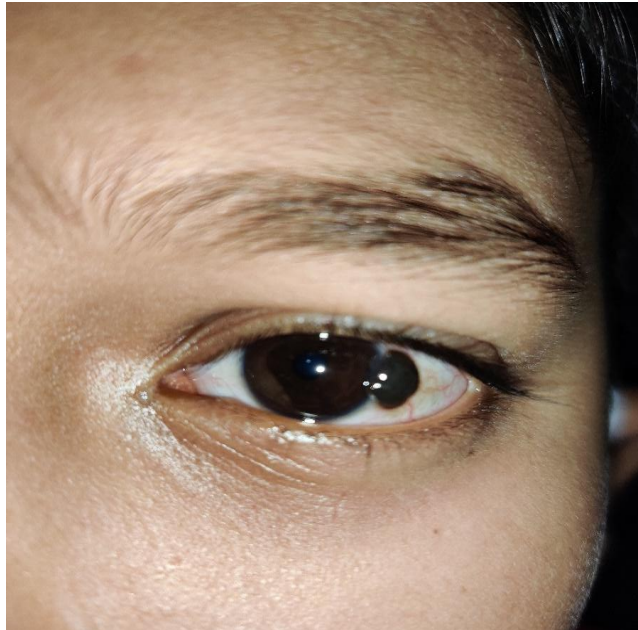


Fig 1: clinical photograph showing elevated, pigmented, nodular lesion at 2 to 4 o'clock region in left eye

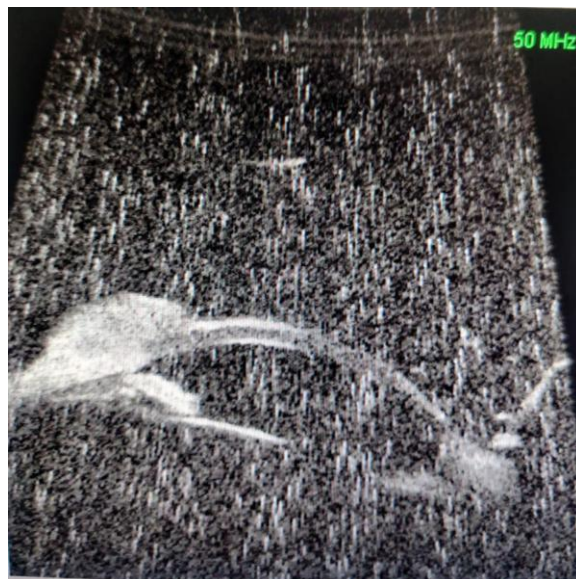

Fig 2: UBM imaging of left eye suggesting corneo scleral involvement of lesion without involvement of angle structures.

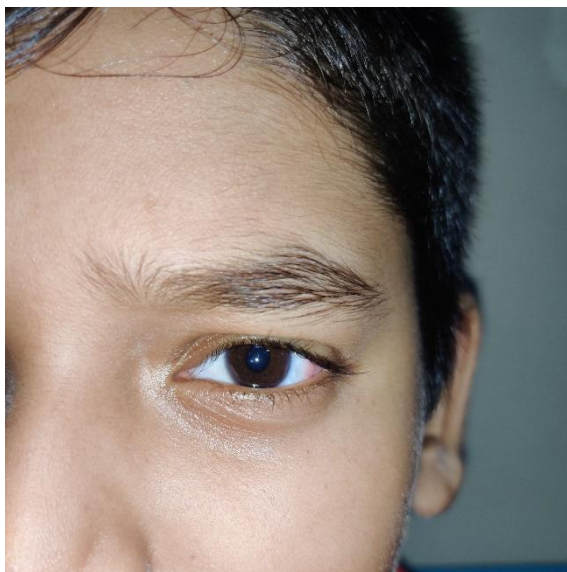


Fig 3: post operative image of left eye

III. Discussion:

Conjunctival nevi are the most common benign melanocytic tumor of the ocular surface with a mean diameter of 3.5mm, they can be present at birth or can develop at a later stage. They are similar in presentation to giant conjunctival nevi as both have cystic spaces and variable pigmentation, but differ in their size and non-diffuse nature. Both can be usually observed as the risk of malignant transformation is less than 1% in conjunctival nevi and 4% in GCN.^[1] In children, change in both pigmentation and size have been associated with hormonal fluctuations^[2] and hence can be observed with emphasis on periodic review. However, even in this age group, considering the rare but definite risk of melanoma arising from nevi,^[1] it may be prudent to interpret unexplained change in size or pigmentation with caution and when in doubt consider surgical excision. For localized lesions complete excision is usually possible unlike in GCN. Limbal stem cell deficiency in lesions proximal to limbus and conjunctival scarring following excision are definite concerns. Surface reconstruction with amniotic membrane grafting can help in these cases.^[2,3] In some patients, cryotherapy has been combined with excision.^[2] Recurrence is rare.^[1]

Among the pigmented lesions, conjunctival melanoma and primary acquired melanosis (PAM) may be considered in the differential diagnosis, but each has its distinct clinical and ASOCT features. In general, cystic spaces indicate chronicity and are quite often seen in conjunctival nevi on clinical examination. Shields *et al.* noticed this in 78% of cases on ASOCT.^[1] PAM occurs in middle age, is flat and the pigmentation is usually epithelial. Cystic spaces are not seen. Melanoma is usually thicker with an age of onset usually in slightly older patients. Pigmentation in melanoma is mostly within the stroma.^[4] Cystic spaces are usually absent and can rarely be seen in melanomas arising from nevi.^[5] In older age, increase in thickness/enlargement in size and/or change in pigmentation is usually suspicious of a malignant change and needs excision with histopathological analysis of the specimen.

IV. Conclusion:

Young children with conjunctival nevi with no ocular or systemic risk factors can be observed with emphasis on periodic evaluation. In this age group suspicious lesions may need early surgical intervention and histopathological confirmation. Periodic follow up is essential, considering the rare but definite risk of malignant transformation.

Conflicts of interest

There are no conflicts of interest.

References

- [1]. Shields CL, Regillo AC, Mellen PL, Kaliki S, Lally SE, Shields JA. Giant conjunctival nevus: Clinical features and natural course in 32 cases. *JAMA Ophthalmol* 2013;131:857- 63.
- [2]. Tóth- Molnár E, Vizvári E, Skribek Á, Vörös A. Giant conjunctival nevus in a 12- year- old child. *Case Rep Ophthalmol Med* 2017;2017:8414352. doi: 10.1155/2017/8414352.
- [3]. Tomita M, Goto H, Muramatsu R, Usui M. Treatment of large conjunctival nevus by resection and reconstruction using amniotic membrane. *Graefes Arch Clin Exp Ophthalmol* 2006;244:761- 4.

- [4]. Shields CL, Fasiuddin AF, Mashayekhi A, Shields JA. Conjunctivalnevi: Clinical features and natural course in 410 consecutivopatients. Arch Ophthalmol 2004;122:167- 75.
- [5]. Esposito E, Zoroquiain P, Mastromonaco C, Morales MC,Belfort Neto R, Burnier M Jr. Epithelial inclusion cyst inconjunctival melanoma. Int J Surg Pathol 2016;24:562- 67.

Lakshmi Prasanna Peruri, et. al. "Conjunctival Nevus: A Case Report." *IOSR Journal of Dental and Medical Sciences (IOSR-JDMS)*, 22(3), 2023, pp. 15-18.