

# The Adjunctive Use of Autologous Adipose Tissue in Alveolar Cleft Grafting: A Case Report

Marwa A. Alkassaby<sup>1</sup>, Karim Tarek<sup>2</sup>, Mahmoud Yehia<sup>3</sup>, Yasser N. Alhadidy<sup>4</sup>

<sup>1</sup>(Professor and head of oral and maxillofacial surgery department, faculty of dentistry/ Ainshams university, Egypt)

<sup>2</sup>(oral and maxillofacial surgery department, faculty of dentistry/ Ainshams university, Egypt)

<sup>3</sup>(Lecturer of oral and maxillofacial surgery, faculty of dentistry/ Ainshams university, Egypt)

<sup>4</sup>(Lecturer of oral and maxillofacial surgery, faculty of dentistry/ Ainshams university, Egypt)

## Abstract:

**Background:** The incidence of cleft lip and palate (CLP), which affects 1 in 700 newborns, makes it one of the most prevalent congenital defects. Alveolar cleft defect (AC) is a frequent aberration linked with CLP that is treated with gingivoperiosteoplasty (GPP) or alveolar cleft grafting (ACG), allowing the restoration of arch continuity and stabilisation of the bony segments. There are a number of indications for the repair of the AC, including inadequate support for the erupting teeth at the cleft site, insufficient bone stock for implant insertion, food and fluid escape from oronasal fistula, insufficient alar support, and hypernasality of speech.

**Materials and Methods:** The Cleft Care Center (CCC) affiliated with the Department of Oral and Maxillofacial Surgery, Faculty of Dentistry, Ain Shams University, Cairo, Egypt, operated on a patient with unilateral AC

**Conclusion:** Dermal fat grafting can be used as an adjunctive biological barrier membrane to decrease the ONF, increase the success rate of ABG through assessment of bone fill both in 2D as well as in 3D.

**Key Word:** Cleft alveolus, alveolar cleft grafting, dermal fat grafting

Date of Submission: 14-03-2023

Date of Acceptance: 30-03-2023

## I. Introduction

The incidence of cleft lip and palate (CLP), which affects 1 in 700 newborns, makes it one of the most prevalent congenital defects<sup>(1)</sup>. Alveolar cleft defect (AC) is a frequent aberration linked with CLP that is treated with gingivoperiosteoplasty (GPP) or alveolar cleft grafting (ACG), allowing the restoration of arch continuity and stabilisation of the bony segments. There are a number of indications for the repair of the AC, including inadequate support for the erupting teeth at the cleft site, insufficient bone stock for implant insertion, food and fluid escape from oronasal fistula, insufficient alar support, and hypernasality of speech<sup>(3)</sup>. ACG has historically employed a variety of graft materials, but autogenous iliac bone graft is now regarded as the industry standard. Allogenic and xenograft grafts may have certain advantages, such as reducing the length of surgery and the morbidity at the donor site, but they lack the osteogenic qualities of autogenous bone<sup>(4)</sup>. Certain preparations, such as Plasma rich in growth factors (PRGF), Platelet rich plasma (PRP), and Plasma rich fibrin (PRF)<sup>(5)</sup>, were added to either allografts or xenografts; nonetheless, in every comparison, the autogenous bone was superior. Fat tissue is currently considered a gold standard soft tissue graft material. Coleman et al. claimed that fat graft is biocompatible, autologous in nature, integrate with donor tissues with least complication. Those properties in addition to stem cell abundance attracted our team to assess the effect of using dermal fat graft as a barrier membrane over the grafted bone instead of other allograftic or alloplastic barrier materials.<sup>(6)</sup>

## II. Material And Methods

The Cleft Care Center (CCC) affiliated with the Department of Oral and Maxillofacial Surgery, Faculty of Dentistry, Ain Shams University, Cairo, Egypt, operated on, a patient with unilateral AC.

**Study Design:** Case report.

**Study Location:** Cleft care center, department of oral and maxillofacial surgery, ainshams university.

**Inclusion criteria:**

- Patients having age range of 8-15 years old.
- Patients eligible for 2ry alveolar cleft grafting using adipose fat graft in conjunction with ABG.
- Boys or girls.
- Unilateral cleft alveolus.
- Cleft lip and primary palate with or without secondary palate

- Sufficient transverse maxillary width was present before surgery.
- No history of previous ACG operations
- Good oral hygiene
- Non-syndromic CLP patients
- Good general condition
- Free from any diseases affecting bone formation

### **Procedure methodology**

Although our study is a retrospective study, but we'll be discussing the surgical procedures for better presentation of the proposed technique.

#### 1. Anesthesia and patient preparation:

The patient was placed in supine position on the operating table. General anesthesia was administered through Nasotracheal intubation. A cannula was inserted in a peripheral vein (18G) and normal saline infusion started at a rate of 6 ml/kg before induction of the anesthesia and was continued during surgery along with the Ringer's solution\*. The induction of the anesthesia with IV Propofol 1.5-2 mg/kg, Fentanyl 1.3 µ/kg and Succinyl choline 1mg/kg was done to enable nasotracheal intubation. The maintenance of anesthesia was achieved using Isoflurane in Oxygen and Atracurium in a dose of 0.3-0.6 mg/kg.

Overextension of the neck and support using wrapped sandbags was done. A small sandbag was also placed under the gluteal region, to lift the iliac wing away from the operating table. Preparation of the surgical sites with Povidone Iodine and then draping was achieved according to the standard oral and maxillofacial surgery operating procedures. The patient was also draped to allow exposure of the whole extent of the iliac wing.

At the beginning of the procedure a dose of 500-1000 mg Cefotaxime was administered as an antibiotic according to weight 50mg/Kg body weight followed by the administration of Dexamethasone Phosphate (as sodium salt) 4-8 mg through peripheral IV route. Epinephrine (1:200,000) was freshly prepared then infiltrated using 30-gauge needles within the planned surgical field to provide hemostasis.

#### 2. Surgical technique:

There were two surgical teams operating simultaneously to minimize the time of the operation and to minimize the cost.

##### a. Alveolar cleft site preparation:

Performed by the first surgical team. This preparation included the creation of a pyramidal defect for ACG, based on the technique described by Morselli et al. <sup>(8)</sup> The cleft area was exposed widely through incisions within the cleft edges. Then flaps were designed and raised to reconstruct the nasal floor, palatal wall of the defect, attached gingiva and the labial mucosa sufficiently.

##### i. Labial side preparation:

A sulcular incision using a number 15 Bard Parker blade was performed on both labial sides of the alveolar cleft, followed by papilla sparing sulcular incisions which is extended posteriorly to the first permanent molar tooth on both sides, with vertical releasing incisions anteriorly, made within the cleft edges separating the oral and nasal mucosal layers.

The width of the flap was at least two times the width of the alveolar cleft. In bilateral cleft lip and palate (BCLP) cases, it was critically important to preserve the mucoperiosteum over the premaxilla to prevent disrupting its blood supply, since this section is the primary vascular source. Thus, minimal mucoperiosteal elevation was performed on the edges of the labial surface of the premaxilla.

In addition, dissection between the labial flaps and the nasal mucosa within the area of the alveolar cleft increased coverage. This dissection was carried out with a combination of blunt and sharp dissection directed to expose the anterior nasal spine using Metzanbaum and Iris scissors.

##### ii. Palatal side preparation:

A palatal sulcular incision was made on each side of the alveolar cleft reaching at least two teeth mesial and distal to the defect. The palatal mucoperiosteal flaps were reflected caudally with simultaneous dissection between the nasal mucosa and the palatal mucosa.

Once the palatal flaps were separated from the nasal mucosa, these flaps were sutured (using 4-0 Polyglycolic Acid suture with cutting needle.) together in interrupted manner (knot towards the oral cavity). Hence providing the palatal wall of the pyramidal defect.

##### iii. Nasal side preparation:

The nasal mucosa was reflected cranially to reconstruct the nasal floor and ONF was closed if present. (Using 5-0 Polyglycolic Acid suture with round needle.)

Methylene blue dye was injected from the nose to ensure watertight closure of the nasal layer in the alveolar cleft region before the graft placement.

b. Bone Harvesting:

The second team performed harvesting simultaneously with the alveolar cleft site preparation. Autogenous cancellous bone chips from the anterior iliac crest (AIC) were harvested via an open approach which is the “Medial Cortico-cancellous Approach”.<sup>(9)</sup>

Prior to the incision, injection of Bupivacaine Hydrochloride Local Anesthetic with vasoconstrictor subcutaneously was done.

A slight medial pull was done using the hand placed on the iliac fossa to elevate the skin over the iliac bone crest. The assistant role was pulling the skin during making the incision medially, thus making the scar beneath the iliac crest prominence and thus below the belt level for trousers and skirts. This was to prevent future irritation of the scar.

Incision was made initially over the AIC and extended to the deep fascia, which eventually was incised.

The wide musculofascial attachment of the abdominal wall muscles to the iliac crest was delineated and any fatty covering should be removed and cleared to allow better exposure of the attachment of this fascia.

The Periosteal incision was made between the External abdominal oblique and Tensor Fascia Lata muscles. Elevation of the External abdominal oblique abdominal muscle together with the Transversus Abdominus was achieved and reflected to the medial crest edge, while leaving the Tensor Fascia Lata muscle intact without elevation; to avoid any gait disturbance.

At this point, a periosteal elevator was turned downward to reflect the Iliacus muscle to a length of 5 cm and a Tessier retractor is placed to expose the entire medial cortex.

The osteotomies were then outlined in the medial cortex to correspond to the dimensions of the recipient site

The anterior vertical osteotomy was placed 2cm posterior to the Anterior Superior Iliac Spine; to avoid injury to the Inguinal Ligament and fracture of the Sartorius muscle attachment at the fossa beneath the Anterior Superior Spine. Then superior horizontal, inferior horizontal and the posterior vertical osteotomies were done to yield a cortico-cancellous block and to expose the cancellous marrow.

Bone gouges were used in a rotating rest manner to remove large particles of cancellous marrows, then bone curettes were used to harvest the remaining cancellous marrow which is stored in a solution consisting of 0.9% Sodium Chloride isotonic solution in addition to Gentamicin antibiotic.

The Cortico-cancellous block was scrapped using a disposable bone scrapper for removal of the cancellous part to facilitate the use of the cortex above the cancellous graft in the cleft area.

The cancellous bone was placed and compressed in a plastic syringe to calculate the total volume of bone and to aid in the handling and placement of the graft into the recipient alveolar cleft site.

In the group of patients operated from 2018, fat from the subcutaneous tissue at the incision margin was dissected freely to be placed in the recipient site above the graft composed of cancellous part filling the defect and cortex covering the defect and fixated with self-drilling mini screws as a barrier membrane before the closure of the mucoperiosteal flaps.

c. Graft insertion:

Drilling of bur holes in the available bone bordering the recipient site was done using surgical round burs (size 2-3) and irrigation using 0.9% Sodium Chloride isotonic solution to accelerate healing and graft incorporation (Regional Acceleratory Phenomenon) which is an important step Before the insertion of the graft in the donor site.

Packing of the cancellous graft into the prepared alveolar clefts sites against the reconstructed nasal floor was done until slight overfilling was accomplished.

The cortex was then placed as an on lay graft and fixed in the bone adjacent to the cleft site by 1-2 self-drilling screws (2.0mm diameter and 5-7mm length). Then the fat graft was placed over the bone graft.

The recipient site received an additional 2cc of adipose tissue used as a barrier membrane above the grafted site before the flap closure. (Figure 1)

d. Donor site closure:

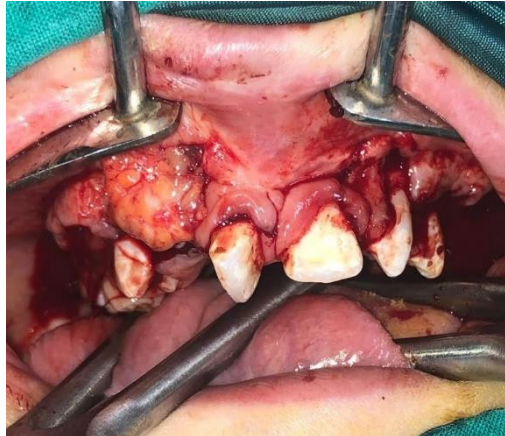
1. Hemostasis was achieved by cauterization and local hemostatic measures as bone wax and/or gel foam packing.

2. Closure of the muscular layer by 4-0 Braided Polyglycolic Acid sutures followed by suturing the fascial and subcutaneous layers.

3. Finally, skin closure was achieved by 5-0 blue Poly-Propylene suture on a cutting needle in subcuticular manner.

e. Recipient site closure:

The gingival mucoperiosteal flaps were sutured in advanced position medially to cover the graft using 4-0 – 5-0 Braided Polyglycolic Acid2 suture on a round needle in an interrupted manner.



**Figure 1 : Adipose Tissue application after grafting**

### **Statistical analysis**

The bone volume is considered continuous data, the student's T-test for independent sample was used to evaluate statistical significance.

The Bergland Scale results was considered discrete data, so the results for both groups were tabulated and statistically analyzed using chi-square test.

The ONF and the occurrence of dehiscence was considered discrete data, so results was tabulated and statistically analyzed using Chi Square test.

P- Value was set that:

- $P > 0.05$ : Non -significant (NS).

- $P < 0.05$ : Significant (S).

- $P < 0.01$ : Highly significant (HS).

The cohort correlation coefficient was used to assess the inter- and intra observer reliability.

Statistical analysis was performed with IBM® SPSS® Statistics Version 20 for Windows 8.

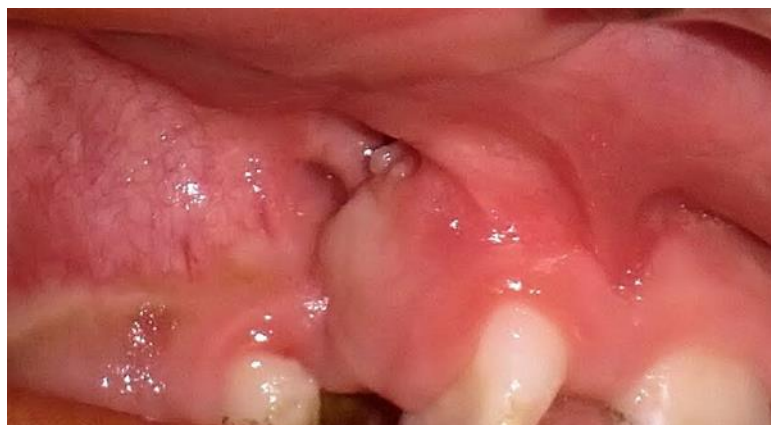### **III. Result**

Clinical data was extracted from the CCC archives as follows :

1. At the recipient site:

Immediate post-operative: patient complained from tenderness in the first post-operative week and up to ten days that was relieved by continuing the already prescribed analgesic (ibuprofen syrup) whenever needed.

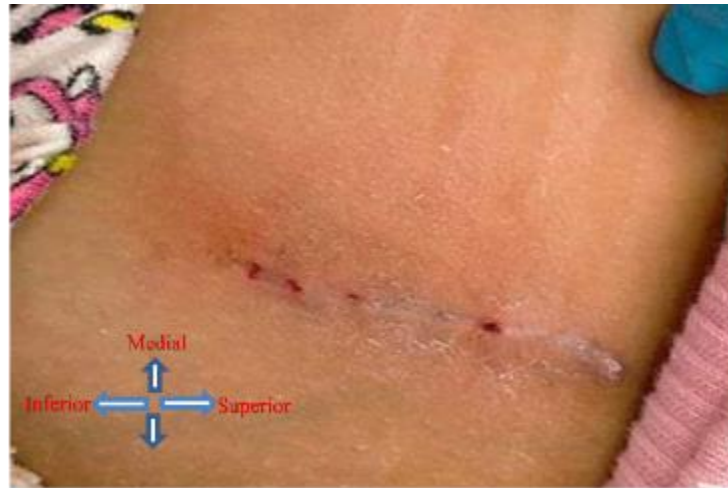Early post-operative: Sutures were removed within 14-21 days post-operatively. Soft tissue healing was optimum, mostly related to poor oral hygiene. This was treated by local wound care using Povidone Iodine mouthwash, Hyaluronic acid gel and Miconazole Nitrate gel three times daily for ten days. Systemic antibiotic were also prescribed for five additional days. Improvement of oral hygiene was stressed on for the patients and guardians in addition to adequate nutrition. There was improvement at the recipient site in the next follow up visit following treatment.



**Figure 1 : PreOperative Fistule**

## 2. Assessment of the donor site:

Donor site assessment was one of the integral steps in clinical follow up. All patients experienced tenderness which was not spontaneous and only during walking during the first post-operative week up to 10 days, which was relieved by analgesics. No paresthesia or numbness nor infection or gait disability were found in any of the cases. Sutures were removed on the 10th post-operative day. (Figure 3)



**Figure 2 : Picture showing donor site 10 days postoperatively**

A comparison was made between healing time in the oral wounds and iliac crest wound showed delayed healing in oral wound (14-21 days) compared to 10 days in the Iliac crest wound.

## B. Radiographic Assessment:

According to Bergland scale, a grade I bergland scale was found at our case showing a bone fill of 75-100%.

According to CBCT , reading was measured from the basal level which is the nasal floor , coronally was the interdental bone this was the height of the formed bone , width was the mesiodistal measurement between roots of the teeth (mid-level Interdentally) and the depth was the buccopalatal dimension at the mid-level of the formed bone.

These measurements were done by two examiners with a Pearson's correlation coefficient of 0.968 which shows that there was a moderate and acceptable agreement between the examiners.

## IV. Conclusion

Dermal fat grafting can be used as an adjunctive biological barrier membrane to decrease the ONF , increase the success rate of ABG through assessment of bone fill both in 2D as well as in 3D..

## References

- [1]. Goudy S, Lott D, Burton R, Wheeler J, Canady J. Secondary alveolar bone grafting: outcomes, revisions, and new applications. *The Cleft Palate-Craniofacial Journal*. 2009 Nov;46(6):610-2.
- [2]. Mossey, P.A., Little, J., Munger, R.G., Dixon, M.J. and Shaw, W.C., 2009. Cleft lip and palate. *The Lancet*, 374(9703), pp.1773-1785.
- [3]. Barry Steinberg DDS, MD, John Caccamese DMD, MD, Bernard J. Costello DMD, MD and Jennifer Woerner DMD, MD. Cleft and Craniofacial Surgery. *Journal of Oral and Maxillofacial Surgery*, 2017-08-01, Volume 75, Issue 8, Pages e126-e150.
- [4]. Eppley BL. Donor site morbidity of rib graft harvesting in primary alveolar cleft bone grafting. *Journal of craniofacial surgery*. 2005 Mar 1;16(2):335-8.
- [5]. Vandeputte T, Bigorre M, Tramini P, Captier G. Comparison between combined cortical and cancellous bone graft and cancellous bone graft in alveolar cleft: retrospective study of complications during the first six months post-surgery. *Journal of Cranio-Maxillofacial Surgery*. 2020 Jan 1;48(1):38-42.
- [6]. Coleman SR. Structural fat grafting: more than a permanent filler. *Plast Reconstr Surg* 2006;118(3 suppl):108S-120S.
- [7]. Khojasteh A, Kheiri L, Behnia H, Tehranchi A, Nazeman P, Nadjmi N, Soleimani M. Lateral ramus cortical bone plate in alveolar cleft osteoplasty with concomitant use of buccal fat pad derived cells and autogenous bone: phase I clinical trial. *BioMed research international* ;2017.
- [8]. Morselli PG, Giuliani R, Pinto V, Oranges CM, Negosanti L, Tavaniello B, Morellini A. Treatment of alveolar cleft performing a pyramidal pocket and an autologous bone grafting. *Journal of Craniofacial Surgery*. 2009 Sep 1;20(5):1566-70.
- [9]. Cricchio G, Lundgren S. Donor site morbidity in two different approaches to anterior iliac crest bone harvesting. *Clinical implant dentistry and related research*. 2003 Oct; 5(3):161-9.