

## A rare case of vitreous retinoma : case report Un cas rare de rétinome vitréen : Case report

Ismail ESSAMLALI<sup>1 a</sup>, Roukaya CHAHIR<sup>a</sup>, Ghizlane DAGHOUI<sup>b</sup>, Loubna ELMAALOUM<sup>b</sup>, Bouchra ALLALI<sup>b</sup>, Asmaa ELKETTANI<sup>c</sup>

*a Medical Resident at Pediatric Ophthalmology Department, 20 august hospital, Casablanca, Morocco*

*b Professor Pediatric Ophthalmology Department, 20 august hospital, Casablanca, Morocco*

*c Professor and Head of Pediatric Ophthalmology Department, 20 august hospital, Casablanca, Morocco*

<sup>1</sup> Corresponding author ESSAMLALI ISMAIL, Casablanca, Morocco.

---

### **Abstract:**

*Retinomas are benign retinal tumors that are caused by mutations of the retinoblastoma gene. Diagnosis of retinoma is made on the basis of a characteristic clinical appearance and absence of growth.*

*These tumors were all associated with vitreous seeding. Through this clinical case, we report a retinoma revealed by an eye trauma by stone throwing and whose regular monitoring for 10 years of the retina finds no sign of evolution.*

*Retinoma or retinocytoma is a rare retinal tumor whose recognition by any ophthalmologist is essential. Screening and monitoring can improve the prognosis of this disease by early treatment of the tumor in case of signs of malignancy*

### **Keywords**

*Vitreous retinoma, retinocytoma, retinoblastoma, pediatric ophthalmology*

---

Date of Submission: 11-03-2023

Date of Acceptance: 25-03-2023

---

### **I. Introduction**

Retinomas are benign tumors of the retina caused by mutations in the retinoblastoma gene. The diagnosis of retinoma is made on the basis of a characteristic clinical appearance and lack of growth [1]. Retinoma presents as an homogeneous translucent intraretinal mass, which is usually associated with changes in the retinal pigment epithelium and irregular looped blood vessels.

The malignant transformation of retinoma into retinoblastoma has been in the literature [2][3]

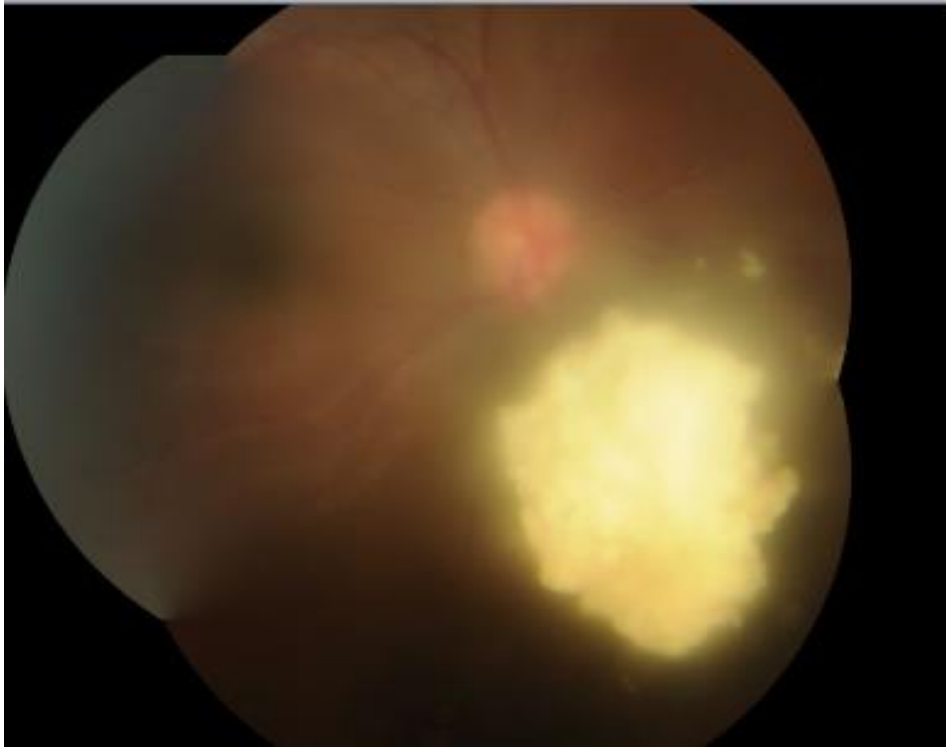
These tumors were all associated with vitreous seeding.

Therefore, we report a rare case of vitreous retinoma revealed by an eye trauma by stone throwing and whose regular monitoring for 10 years of the retina finds no sign of evolution.

This study has been reported in accordance with the SCARE criteria [9]

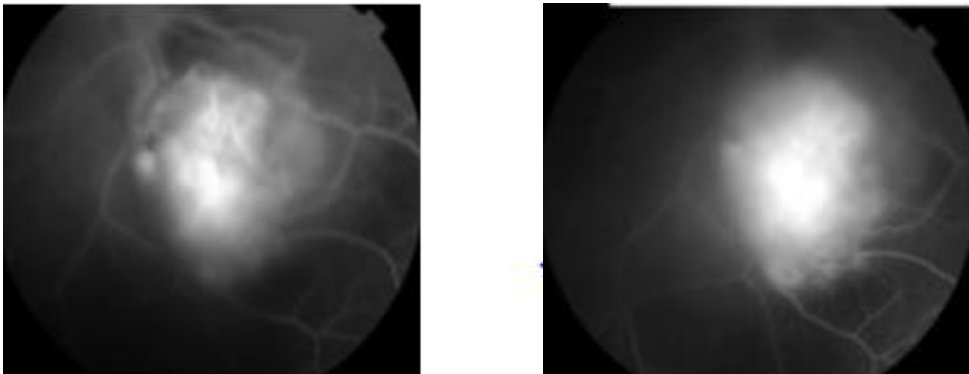
### **II. Case Report**

The patient was 11 years old and had no particular pathological history. She went to the emergency room for a decrease in visual acuity following a right eye trauma caused by a stone throw. The ophthalmological examination revealed a corrected visual acuity of 7/10 in the right eye, a normal anterior segment, a calcified vitreous tyndall with a whitish calcified mass of four papillary diameters (Fig 1).



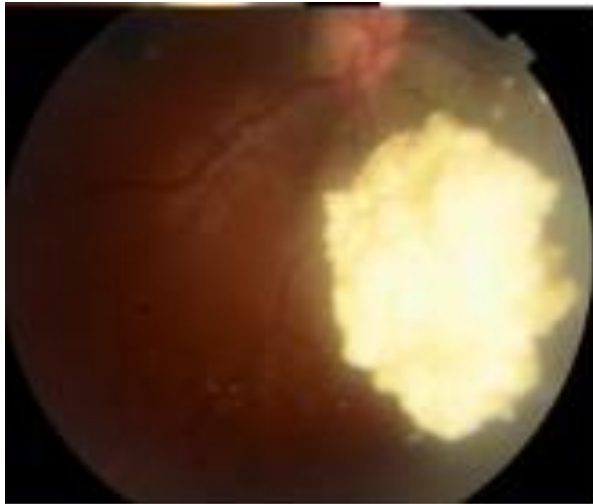
*Figure 1 : retinoma of the eyeretinoma of the right eyewith vitreous swarming*

The examination of the left eye was normal with a corrected visual acuity of 10/10. The examination of the siblings and parents was normal. The tumour was classified as retinocytoma because of the presence of a surrounding narrow band of chorioretinal atrophy, lack of dilated feeder vessels, and the relatively older age at presentation . The ocular ultrasound and angiography performed at admission showed a hyperechoic vitreous with a calcified mass measuring 7.3mm/4.17mm without retinal detachment (Fig 2).



*Figure 2 :calciefed mass of the right eye measuring 7.3/4.17mm without retinal detachment*

The initial course of action was to carry out a close monthly surveillance which did not reveal any signs of evolution. Long-term monitoring did not find any tumor growth or increase in vitreous tyndall. The patient is still under annual surveillance. No change has been seen in 10 years of observation (Fig 3)



*Figure 3 : retinophotography of the right eye showing a regressive aspect of the retinal with clear regression of the vitreous swarming*

### **III. Discussion**

The incidence of retinocytomas is between 1.8% to 10% (4). The average age at the time of discovery of a retinoma is 15 years of age and 41% of patients are asymptomatic [2]. The rate of bilaterality is 18%. Clinically, retinocytoma is characterized by a white, translucent retinal mass, with calcifications, retinal pigment epithelium alterations, and vascular loops [5]. We previously described 24 retinocytomas that showed features of a translucent mass (88%), calcification (63%), and retinal pigment epithelium alterations (54%).<sup>3</sup> Malignant transformation occurred in one case (4%). Munier et al [6] propose classification including 5 forms of retinomas. The types I, II and III are related to the ophthalmoscopic appearance of retinoblastomas in a regressed state after external irradiation[6][7]. Type IV manifests itself as a flat chorioretinal scar and type V may contain pseudocysts. The characteristics consistently observed are a translucent mass, clusters of calcifications, remodeling of the pigment epithelium at the edge of the lesion and areas of chorioretinal atrophy sometimes surrounding the tumor, In this patient, the retinoma in the right eye were type III.

The genetic transmission of retinomas follows the dominant mode with a penetrance comparable to that of comparable to that of retinoblastoma [8].

There is a 4% risk of malignant transformation of a retinoma [3]. These two facts alone make early detection of retinoma even more important.

### **IV. Conclusion**

Retinoma or retinocytoma is a rare retinal tumor whose recognition by any ophthalmologist is essential. Screening and monitoring can improve the prognosis of this disease by early treatment of the tumor in case of signs of malignancy

#### **Consent :**

Patient provided written, retrospective consent for publication following detailed explanation of the purpose of manuscript and understanding that no identifiable information was going to be released.

The patient's parent has given consent for possible publication of this case report.

#### **Sources of funding :**

This study did not receive any sources of funding.

#### **Ethical approval :**

This type of study does not require any ethical approval by our institution.

#### **Provenance and peer review :**

Not commissioned, externally peer-reviewed.

#### **Declaration of competing interest :**

The authors declare no conflict of interest.

**Conflict of interest :** There is no conflict of interest.

**Author contribution** I.ESSAMLALI : drafting the article, study concept, writing the article. R.CHAHIR : acquisition of data.G.DAGHOUI , L.El maaloum ,B.Allali: revising the article. A. El kettani: final approval

### **Bibliography**

- [1]. Gallie BL, Phillips RA, Ellsworth RM, Abramson DH. Significance of Retinoma and Phthisis Bulbi for Retinoblastoma. *Ophthalmology*. déc 1982;89(12):1393-9.
- [2]. Abouzeid H, Balmer A, Moulin AP, Mataftsi A, Zografos L, Munier FL. Phenotypic variability of retinocytomas: pregression and postgression growth patterns. *Br J Ophthalmol*. juin 2012;96(6):884-9.
- [3]. Eagle RC, Shields JA, Donoso L, Milner RS. Malignant Transformation of Spontaneously Regressed Retinoblastoma, Retinoma/Retinocytoma Variant. *Ophthalmology*. sept 1989;96(9):1389-95.
- [4]. Singh AD. Observations on 17 Patients With Retinocytoma. *Arch Ophthalmol*. 1 févr 2000;118(2):199.
- [5]. Gallie BL, Campbell C, Devlin H, Duckett A, Squire JA. Developmental basis of retinal-specific induction of cancer by RB mutation. *Cancer Res*. 1 avr 1999;59(7 Suppl):1731s-5s.
- [6]. Zografos L. *Tumeurs intraoculaires*. Masson. Paris; 2002.
- [7]. Abramson DH, Gerardi CM, Ellsworth RM, McCormic B, Sussman D, Turner L. Radiation Regression Patterns in Treated Retinoblastoma: 7 to 21 Years Later. *J Pediatr Ophthalmol Strabismus*. mars 1991;28(2):108-12.
- [8]. Gallie BL, Ellsworth RM, Abramson DH, Phillips RA. Retinoma: Spontaneous regression of retinoblastoma or benign manifestation of the mutation? *Br J Cancer*. avr 1982;45(4):513-21.
- [9]. Agha RA, Franchi T, Sohrabi C, Mathew G, for the SCARE Group. The SCARE 2020 Guideline: Updating Consensus Surgical Case Report (SCARE) Guidelines, *International Journal of Surgery* 2020;84:226-230