

Honey as an Alternative Fixatives in Oral Cytology - A Review

1. Dr. INDHUJA.M,CRI,DEPARTMENT OF ORAL AND MAXILLOFACIAL PATHOLOGY
2. Dr. JANANI.I , CRI,DEPARTMENT OF ORAL AND MAXILLOFACIAL PATHOLOGY
3. Dr.SHIVAANE.S,CRI,DEPARTENT OF ORAL AND MAXILLOFACIAL PATHOLOGY
4. Dr. POOJA SRI, POST GRADUATE,DEPARMTENT OF ORAL AND MAXILLOFACIAL PATHOLOGY
5. Dr. KARTHIKA, PROFESSOR, DEPARTMENT OF ORAL AND MAXILLOFACIAL PATHOLOGY
6. Dr. SATHISH KUMAR, HEAD OF THE DEPARTMENT, DEPARTMENT OF ORAL AND MAXILLOFACIAL PATHOLOGY

ABSTRACT:

Cytopathology in the present era is a valid and wellaccepted diagnostic tool.Accuracy of cytopathological diagnosis depends on multiple steps such as collection, proper fixation, staining and quality control.Fixation is a physiochemical process that perfectly preserves cellular morphology.An ideal fixative is expected to impart mechanical rigidity to withstand tissue processing, prevent decomposition, putrefaction and autolysis.Considering the chemical fixatives,nowadays natural alternatives like honey is being used.The various properties of honey contribute for fixing property.In the absence of alcohol or as a substitute to it, honey can be used as a successfully alternative.

KEYWORDS: Cytology, Fixative, Honey, Fixation

Date of Submission: 06-03-2023

Date of Acceptance: 18-03-2023

I. INTRODUCTION:

The oral epithelium is constantly exposed by various carcinogens, and it regularly undergoes the process of maturation wherein old cells are continuously replaced by the new cells. The microscopic study of these exfoliative cells by scrapping is known as exfoliative cytology^[7].Cytopathology in the present era is a valid and well accepted diagnostic tool.Accuracy of cytopathological diagnosis depends on multiple steps such as collection, proper fixation, staining and quality control^[1].Fixation is the most imperative step in the practice of diagnostic pathology for processing of biopsy tissue specimen to examine and for the archival preservationThe primary intention of fixation is to preserve the tissues in a life-like state, prevent bacterial putrefaction, prevent autolysis, and increase the refractive index of the tissue.An ideal fixative is expected to impart mechanical rigidity to withstand tissue processing, prevent decomposition, putrefaction and autolysis .

In the routine laboratory, 10% neutral buffered formalin (NBF) is the fixative of choice. However, formalin is a human carcinogen.Ethanol is well known gold standard fixative used in cytology.Ethanol though an efficient cytological fixative has few disadvantages such as it is subjected to pilferage, expensive, flammable, evaporates easily and not freely available.It usually causes skin and eye irritation^[12].

In recent years, natural sweetener such as honey have been experimentally used as cytological fixatives.They found that both ethanol- and honey-fixed smears were at par with each other and concluded that honey could be safely used as a substitute to ethanol.

FIXATION:

Fixation is a physiochemical process that is gradual and complex, involving diffusion of fixative that perfectly preserves cellular morphology yet does not modify the specimen composition.It is the foundation for subsequent stages in the preparation of tissueprocessing for microscopical examination. The selection of fixative depends on considerations such as structures and entities that are to be demonstrated and the effects of short-term and long-term storage.Probable mechanism of fixation is due to presence of carbohydrates such as fructose which causes breakdown of aldehyde in presence of low pH.These aldehydes then cross-link with tissue amino acids which leads to tissue fixation.Adequate fixation is required for proper examination of tissue or cells understudy, to reach a proper diagnosis.The speed of fixation depends on the rate of diffusion of fixative into the

tissue and the rate of chemical reactions with various components. In practice, it is assumed that these processes require at least 1 hour per millimeter of tissue thickness, but routinely the tissues are fixed for 24–48 hours

FIXATIVES:

Ideal fixative must be nontoxic, cheap and easily available, should preserve tissue for long time and should be compatible with immunohistochemical and molecular techniques. Most of the fixative works on the principle of cross-linkage of cellular proteins. Formaldehyde was first discovered in 1859 by the Russian chemist Alexander M. Butlerov^[2]. Champy's fluid, glacial acetic acid, alcohol, formol saline, Carnoy's fluid, Clarke's fluid, Newcomer's fluid, Flemming's fluid, Mercuric chloride fixative, Chromic acid, Ethanol is a well known and widely accepted fixative. Methanol is used alternatively.

NATURAL FIXATIVES:

"Innovation is change that unlocks new values"^[5]. In search of eco-friendly and ideal fixative many natural sweeteners are being experimented. To find a safer alternative has been of concern for most of the pathologist. Exposure to the chemicals used in the processes can cause various health hazards to the laboratory technicians, pathologists, scientists. Natural alternatives used as fixatives are honey, sugar syrup, jaggery.

HONEY AS A NATURAL ALTERNATIVE FIXATIVES:

HISTORY:

Honey is defined as the nectar and saccharine exudation of plants, which gathered, modified and stored as honey in honeycombs by honey bees, *Apis mellifera*. Honey is as old as the written history - dating back to 2100 B.C. - Sumerian and Babylonian cuneiform writings. Honey was man's first and most reliable source of sweetener. History knows examples of things preserved in honey for decades and even centuries.

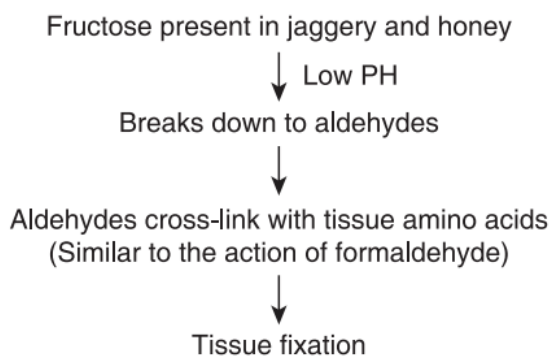
CONSTITUENTS:

Honey primarily contains sugar and water which accounts for 95%–99% of honey dry matter. Majority of these are simple sugars, fructose (38.2%), and glucose (31.3%)^[4]. It contains hydrogen peroxide, chrysin, pinobanksin, vitamin C, catalase and pinocembrin^[8,11]. These compounds give distinct properties to the honey which are antiautolytic, antimicrobial, antiviral, antimutagenic and antioxidant effects which have been known for several centuries. Honey also has been shown to possess acidic, preserving, dehydrating and tissue hardening properties.

PROPERTIES IN FIXING:

Recently, Patil et al.^[10] used 20% honey solution and 30% jaggery solution as routine tissue fixative. Honey at 20% concentration also had acidic pH (4.64). Usually, the fixatives that contain acids or have low pH do not favor the preservation of cytoplasmic constituents; however, they act as good nuclear fixatives.

Literature has revealed two possible mechanisms for honey fixation. The first one is through the conversion of carbohydrate to gluconic acid, which is known to have a wide application in food and pharmaceutical industry as a preservative by preventing the decomposition of the food. The other one is through the presence of fructose in honey which at low pH breaks down to form aldehyde groups.



Subsequently, these aldehyde groups form methylene bridges with lysine amino acids, which lead to the tissue fixation. The quantum of studies accepts honey as a fixative and as an alternative substitute to

formalin in histopathology. Honey has been found to prevent autolysis as tissues put in it for up to 30 days did not show any sign of putrefaction and autolysis.

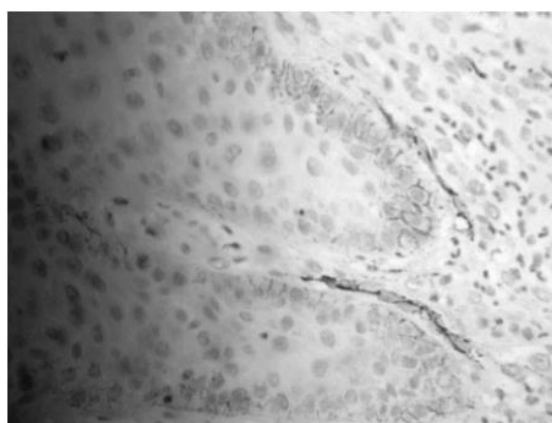
It has the quality of penetrating the deepest tissue and can prevent autolysis and putrefaction. The tissue hardening property makes it similar in action to fixatives which acts by hardening the tissues. Honey has been experimented as fixative in cytology which has provided excellent cellular preservation and dehydration which are required for fixing the smears in Cytopathology. A possible mechanism by which honey fix tissues.

Fungi supply the enzymes invertase, maltase and zymase. Intrinsic enzymes of honey such as invertase and maltase may also assist in the process. The enzyme invertase hydrolyses sucrose to glucose and fructose, and the enzyme zymase converts glucose and fructose to ethanol. As the alcohol concentration rises, the fungi are unable to survive since a concentration of more than 12% kills the fungi. Thus, unlike other staining solutions where appearance of fungal molds is considered to be detrimental, it may be advantageous in honey and jaggery fixative solutions.

Although ethanol and its various concentrations have been widely used in histopathology laboratories, it has many well-known disadvantages. However, honey has many advantages and disadvantages over ethanol. Any cytological smears in which preservation of cellular details is necessary can be adequately and efficiently assessed with fixation in 20% unprocessed honey, which is at par with and as good as ethanol^[3]. In honey fixed smears one could very clearly appreciate all cellular details such as nuclear staining, cytoplasmic staining, cellular morphology, clarity and uniformity of the staining.^[6]

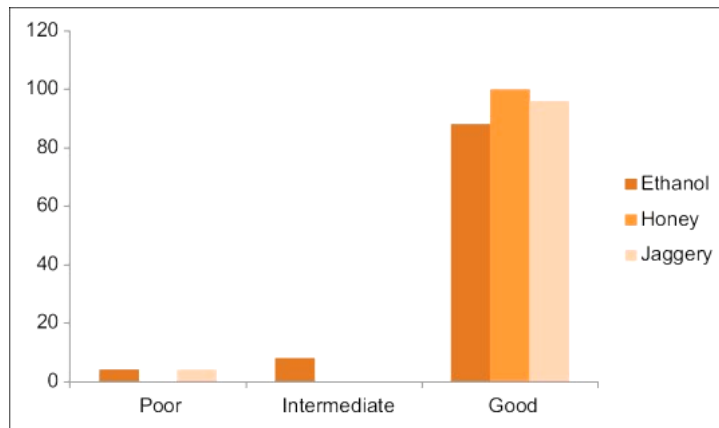


The figure shows honey-fixed tissue with clear nuclear details in both epithelium and connective tissue (610 magnification). There is evidence of homogenization in the connective tissue.^[13]



The figure shows honey-fixed epithelium with positive immunostaining of podoplanin.^[13]

It was found that all of the honey-fixed samples showed good staining as compared to 96% of jaggery-fixed and 88% of ethanol-fixed smears



Correlation of nuclear staining among ethanol-fixed, honey-fixed and jaggery-fixed smears (in percentage)^[10]
 Both processed honey and unprocessed honey have all the fixative properties that an ideal fixative should have and can be used as an alternative fixative. Hydrogen peroxide has the ability to form covalent complex with hemoglobin and spectrin which are specific structures of red blood cells. This may explain why honey masks the staining of red blood cells. All honey groups showed weak staining of the reticulin fibers using G&S method.

Post fixation macroscopic findings^[10]:

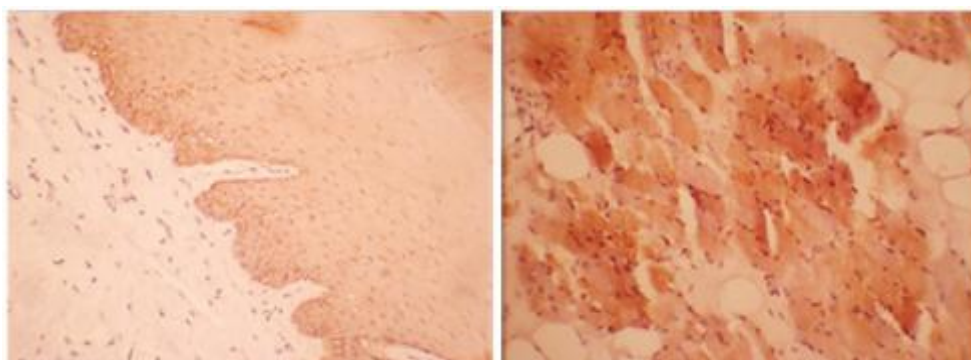
CHARACTERISTIC	FINDING
Gross morphology	Well-preserved
Colour	Light brown
Consistency	Less firm
Odor	No significant odor

Problems encountered and their remedial measures^[10]:

Problem	Fixative	Remedy
Breach in continuity of the section along with folds	Honey	Re-impregnate the tissue for another hour

IMMUNOCHEMISTRY:

Even Immunohistochemistry could be done on honey fixed slides as it fixes tissue without damaging or altering the antigens present in the tissues^[9]. Unlike other staining solutions where appearance of fungal molds is considered to be detrimental, it may be advantageous in honey fixative solutions.



The Figure shows the intensity of the immunohistochemical stains

DRAWBACK:

The major drawbacks seen with honey was, it attracted insects and had a short shelf life.

II. CONCLUSION:

Honey due to its inherent antimicrobial and fixative property can be used as natural and cheaper alternative to ethanol as fixative. An added benefit of honey is being eco-friendly, easily available, cost effective, nontoxic and noninflammable. Using honey also improves the safety and work environment in the laboratory. Honey containing 19.3 g/100 mL reducing sugars fix the oral smears satisfactorily in a mechanism akin to ethanol by coagulating and denaturing proteins. To conclude that in the absence of alcohol or as a substitute to it, honey can be used as a successfully alternative.

REFERENCES:

- [1]. Nerune S.M, Khan M.N, Potekar R.M, Patil V. Natural versus synthetic fixative in oral cytological smears – A double blind study. *Indian J Pathol Oncol.* 2018;5(4):663-666
- [2]. Lalwani V, Surekha R, Vanishree M, Koneru A, Hunasgi S, Ravikumar S. Honey as an alternative fixative for oral tissue: An evaluation of processed and unprocessed honey. *J Oral Maxillofac Pathol* 2015;19:342-7
- [3]. Sah K, Janardhana Amaranath BJ, Chandra S, Ahmad S. Utilization of processed honey and jaggery as an oral cyto-fixative. *Indian J Dent Sci* 2022;14:6-10.
- [4]. Pandiar D, Baranwal HC, Kumar S, Ganesan V, Sonkar PK, Chattopadhyay K. Use of jaggery and honey as adjunctive cytological fixatives to ethanol for oral smears. *J Oral Maxillofac Pathol* 2017;21:317
- [5]. Singh A, Hunasgi S, Koneru A, Vanishree M, Ramalu S, Manvikar V. Comparison of honey with ethanol as an oral cytological fixative: A pilot study. *J Cytol* 2015;32:113-7
- [6]. Priyadarshi A, Kaur R, Issacs R (August 18, 2022) Honey as a Cytological Fixative: A Comparative Study With 95% Alcohol. *Cureus* 14(8): e28149.
- [7]. Sah K, Janardhan BJ, Srivastava RK, Nigam S. Efficacy and reliability of various grades of processed honey as a fixative: A comparative study. *Indian J Dent Sci* 2021;13:103-7.
- [8]. Thamilselvan, Snega, et al. "Honey as a Natural Alternative for Formalin Fixative--A Systematic Review." *Journal of Evolution of Medical and Dental Sciences*, vol. 10, no. 6, 8 Feb. 2021, pp. 369+.
- [9]. Majumdar B, Rao RS, Patil S. Tissue Preservation with Natural Fixatives: An Immunohistochemical Evaluation. *World J Dent* 2016;7(2):87-91.
- [10]. Patil S, Rao RS, Ganavi BS, Majumdar B. Natural sweeteners as fixatives in histopathology: A longitudinal study. *J Nat Sc Biol Med* 2015;6:67-70
- [11]. Alwahaibi, Nasar et al. "Efficiency of neutral honey as a tissue fixative in histopathology." *bioRxiv* (2021): n. pag.
- [12]. M. Khan, R. Potekar, S. Nerune, A. Reddy, Published 1 June 2018 *Medicine*. "Comparison of Fixative Properties of Honey with Ethanol in Oral Cytological Smears" DOI:10.21276/APALM.1852
- [13]. Sabarinath, Balaraman & Sundharam, Sivapatha & Mayilvakanam, Sathyakumar. (2014). Fixative properties of honey in comparison with formalin. *Journal of Histotechnology*. 37. 21-25. 10.1179/2046023613Y.0000000037.

Dr. INDHUJA.M,CRI, et. al. "Honey as an Alternative Fixatives in Oral Cytology - A Review." *IOSR Journal of Dental and Medical Sciences (IOSR-JDMS)*, 22(3), 2023, pp. 25-29.