

Study of Correlation between fundus changes and visual morbidity in pregnancy Induced Hypertension

DR. MAMATHA K¹, DR. RAJENDRA PRASAD J²

Post graduate¹, Professor², Department of Ophthalmology, DR.PSIMS & RF, INDIA)

ABSTRACT:

BACKGROUND: Ocular involvement is common in PIH occurring in 30%–60% of patients. Subjective visual symptoms including decreased vision, visual field defects, diplopia, photopsia are present in approximately 40% of PIH patients. Regular ocular examination reveals important objective information concerning this disorder with regard to severity and is of prognostic value. **AIM:** To evaluate and correlate the retinal findings on fundoscopic examination and visual morbidity in pregnancy induced hypertension (PIH). **MATERIALS and METHODS:** A prospectivestudy was done at DR.PSIMS & RF among 123 cases of pregnancy induced hypertensive women, admitted in the obstetric ward and ambulatory patients who attended to ophthalmology OPD. History regarding age, parity, gravida, gestational age, and initial examination included visual acuity measured, anterior segment examination done, and Intraocular pressure measured, dilated fundus examination was done. **RESULTS:** Out of 123 patients, 63(51.89%) were primigravida, 43(35.32%) were gravida 2, 17(12.79%) were multigravida. Gestational hypertension was seen in 70(60.50%), pre-eclampsia in 41(30.05%), eclampsia in 8(6.45%). In the present study, hypertensive retinopathy was seen in 26.82% of the patients with PIH of which grade 1 hypertensive retinopathy was seen in 60.6066%, papilledema was seen in 3.030% and no retinal detachment. **CONCLUSION:** Definite retinal changes are present in PIH, but visual symptoms are fewer in patients with PIH, and often absent unless the macula is involved. Attenuation of arterioles is the first detectable and most common retinal change. The majority of retinal changes were Grade I hypertensive retinopathy. Progress of retinopathy increases with the severity of PIH and usually regresses with a decrease in blood pressure and may disappear completely after delivery due to lack of placental toxins. Regular ocular examination reveals important objective information concerning this disorder with regard to severity and is of prognostic value. **KEY WORDS:** visual morbidity, Eclampsia, exudative retinal detachment, hypertensive retinopathy, pre-eclampsia, pregnancy-induced hypertension.

Date of Submission: 02-02-2023

Date of Acceptance: 13-02-2023

I. INTRODUCTION

Pregnancy-induced hypertension (PIH) includes gestational hypertension, pre-eclampsia, and eclampsia. PIH is a hypertensive disorder in pregnancy that occurs in the absence of other causes of elevated blood pressure (140/90 mmHg, or a rise of 30 mmHg of systolic pressure, or a rise of 15 mmHg of diastolic pressure), taken on two occasions after rest in combination with generalized oedema and/or proteinuria.^[1] When there is significant proteinuria it is termed as preeclampsia; seizures or coma as a consequence of PIH is termed as eclampsia.^[2] PIH is a common obstetrical complication that leads to new-onset hypertension and damage to other organs after 20 weeks of gestation.^[3] Ocular involvement is common in PIH occurring in 30%–60% of patients. Subjective visual symptoms including decreased vision, visual field defects, diplopia, photopsia are present in approximately 40% of PIH patients. The pathological changes of this disease appear to be related to vascular endothelial dysfunction and its consequences (generalized vasospasm and capillary leak).^[4] Common symptoms are blurring of vision, photopsia, scotomas and diplopia. Visual symptoms may be the precursor of seizures.^[4] Vasospastic manifestations are reversible and the retinal vessels rapidly return to normal after delivery.^[5,9,10]

II. MATERIALS AND METHODS:

Study was done among 123 patients of pregnancy induced hypertension, admitted in the obstetric ward and ambulatory patients who attended to ophthalmology OPD.

History regarding age, parity, gravida, gestational age, and initial examination included visual acuity measured, anterior segment examination done, and Intraocular pressure measured, dilated fundus examination was done.

Study was conducted at Dr. PSIMS & RF chinnaoutpalli.

Study design – prospective study

Study period - 12 months (December 2021-December2022).
Sample size – 123 cases of pregnancy induced hypertension.

INCLUSION CRITERIA:

- Pregnancy induced hypertension patients.

EXCLUSION CRITERIA:

- pre-existing vascular/renal disease,
- any underlying ocular comorbidity like
 1. glaucoma
 2. cataract
 3. pre-existing retinopathy.

III. PROCEDURE METHODOLOGY:

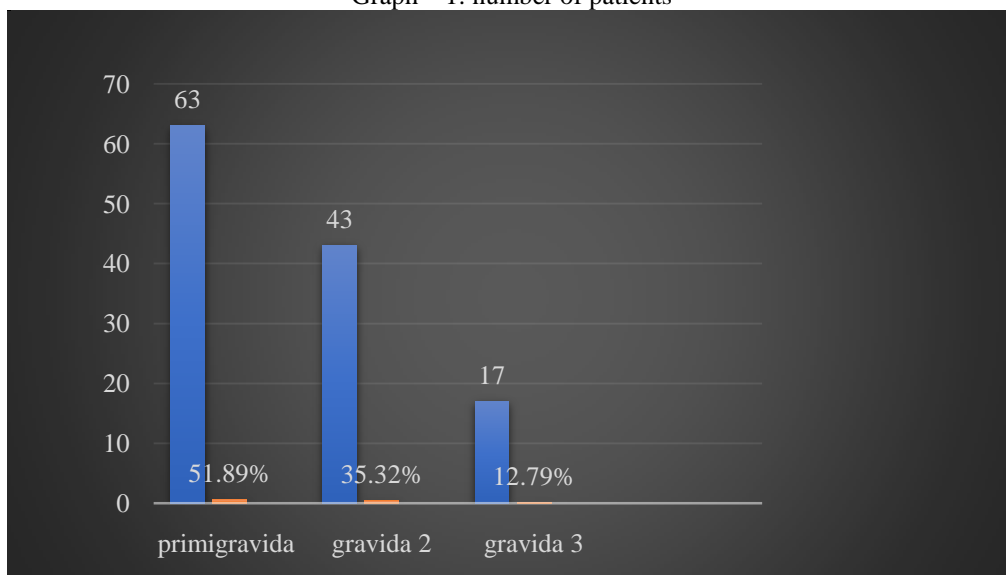
After obtaining history for any eye symptoms, extraocular movements and the anterior segment were examined. Both pupils were dilated with 1% tropicamide eye drops, and the fundus examination was done by the ophthalmologist with a direct ophthalmoscope in the ward. Changes suggestive of hypertensive retinopathy were taken as positive findings in these patients. Age, parity, gravida, gestational age, medical history, and blood pressure recordings were noted. Based on American College of obstetricians and Gynaecologist (ACOG) 2020 guidelines, we adopted while recruiting patients into our study.^[6]

The retinal changes (hypertensive retinopathy) were graded according to Keith Wagener classification into:^[7]
Grade 1: Mild generalized arterial attenuation;
Grade 2: More severe Grade 1 with focal arteriolar attenuation;
Grade 3: Grade 2 changes plus haemorrhages, hard exudates, cotton wool spots;
Grade 4: Grade 3 changes with optic disc swelling (papilledema).

IV. RESULTS:

Total of 123 patients included in the study, Gestational age ranging from 27-42 weeks. Out of 123 patients(Graph -1)- 63(51.89%) were primigravida, 43(35.32%) were gravida 2, 17(12.79%) were multigravida. (Graph-2)Gestational hypertension was seen in 70(60.50%), pre-eclampsia in 41(30.05%), eclampsia in 8(6.45%). In the present study out of 123 patients hypertensive retinopathy changes was seen in 26.82% of the patients with PIH of which grade 1 hypertensive retinopathy(image 1) was seen in 60.6066%, papilledema(image 4) was seen in 3.030% and no retinal detachment and macular oedema.

Graph – 1: number of patients



Graph-2: number and percentage of patients with gestational hypertension, pre-eclampsia and eclampsia

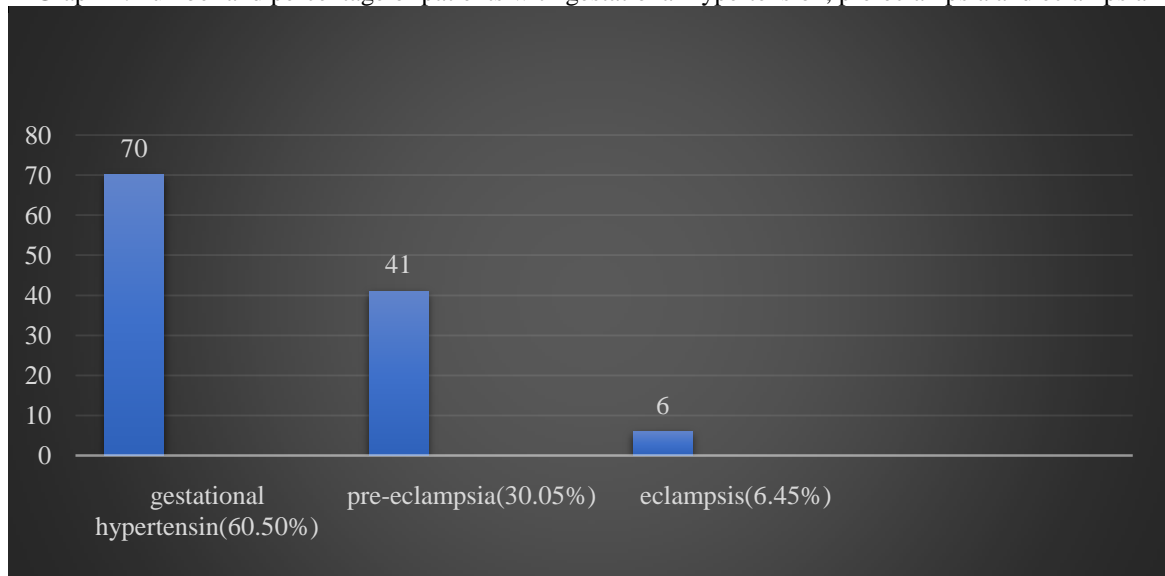


Table – 1: number of PIH patients presented with fundus changes

PIH	Number of patients	Fundus changes seen in	percentage
Gestational hypertension	74	7	10%
Pre-eclampsia			
• Mild	28	6	22%
• Moderate	13	12	95.58%
Eclampsia	8	8	100%
	Total-123	Total -33	

Table 2: number and percentage of patients with hypertensive retinopathy

Hypertensive retinopathy grading	Number of patients	percentage
Grade 1	20	60.6066%
Grade 2	7	21.212%
Grade 3	5	15.512%
Grade 4	1	3.030%
Retinal detachment	0	0%

Images of Fundus pictures of hypertensive retinopathy

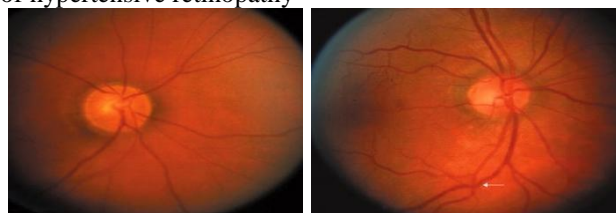


Image 1 - grade 1

Image 2- grade 2

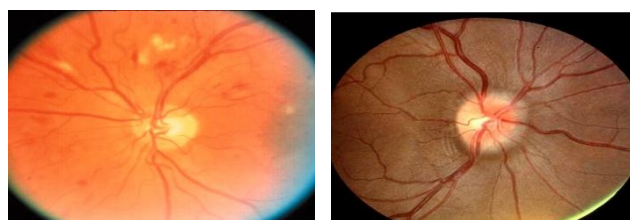


Image 3- Grade 3 Image 4-grade 4

Table 3-Best corrected visual acuity

Hypertension grading	BCVA at the time of presentation	BCVA after 1month of delivery
Grade 1	6/6	6/6
Grade 2	6/6	6/6
Grade 3	6/9-6/6	6/6
Grade 4	6/9	6/6

V. Discussion:

Changes in the retinal vascularity reflect the status of hypertension, and fundus examination has been considered as a routine practice to assess the progression of systemic hypertension. In PIH, retinal evaluation is done to assess maternal hypertension and fetal health. In the present study majority of the patients presented with grade 1 hypertensive retinopathy followed by grade 2 hypertensive retinopathy, papilledema was seen in one patient and retinal detachment and macular oedema in none. An ophthalmologist plays an important role in the management of these patients as advanced retinal changes will require drastic decisions such as termination of pregnancy. This may have to be planned particularly if exudative retinal detachment or papilledema is detected during the ophthalmic examination as it indicates similar changes as a cause of placental ischemia.^[8] The aim of our study was to analyze the fundus changes in pre-eclampsia and eclampsia and its effect on visual loss. Decrease in visual acuity is more frequently in eclampsia than in pre-eclampsia patients. Most of the patients have good BCVA as none of the patient had macular involvement. Almost all patients had complete visual recovery after childbirth when the hypertension was reversed. The presence of papilledema in the eyes may indicate raised intracranial tension, and such patients may develop convulsions. Predominant changes in preeclampsia were arterial attenuation and arterio- venous crossing changes. The presence of macular edema or papilledema or retinal detachment are the warning signs for termination of pregnancy. The management of retinal detachment is not surgery, but termination of pregnancy after controlling blood pressure so that vision can be saved in the affected eye.

VI. Conclusion:

Definite retinal changes are present in PIH, but visual symptoms are fewer in patients with PIH, and often absent unless the macula is involved. Sudden onset of headache and visual loss which is resistant to routine therapy may be the warning symptom before the onset of the first convulsion. Attenuation of arterioles is the first detectable and most common retinal change. The majority of retinal changes were Grade I hypertensive retinopathy. Progress of retinopathy increases with the severity of PIH and usually regresses with a decrease in blood pressure and may disappear completely after delivery due to lack of placental toxins. Regular ocular examination reveals important objective information concerning this disorder with regard to severity and is of prognostic value.

References

- [1]. Uma MS, Bhuvana S, Annamalai R, Muthayya M. Visual morbidity and spectrum of ophthalmic changes in pregnancy induced hypertension. *J Family Med Prim Care* 2022;11:2488-92.
- [2]. Reddy SC, Sivalingam N, Sheila Rani KG, Tham SW. Fundus changes in pregnancy induced hypertension. 2012; 5(6):694-697
- [3]. Cunningham FC, Leveno KJ, Bloom SL, Spong CY, Dashe JS, et al. *Williams Obstetrics*. New York: Mc Graw-Hill; 2014. p. 728-69.
- [4]. Bakhda RN. Clinical study of fundus findings in pregnancy induced hypertension. *J Family Med Prim Care*. 2016 Apr-Jun;5(2):424-429.
- [5]. Das KA, Jaisal P. Fundus changes in pregnancy induced hypertension. *Int J Med Res Prof* 2016;2:47-50.
- [6]. Gestational hypertension and preeclampsia. ACOG Practice Bulletin No. 222. American College of Obstetricians and Gynecologists. *ObstetGynecol* 2020;135:e237-60.

- [7]. Kanski. Clinical Ophthalmology-A Systematic Approach. 9th ed.
- [8]. Upadya M, Rao ST. Hypertensive disorders in pregnancy. *Indian J Anaesth*2018;62:675-81.
- [9]. Richard RO. Pregnancy induced hypertension (preeclampsia-ecclampsia) In: Schachat AP, Murphy RB, editors. *Retina*. 2nd ed. St Louis: Mosby; 1994. pp. 1405–1412.
- [10]. Reddy SC, Nalliah S, George SRA, Who TS. Fundus changes in pregnancy induced hypertension. *Int J Ophthalmol*. 2012 Dec 18;5(6):694–7.

DR. MAMATHA K, et. al. “Study of Correlation between fundus changes and visual morbidity in pregnancy Induced Hypertension.” *IOSR Journal of Dental and Medical Sciences (IOSR-JDMS)*, 22(2), 2023, pp. 52-56.