

The Short-term Outcome of Femoral Shaft Fractures Treated with SIGN Intramedullary Nail in a Nigerian Tertiary Institution.

Oguzie G.C, Obioha I.C, Duru N.E, Iyidobi E.C, Lasebikan O.A

FWACS, FMCOrtho, FICS- Consultant Orthopedic & Trauma Surgeon, Federal University Teaching Hospital, Owerri.

FWACS, - Consultant Orthopedic Surgeon, Federal university Teaching Hospital Owerri

FWACS, FICS- Chief Consultant Orthopedic Surgeon, National Orthopedic Hospital, Enugu

FWACS, FMCOrtho, FICS- Chief Consultant Orthopedic Surgeon, National Orthopedic Hospital, Enugu

Correspondence To: Dr Gerald Oguzie, Federal University Teaching Hospital, Owerri

Abstract

Femoral shaft fractures constitute majority of long bone fractures. Closed IM nailing is currently the option of choice however, they require an image intensifier. This is largely unaffordable in resource poor settings. The SIGN nail was developed for resource poor regions with the benefit of not requiring a C-arm. These nails are provided free and offer the rare opportunity of patients accessing this current treatment technique irrespective of their socio economic status and based on evidence based decisions which is lacking due to paucity of clinical trials. The study was a prospective interventional study aimed to determine the short term outcome and was carried out between January and December 2016 at National Orthopaedic Hospital Enugu, Nigeria. Ethical clearance was obtained from the hospital ethical committee. A total of 54 patients were evaluated. The age range was predominantly between 3rd and 4th decade. The average fracture healing time was 18.9 ± 4.7 weeks. There was superficial surgical site infection in 3 (5.6%) patients. A significant limb shortening prevalence of 14.1% was found in this study however, 96.2% had good or excellent Thoresen's outcome score. Knee stiffness was significantly higher among patients treated with antegrade approach. Femoral shaft fractures treated with SIGN nail has good to excellent outcome.

Keywords: Femoral Shaft Fractures, SIGN, Intramedullary Nail

Date of Submission: 01-02-2023

Date of Acceptance: 11-02-2023

I. Introduction

Femur shaft fractures are among the most common fractures encountered in orthopedic practice.^{1,2} They can cause lengthened morbidity and far-reaching disability except treatment is appropriate.¹ They make up 5-10% of all fractures and require a high energy transfer to occur.^{1,2} Overall, the mean age of adults involved is 35 years.³ However, it has variations in the gender and age distribution with two peaks: one among young males at higher risk of trauma¹⁻⁴ and the other in elderly females, as a result of post-menopausal decrease in bone mineral density from osteoporosis.¹ It is classified as comminuted based on the presence of butterfly fragments or segmental based on the number of fracture segments. These are the most challenging to treat because of rotational and vertical instability.²

Operative reduction and fixation is practiced in most centers around the world. The options of internal fixation methods include: Intramedullary (IM) nailing or plate and screw fixation. The choice of treatment in any particular case may be influenced by such factors as the type and location of fracture, degree of comminution, age and socio-economic status of the patient.^{1,3,7} The surgeon's preference may also be an important consideration.⁷ Interlocking IM nailing is the treatment of choice for most femoral shaft fractures giving consistently excellent outcome.^{1,3,7} IM nailing can be performed open or closed using either antegrade or retrograde approach. In open technique the fracture site is exposed and reduction done manually under direct vision, whereas in closed nailing technique which is ideal, the IM device is inserted under image guidance without exposing the fracture site. This has the benefit of lower infection risk but the combination of reduced cost and lower risk of radiation exposure are factors that has popularized the use of external jig-aided interlocking system, especially in resource-poor settings.^{6,8} The Surgical Implant Generation Network (SIGN) nailing system was founded by Lewis Zirkle for low and middle income countries (LMIC) where acquisition and maintenance of fluoroscopic equipment is a challenge.^{6,8-11} The implants and instrumentations are obtainable free of charge by health institutions. SIGN IM nail insertion makes fracture table, power reaming or image

intensifier non-essential.⁶ It furthermore has reduced the burden of provision of care with documented benefits of early postoperative weight bearing, satisfactory knee range of motion (ROM), high rate of fracture union and low complication rate.^{5,6,8,11}

Some complications have been reported in patients following treatment of femoral shaft fractures using SIGN interlocking IM nailing system.^{6,8} These include: surgical site infection (SSI), limb length discrepancy (LLD), rotational mal-alignment, knee joint stiffness, knee pain, hip pain, angular mal-union, non union, implant migration and implant failure.^{6,8,10}

There is paucity of studies in our expanse assessing the treatment outcome. This is a major objective of this study. This study has guided the formulation of a validated evidence based treatment protocol for these patients in the region.

Aims: To determine fracture union, healing time and complications among patients with femoral shaft fractures treated with SIGN IM nail.

II. Methodology:

The study was a prospective interventional study carried out at the National Orthopedic Hospital, Enugu in Nigeria, a tertiary multi-specialist hospital. This study was conducted over a period of one year from January to December 2016. The study population included patients undergoing orthopedic procedures for femoral shaft fractures using the SIGN instrument system, ≥ 18 years, closed femoral shaft fracture(s), ≤ 3 -months old fracture and completed 24 weeks follow up. Subjects with open femoral fractures, bilateral fractures, intra-articular femoral fractures, Pathological femoral fractures, immunosuppression by HIV and uncontrolled Diabetes mellitus were excluded.

Patient Assessment: Consecutive patients with closed femoral diaphyseal fractures were evaluated clinically and radiologically. The Advanced Trauma Life Support protocol (ATLS) was employed in the resuscitation of patients that presented through the Emergency room (ER). Screening of patients included history taking, physical examination, and investigations. All consenting patients were studied.

The sample size calculation was done following a pilot study with 10% added for attrition making up 54 patients. Consecutive patients who met the study inclusion criteria were enrolled until our sample size was reached. The data was collected using a well designed structured data proforma. The patients were operated on by a Consultant or Senior registrar 1 under supervision. All relevant information was obtained from the patient from the time of recruitment to discharge and specified follow up dates and was recorded in the case notes and data collection tools. Ethical clearance was obtained from the Ethical Clearance Committee of NOHE.

Intraoperative Procedure: All patients were administered intravenous prophylactic antibiotics (ceftriaxone 1gram) and the skin preparation was as the standard protocol in NOHE. The patients were offered standard surgical approaches for each indication. The patient's position was dependent on the approach: supine or lateral decubitus position on the operating table for the retrograde or antegrade nailing approach respectively.^{5,24} Antegrade approach was performed for proximal and middle third femoral fractures and retrograde approach for distal third fractures.

Postoperative care and follow-ups: An immediate post-operative examination to assess the lower limb length and postoperative x-rays were obtained. Physiotherapy was commenced and Following discharge home they were scheduled for regular follow up visits. The surgical wounds were examined for infection on the 5th day post operatively and 14th day during suture removal and during subsequent visits. The wound surveillance was done using Center for Disease Control and Prevention (CDC) criteria for diagnosis of surgical site infection. Standard patient care and discharge protocol was observed.

During the follow-up visits scheduled at 6th, 12th, 18th and 24th weeks respectively. radiographs were obtained and **union** was assessed by the number of cortices (0 to 4) bridged by callus and clinical union as absence of tenderness at the fracture site and ability to bear weight without thigh pain with a squat and smile photograph.⁵⁵

Data Management: All data obtained were analysed using SPSS Statistical soft ware version 21. (P-value < 0.05) **The study limitation was the** limited follow up of 24 weeks, which was not adequate to fully assess the rate of union and deep infection.

III. Results

A total of 59 patients with closed femoral shaft fracture were included in the study and analyzed. However four patients were lost to follow up after discharge from the hospital and 1 patient was lost to follow up after the 6th week visit. The remaining 54 patients completed a minimum of 24 weeks of follow up after surgery. The age range of the patients is 18-85 years with predominance of 3rd and 4th decade. Most of the fractures 34(62.96%) were fixed by a Consultant.

Table1. Age distribution of the patients

Age (years)	Frequency	Percent
11 – 20	4	7.4
21 – 30	14	25.9
31 – 40	15	27.8
41 – 50	11	20.4
51 – 60	4	7.4
>60	6	11.1
Total	54	100.0

Table 1 shows that the most common affected age group is 31-40 years.

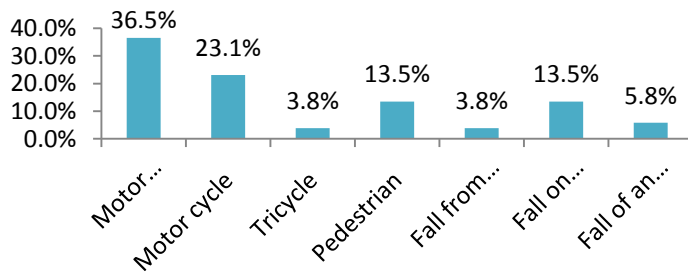


Figure 2. Cause of Injury

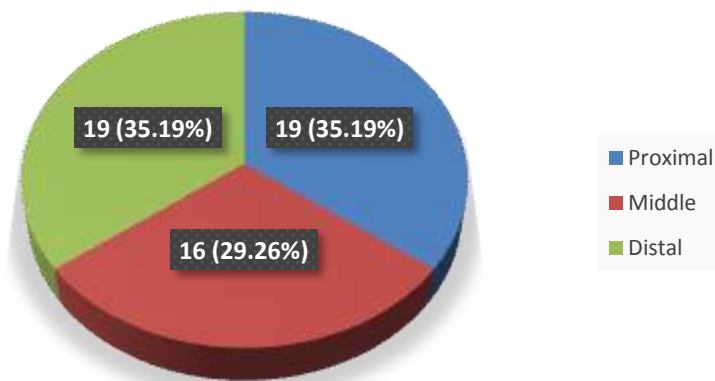


Fig 3: Anatomical site of injury

This shows that the fracture most commonly involves the proximal 19 (35.19) and middle 19 (35.19) portion of the femoral shaft respectively

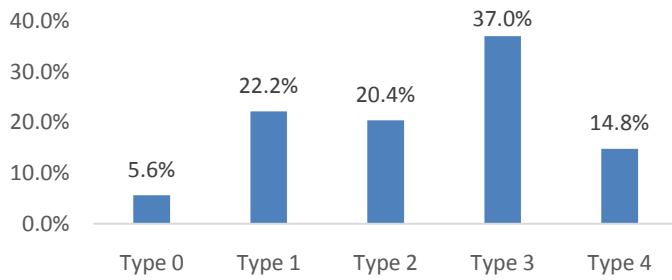


Fig.4 Winquist Hansen’s classification of the femur fractures

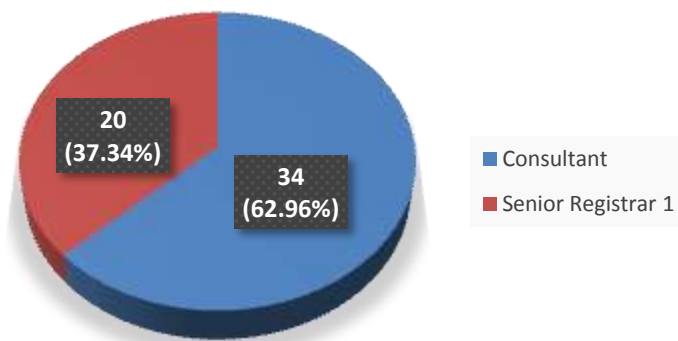


Fig 5: Status of the surgeon

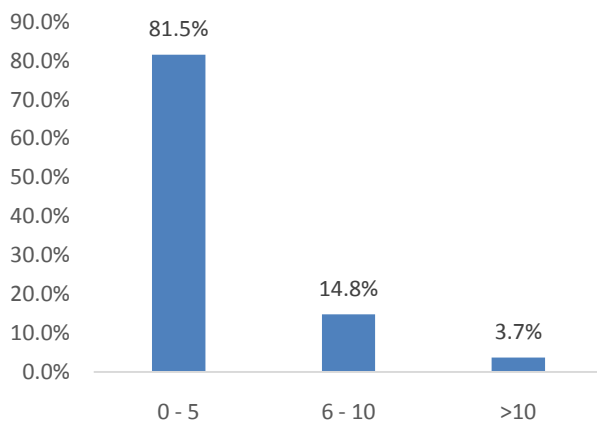


Fig. 6 Interval between Admission and Surgery

Table 4. Radiographic union over the study period

Radiographic Union (Number of Cortices with callus)	6 weeks	12 weeks	18 weeks	24 weeks
	n (%)	n (%)	n (%)	n (%)
1	31 (57.4)	5 (9.3)	0 (0.0)	0 (0.0)
2	23 (42.6)	16 (29.6)	3 (5.6)	1 (1.9)
3	0 (0.0)	29 (53.7)	31 (57.4)	3 (5.6)
4	0 (0.0)	4 (7.4)	20 (37.0)	50 (92.6)

Table shows the radiographic union with time to first callus formation was at 6th week post operative and 92.6 percent had four cortices bridged by 24 weeks. The average fracture union time was 18.88 ± 4.69 weeks.

Table 13: Knee range of motion over the study period

Knee Range of motion	2 weeks	6 weeks	12 weeks	18 weeks	24 weeks
	n (%)	n (%)	n (%)	n (%)	n (%)
< 90 degree flexion	11 (20.4)	10 (18.5)	10 (18.5)	11 (20.4)	13 (24.1)
91 – 110 deg flexion	8 (14.8)	5 (9.3)	4 (7.4)	3 (5.6)	4 (7.4)
111 – 135 deg flexion	10 (18.5)	13 (24.1)	12 (22.2)	7 (13.0)	4 (7.4)
>135 deg flexion	25 (46.3)	26 (48.1)	28 (51.9)	33 (61.1)	33 (61.1)

Table 5. Association between Knee stiffness and Approach of femur fixation

Knee Range of Motion	Approach to the femur		χ^2	P value
	Antegrade n (%)	Retrograde n (%)		
2 weeks				
<90 degree flexion	10 (24.4)	1 (7.7)	20.386	< 0.001
91 – 110 deg flexion	3 (7.3)	5 (38.5)		
111 – 135deg flexion	4 (9.8)	6 (46.2)		
>135deg flexion	24 (58.5)	1 (7.7)		
6 weeks				
<90 degree flexion	9 (22.0)	1 (7.7)	26.814	< 0.001
91 – 110 deg flexion	4 (9.8)	1 (7.7)		
111 – 135deg flexion	3 (7.3)	10 (76.9)		
>135deg flexion	25 (61.0)	1 (7.7)		
12 weeks				
<90 degree flexion	9 (22.0)	1 (7.7)	15.730	0.001
91 – 110 deg flexion	3 (7.3)	1 (7.7)		

111 – 135deg flexion	4 (9.8)	8 (61.5)		
>135deg flexion	25 (61.0)	3 (23.1)		
18 weeks				
<90 degree flexion	9 (22.0)	2 (15.4)	2.512	0.473
91 – 110 deg flexion	3 (7.3)	0 (0.0)		
111 – 135deg flexion	4 (9.8)	3 (23.1)		
>135deg flexion	25 (61.0)	8 (61.5)		
24 weeks				
<90 degree flexion	10 (24.4)	3 (23.1)	1.462	0.691
91 – 110 deg flexion	4 (9.8)	0 (0.0)		
111 – 135deg flexion	3 (7.3)	1 (7.7)		
>135deg flexion	24 (58.5)	9 (69.2)		

Table shows there is a statistically significant difference in the approach to fixation and post operative knee stiffness at 2, 6 and 12 weeks, however there was a gradual improvement in the range of motion with time showing no significant difference in the antegrade and retrograde approaches at 18 and 24weeks. Antegrade (58.5%) and Retrograde (69.2%) had excellent outcome at 24weeks.

IV. Discussion:

The operative fixation of 54 closed femoral shaft fractures using SIGN locking IM nailing showed the short term outcome using fracture union, healing time and complication rate as outcome parameters. There was a male preponderance 32 (59.3%) with a male to female ratio of 1.4: 1. This is similar to the report by Anyaehie et al in their study on the Pattern of femoral fractures and associated injuries in a Nigerian tertiary trauma centre in Enugu. They reported a ratio of 1.8:1.⁷ although, the ratio is lower than 6:1 reported by Salawu in Zaria.³⁰ These differences are probably due to the influence of the population being studied on the distribution of adult femoral shaft fractures³⁰ and the overall male higher activity levels than females. Femoral shaft fractures occur most commonly within 21-40 years with a peak age of 21-30 years. This is similar to the findings by Felix⁵⁹, Katchy et al⁶⁰ and Oginni et al⁶¹ where the most commonly involved age bracket was also found to be

21-45 years.⁵⁹⁻⁶¹This age groups constitute the young active work force in the region.⁷

The majority of patients were traders with 14 (25.9%), possibly because of the predominance of road travels to buy and sell their goods which increases their risk of RTA. Motor vehicle accident 17 (31%) accounted for the major cause of femoral shaft fractures in this study comparable to other reports in which 62.8 percent were due to RTAs.^{7,63} Salawu in Zaria also found that road crashes accounted for 69 (97%) of the cases he studied.³⁰This is perhaps because of the poorly maintained roads and reckless disregard to traffic rules.⁷

In concordance with a previous study the majority of fractures were in the proximal and middle third of the femoral shaft 19 (35.19%) respectively. The reason why the mid-shaft is the most common part to fracture may be because it is the most exposed and extensive part that receives impact when there is trauma.⁷

There was a higher prevalence of Winkvist-Hansen type 3 fractures (35.2%), this is corroborated in a similar study by Felix in Tanzania.⁵⁹The majority of fractures were fixed using the antegrade approach (75.92%) this is due to the predominance of proximal and mid shaft fractures which are treated preferably using the antegrade approach.⁵On the contrary, Faseeh reported more retrograde femur nailing 13 (59%) than antegrade 9 (41%) in their study.⁶⁷The average duration of hospital admission in this study was 12.5 ± 4.92 days which agrees with the report by Van Niekerk et al in their series.⁶⁹ This may be due to the variability in the pattern and severity of associated injuries in the patients studied which plays a key role in the extent of initial treatment and rehabilitation of the patient.

Fracture union and healing time

A fracture union of 98.2 percent at 24 weeks with mean union time of 18.88 ± 4.69 weeks was found in this study. This is within the estimated adult femoral shaft fractures healing time of 12 – 24 weeks documented earlier.^{3,4,26} Naeem et al reported fracture union in 97.83% at 32 weeks after surgery with mean union time of 19.65 ± 5.69 weeks in the treatment of femoral shaft fractures with SIGN nail.³²Similarly, Sultan et al followed up patients with comminuted femoral shaft fractures treated with closed Interlocked nailing and reported an average time to union of 34 weeks.²²The fracture union observed in this study reveals that femoral shaft fractures heal fast when SIGN IM nail is used.

Complications

Surgical site infection rate:

This study reported superficial surgical site infection in 3 (5.6%) patients and *staphylococcus aureus* was the only organism cultured. The superficial wound infections resolved completely following culture sensitive antibiotic therapy and wound dressing. The SSI rate is higher than the rates of 0%, 0.1% and 0.4% reported by Sojberg et al, Faseeh and Winkvist et al respectively in their series.^{64,66,67} Faseeh also reported staphylococcus aureus as the culture result in their study.⁶⁷ The observed infection rate may be associated with the open reduction technique used in all cases in this study while the other studies used mainly closed reduction technique for the fracture fixations.

Limb Length Discrepancy:

5.6 percent had clinically significant shortening of more than 2cm. This is at variance with the report of limb shortening of 2 to 3cm in 3.8% of patients in a similar study in Tanzania. Shortening in the lower limb less than or equal to 2cm is not significant as patients have been reported to cope with their activities of daily living without distress and they can be managed conservatively. The Thoresen's score for limb length discrepancy less than 2cm has a good to excellent outcome. 96.2 percent of patients in this study had excellent or good limb length outcome. The high proportion of comminuted fractures in this study may be a factor. Improved limb length outcome by maintaining traction after aligning fracture fragments and before locking.⁷

Angular and Rotational Malignment

Varus deformity greater than 5 degrees occurred in 2 (3.7%) of patients and internal rotational malalignment of more than 10 degrees was encountered in 1 (1.9%). According to Thoresen's score 94.4% of patients had excellent limb alignment outcome. Winkvist et al reported rotational deformity of more than 10 degree in 2.3% of their patients.²⁷ Felix reported 7.9% of internal rotation of more than 15 degree with 76.3% excellent limb alignment outcome score using the Thoresen criteria.⁷

Knee stiffness:

There was a progressive improvement on the knee range of motion over time. Majority of patients 61.1 percent had excellent outcome. Knee flexion of less than 90 degrees was reported in 38.9% of the patients in this study. This was higher than 7.5% reported by Felix and Sojberg et al respectively in their separate studies.^{37, 59} This may be due to poor compliance to physiotherapy rehabilitation protocol in our patients as a

result of lack of proximity to a physiotherapy centre. There was a statistically significant difference in the rate of knee stiffness between patients with antegrade and retrograde approaches ($\chi^2 = 20.386$, $P = < 0.001$). Knee stiffness was significantly higher among patients treated with antegrade approach compared to those with retrograde nailing at the 2nd, 6th and 12th week visit but there was no significant difference observed at 18th week ($P = 0.473$) and 24th week ($P = 0.691$). This is an uncommon finding in comparison to earlier studies which showed greater knee stiffness in the retrograde group.^{13,37,43} Majority of the fractures were fixed using the antegrade approach (75.92%) due to the predominance of proximal and mid shaft fractures in this study. However this was contrary to Faseeh et al who reported 3 cases of knee stiffness and all had retrograde nailing.⁵⁹ This is divergent to the finding of Sjøbjerg et al who reported that 7.5% of patients with knee flexion of 60 to 90 degrees,³⁷ Wiss et al reported that no patient had knee flexion contracture and 2 (0.06%) patients had less than 90 degrees knee flexion.¹³ This variation in the knee stiffness may be due to the late hospital presentation following injury as 3.7 percent of patients presented beyond ten days following injury and the long interval between injury and surgery due to limitation of funds by the patients. The lack of regular knee range of motion exercises in this setting due to patients' non compliance and paucity of continuous passive motion machines are notable contributory factors. The Thoresen grading showed a progression from fair to good and excellent outcome between two to twenty four weeks. It is advised that all patients should be counseled about the possibility of knee stiffness and knee range of motion exercises commenced as soon as patient is able to tolerate irrespective of the nailing technique. This emphasizes the importance of knee range of motion exercises in both antegrade and retrograde nailing techniques.

V. Conclusion

SIGN nailing is an effective treatment for femoral shaft fractures in resource poor settings where image intensifiers and fracture tables are not readily available. The mean time to fracture union of fresh closed femoral shaft fracture treated with SIGN IM nail is 18.88 ± 4.69 weeks. Knee stiffness is a common complication irrespective of the nailing technique.

Reference

- [1]. Canale S T, Beaty J H. Campbell's operative orthopaedics: fractures of lower extremity. 11th ed. Philadelphia: Mosby, An Imprint of Elsevier; 2008. P.2825-72.
- [2]. Starr A.J, Bucholz R.W. Fractures of the shaft of femur. Chapter- 41, Rock Wood & Green's Fractures in Adults, 5th Edn., Vol. 2, Lippincott Williams and Wilkins, 1683-1730.
- [3]. Dim EM, Ugwuegbulem OA, Ugbeye ME. Adult traumatic femoral shaft fractures: a review of the literatures. Ibom medical journal 2012; 5(1): 26-38.
- [4]. McGuigan F.X. Skeletal trauma. Chapter 2, Essentials of Orthopaedic Surgery. Fourth edition. Springer, 2010 pg. 35-73
- [5]. Zirkle LG. Technique manual of SIGN IM and interlocking screw system insertion and extraction guide. 2012 November 03; 26-33.
- [6]. Ikpeme I, Ngim N, Anthony U, Obiora O, Okokon E and Segun B ;External jig-aided intramedullary interlocking nailing of diaphyseal fractures: experience from a tropical developing centre; Int Orthop. Jan 2011;35(1): 107-111
- [7]. Anyaehie UE, Ejimofor OC, Akpuaka FC, Nwadinigwe CU. Pattern of femoral fractures and associated injuries in a Nigerian tertiary trauma centre. Nigerian Journal of clinical practice. 2015, Vol.18: 4 Pg:462-466.
- [8]. Soren OO. Outcome of surgical implant generation network nail initiative in treatment of long bone shaft fractures in Kenya. East Afr Orthop J. 2009;3:8-14.
- [9]. Salawu SAI. Interlocked medullary nailing of femur and tibial shaft fractures at the National Hospital Abuja: The journey so far, Nig. Journal of Ortho and Trauma. 2010;9(2):45 - 46
- [10]. Waqar H, Ghulam A, Mahmood-ul H. Treatment of Nonunion of Long Bone Fractures with The Surgical Implant Generation Network nail. J of Surg. Pakistan Int. 18 (2) April- June 2013.
- [11]. Ikem IC, Ogunlusi JD, Ine IR. Achieving interlocking nail without use of image intensifier. Int Orthop. 2007; 31:487-90.
- [12]. NOHE EMD registry books. 2014-15
- [13]. Wiss DA; Fleming CH; Matta J M; Clark D. Comminuted and Rotationally Unstable Fractures of the Femur Treated with an Interlocking Nail. Clinical Orthopaedics & Related Research. Nov. 1986.212:35-47
- [14]. Tüzüner T, Subaşı M, Kapukaya A, Necmioğlu NS. Treatment of femoral shaft fractures with interlocking intramedullary nailing. Acta Orthopaedica Traumatology Turkey. 2002; 36(3):211-9.
- [15]. Borel JC, Dujardin F, Thomine JM, Biga N. Closed locked nailing of complex femoral fractures in adults: Apropos of 68 cases. Rev Chir Orthop Reparatrice Appa 1993;79(7):553-64
- [16]. Deshmukh RG, Lou KK, Neo CB, Yew KS, Rozman I, George JA technique to obtain correct rotational alignment during closed locked intramedullary nailing of the femur. Injury 1998 Apr;29 (3):207-10.
- [17]. Johnson KD, Johnston DWC, Parker B. Comminuted femoral-shaft fractures: treatment by roller traction, cerclage wires and an intramedullary nail or an interlocking intramedullary nail. Journal Bone Joint Surg. (Am) 1984;66-A:1222- 35
- [18]. Shearer D, Eliezer E, Haonga B, Morshed S. The Design of a Prospective Observational study to evaluate the outcome of operatively treated femoral shaft fractures in the sub-saharan Africa; Int'l Research studies, 2013 paper 2.
- [19]. Kyle RS, Daniel G, Duane A, Kiprono GK, Paul W, Micheal M, Douglas WL. Management of closed femur fracture with SIGN IM nail in to developing African countries; Int'l Research Studies, 2013, paper 20.
- [20]. Fadero PE, Alabi S, Adebule GT, Odunubi OO, Yinusa W, Eyesan SU, Obianyor OD. Locked intramedullary nailing for the treatment of femoral shaft fractures: experience and result in 19 cases. Niger J Med. 2008 Apr-Jun;17(2):168-72.

Oguzie G.C, et. al. "The Short-term Outcome of Femoral Shaft Fractures Treated with SIGN Intramedullary Nail in a Nigerian Tertiary Institution." *IOSR Journal of Dental and Medical Sciences (IOSR-JDMS)*, 22(2), 2023, pp. 17-21.