

Analysis of Renal Specimens with Histopathology in South Tamilnadu Tertiary Care Hospital

Dr.R.Nagaraj MS, MCh uro Assistant professor urology Govt.medical college and hospital, Dindigul
Dr.R.Umasamundeeswari MD, Associate Professor in Pathology Govt.medical college and hospital,
Dindigul

Dr.Chandramurali, Ms, Mch uro, Senior resident Urology, Government medical college and hospital,
Dindigul

Corresponding author Dr.V.Nithyananthinie, MD, DNB Pathology Assistant Professor Pathology,
Govt.medical college and hospital, Dindigul

ABSTRACT

Kidneys-being the major organs in the body are resected for various reasons including malignancy and nonfunctioning status of the organ, leading to severe morbidity and decrease in quality of life of the people, especially in south Tamil nadu where the people are extreme laborers and belong to poor socioeconomic status. So, this study aimed at collecting the major causes of nephrectomy being done and sorting out the preventive aspects that can be instituted in the general public.

AIM

To analyse the histopathological reports of the nephrectomy specimens this study was aimed at deriving the data that reveals the major pathological diagnosis with respect to the nephrectomies done in a medical college and hospital catering to rural population in south Tamilnadu. Also to know the age and sex frequencies of the malignant and nonmalignant conditions of the nephrectomy specimens.

Materials and methods:

Retrospective analysis of the histopathological reports of the nephrectomy specimens from the hospital collected and data analysed based on gender, age, preoperative diagnosis and postoperative histopathological diagnosis.

Results:

Analysis reports that most of the nephrectomy was done for nonmalignant conditions like nonfunctioning status of the kidneys, mostly due to chronic pyelonephritis- which is a complication of sepsis untreated and chronic obstruction along with diabetes mellitus. Only second to it comes the malignant causes like clear cell renal cell carcinoma in the district.

CONCLUSION

The study concludes the top cause to be malignant seconding chronic pyelonephritis, directing the need to early detection and control of diabetes mellitus, avoiding sepsis and infections.

Key words: nephrectomy, malignancy of kidney, chronic pyelonephritis

Date of Submission: 13-02-2023

Date of Acceptance: 26-02-2023

I. Introduction

One of the major vital organs in the body, the kidneys, essential for the excretion of the metabolic wastes maintaining the hemodynamics, metabolic equilibrium including electrolyte balance pH control and calcium maintenance. Also the source of erythropoietin which determines the oxygen carrier of the body-the red blood cell production. Calcium homeostasis maintains our body framework and prevents osteoporosis related events. Hormones secreted from the kidney plays vital part in maintaining blood pressure as the blood traverses through this organ atleast 10-12 times a day for purification and reinstallation of vital elements, thus it removes the unwanted substances and reabsorbs the essential chemicals, the basic building materials needed for the effective functioning of the body and neutralizing the homeostasis, the two kidneys are another lifeline for the humans.¹¹

But circumstances lead to the removal of the organ whenever there is a mass growing within it or the functioning is not adequate and the kidneys are damaged by diseases which need surgical exploration and restoration. Sometimes when not done can lead to the death of the individual.

Major causes for surgical removal include chronic pyelonephritis in nonmalignant conditions and renal cell carcinoma on the malignant side.¹¹

AIM: this study was aimed at deriving the data that reveals the major pathological diagnosis with respect to the nephrectomies done in a medical college and hospital catering to rural population in south Tamilnadu. Also to know the age and sex frequencies of the malignant and nonmalignant conditions of the nephrectomy specimens.

II. Materials And Methods:

A retrospective study analysing the data of pathological reports between January 2018 and December 2022 in Government medical college and Hospital, south Tamil Nādu. A total of 49 cases which included all nephrectomy specimens received in the pathology department were included in the study.

Renal biopsies and traumatic removal of kidneys were excluded from the study.

Ethical committee approval was obtained from the authorities.

Received specimens were fixed in 10% buffered formalin for 24 hours and grossing done to note the macroscopic picture. Bits taken from the pathological sites and subjected for tissue processing in graded alcohol and xylene. Sections cut and stained with routine haematoxylin and eosin. Slides were examined by the pathologists individually and fuhrmans nuclear grading given for the relevant cases.

III. Results:

A total of 49 cases were taken up for the study which show that nephrectomy has been a significant proportion of the surgical cases done in the tertiary care hospital.

Out of the 49 cases 57% of cases are dominated by the male population with maximum number of 28 cases out of the 49. 42% of cases contributed by the female population with 21 of them.

Taking up the age limits, males the eldest was 78 year old and the youngest was 18 years old.

Of the females the eldest was 70 year old and the youngest was 22 year old.

When analysing the pathologies and age distribution, it was found that nonmalignant lesions were found in females with youngest age being 22 years -a case of pyelonephritis with abscess and the oldest was 70 years with chronic pyelonephritis.

The malignant lesions showed the youngest of the females to be 35 years with chromophobe variant of renal cell carcinoma and the oldest being 70 years WITH CLEAR CELL RENAL CELL CARCINOMA WITH SARCOMATOID DIFFERENTIATION.

The male population showed highest age to be 75 years in nonmalignant category -chronic pyelonephritis and 78 years a case of clear cell carcinoma in the malignancy category. Also it was found that the lowest age in males was a 39 year old with Clear cell renal cell carcinoma in the malignant list and an 18 year old with chronic pyelonephritis in the nonmalignant category- revealing the high prevalence of pyelonephritis in the middle age group rather than elderly.

Regarding the pathology, 29 cases were found to be benign/non malignant forming 57% of the cases predominating to be of infective/ inflammatory pathology. The remaining 20 cases are malignant forming 43% to be of renal cell carcinoma and other variants.

Pathologically the nonmalignant cases leads with chronic pyelonephritis forming 51% of the cases and with degenerative changes like calcification 1 case and abscess formation 1 case. Xanthogranulomatous pyelonephritis being the second of nonmalignant with 3 cases. The malignant list is lead by clear cell renal cell carcinoma forming 16 cases which also show sarcomatoid change in 3 cases. Papillary variant observed in 1 case. Rare presentation of leiomyosarcoma was observed in 1 case and I case showed angiomyolipoma which was the youngest of the females. Chromophobe Renal cell carcinoma also was reported in 2% of the cases adding to the variants of renal cell carcinoma.

Fuhrman`s nuclear grading was given based on the nuclear features individually by the pathologists for each concerned case and verified. The highest nuclear grading was grade 3 with the clear cell carcinoma showing sarcomatoid changes.

IV. Discussion:

The spectrum of diagnosis for the nephrectomies done including benign/nonmalignant and malignant conditions in the tertiary care centre in south Tamilnadu ranging from chronic pyelonephritis with abscess formation, xanthogranulomatous pyelonephritis to clear cell variant of renal cell carcinoma, with sarcomatoid changes, papillary variant of renal cell carcinoma, leiomyosarcoma of kidney and chromophobe renal cell carcinoma.

Chronic pyelonephritis is the complication of chronic untreated infection of the renal parenchyma with inflammatory cell infiltration, fibrosis and scarring of the organ leading to derangement of organ function, compelling to remove the organ.¹¹ A variant of this condition is the xanthogranulomatous pyelonephritis resulting from E. coli, Klebsiella and Proteus infection leading to gross changes mimicking renal cell

carcinoma. Microscopically parenchyma is replaced by chronic inflammatory cell infiltration with foamy histiocytes, neutrophils and eosinophils.^{10,8}

Malignant lesions when analysed, the most common and first on the list is renal cell carcinoma-clear cell variant with sarcomatoid differentiation.^{8,7} Presenting as variegated well defined mass in the poles of the kidney and detected by USG or CT and confirmed with MRI, nephrectomy is the treatment of choice. Microscopically there are sheets of clear cells with regular round nucleus and inconspicuous nucleoli along with mitosis and necrosis, the Fuhrman nuclear grading is used to define the tumors for appropriate staging and need to check the renal veins for thrombo embolic phenomenon. Some of them also show minimal to abundant pleomorphism in the stromal cells accompanying resulting in sarcomatoid change, which can also show calcification and osseochondrous metaplastic changes.^{7,8}

Papillary variant of RCC-comprising of c-MET oncogene germline mutations in contrast to VHL gene mutation of clear cell variants show well defined papillary branching architecture of renal epithelial cells with psammoma bodies-also metastatic calcification changes.⁶

When analysing similar studies by Ankit vyas et al done in a similar environment but a high volume tertiary care centre, also reveals lead of non Malignant cases with 68 % of which renal stones were the first in the list and followed by pyelonephritis with 32% . the malignant cases formed about 17% of the cases with the lead by RCC forming 13% of the cases with inferior vena cava thrombosis and metastatic deposits .³

In another similar study by Thakur.A.S and others in a similar town of India has included 54nephrectomy specimens. But a slight change in the pathology of neoplastic lesions leading with 38 cases forming 70% and nonneoplastic being 16 cases with 29% of the 54 cases. Among the nonneoplastic similar results with lead by chronic pyelonephritis was observed and neoplastic also lead by RCC and its variants were observed.¹⁴

In the study over a ten-year period in a south Indian tertiary hospital, where total of 177 cases were taken up and 64 were found to be neoplastic and 113 non neoplastic like the current study. Among the 177 cases 96 male patients and 81 female patients which includes youngest being 5month old infant with Wilms tumor an the oldest being 80year old with RCC. Other causes of nonneoplastic conditions included hydronephrosis, xanthogranulomatous pyelonephritis, tuberculosis, chronic interstitial nephritis and simple renal cysts.⁴

Almost many studies from Ghayani et al-70.44%, Rafique et al-76.6% and Kishor H.Suryawanshi et al 75.76% show similar results to the present study with nonneoplastic lesions being the leading cause of nephrectomy specimens.

Few studies also like Vikram Narang et al and swarnalata Ajmera et al show that neoplastic lesions are the leading cause of the nephrectomies.

V. Conclusion:

Thus the implication in the study area also shows that the major cause of nephrectomy is due to chronic pyelonephritis and the neoplastic cause is due to Renal cell carcinoma in various patterns with the least occurrence of angiomyolipoma. Non malignant lesions can be tackled at the early stage of the diseases by controlling other risk factors like diabetes, infections, etc. henceforth avoiding the necessity of nephrectomy and its complications.

FUNDING: NIL

CONFLICTS OF INTEREST: NIL

References:

- [1]. Histopathological study of nephrectomy specimens in a tertiary care hospital; Nilay Shah, Sunita Goyal*; IP journal of diagnostic pathology and oncology Volume : 4, Issue : 1, Year : 2019; 39-44
- [2]. SPECTRUM OF LESIONS IN NEPHRECTOMY SPECIMENS IN TERTIARY CARE HOSPITAL; Journal of Evolution of Medical and Dental Sciences September 2015 10.14260/jemds/2015/1832
- [3]. Nephrectomy – A study of recent trends in a high-volume tertiary care center, exploring the need for screening and preventive strategies; Asian Journal of Medical Sciences, February 2022, 13(2):65-68; 10.3126/ajms.v13i2.40434- Ankit vyas et al
- [4]. Histopathology of nephrectomy specimens: A ten year south Indian tertiary hospital based study, Chaitra B, PremaLatha P, Tejeswini V, Haritha O, Anusha ,Volume : 3, Issue : 3, Year : 201; 232-236
- [5]. Alpers CE. The Kidney. In: Kumar V, Abbas AK, Fausto N, Aster JC, editors. Robbins and Cotran pathologic basis of disease. 8th ed. Philadelphia: WB Saunders, 2010; pp 905-70.
- [6]. Urologic pathology by Robert.O.Peterson, Isabel.A.Sesterhann-3rd edition
- [7]. Rosai and Ackerman's Surgical Pathology by Juan Rosai-tenth edition-volume 1:1160-1178
- [8]. Rosai and Ackerman's surgical pathology by Juan Rosai-tenth edition-Volume -1:1183-1193
- [9]. Algaba F, Delahunt B, Berney DM, et al
- [10]. Handling and reporting of nephrectomy specimens for adult renal tumours: a survey by the European Network of Uropathology Journal of Clinical Pathology 2012;65:106-113.
- [11]. Sternberg's Diagnostic Surgical pathology-Stacey .E.Mills-fifth edition-chapter 41 and 42
- [12]. Robbins pathologic basis of diseases-9th edition-Kumar, Abbas and Cotran-South asia edition

- [13]. Datta B, Moitra T, Chaudhury DN, Halder B. Analysis of 88 nephrectomies in a rural tertiary care center of India. Saudi J Kidney Dis Transpl. 2012 Mar;23(2):409-13. PMID: 22382250.
- [14]. Siddappa, Sujatha. (2018). Histopathological Spectrum of Nephrectomy Specimens: Single Center Experience. Biomedical Journal of Scientific & Technical Research. 6. 10.26717/BJSTR.2018.06.001350.
- [15]. Singh Thakur, D.A., Gahine, D.R., &Banjare, D.B. (2019). A Histopathological spectrum of nephrectomy specimens in a tertiary hospital of Raipur city (C.G.) India. *Tropical Journal of Pathology and Microbiology*.
- [16]. **Histopathological spectrum of lesions in Nephrectomy specimens in a tertiary care hospital in North India** Anu Gupta, Subhash Bhardwaj: <https://dx.doi.org/10.18535/jmscr/v8i2.144>

TABLES AND FIGURES

TABLE 1 FREQUENCY OF AGE WITH NEPHRECTOMY LESIONS

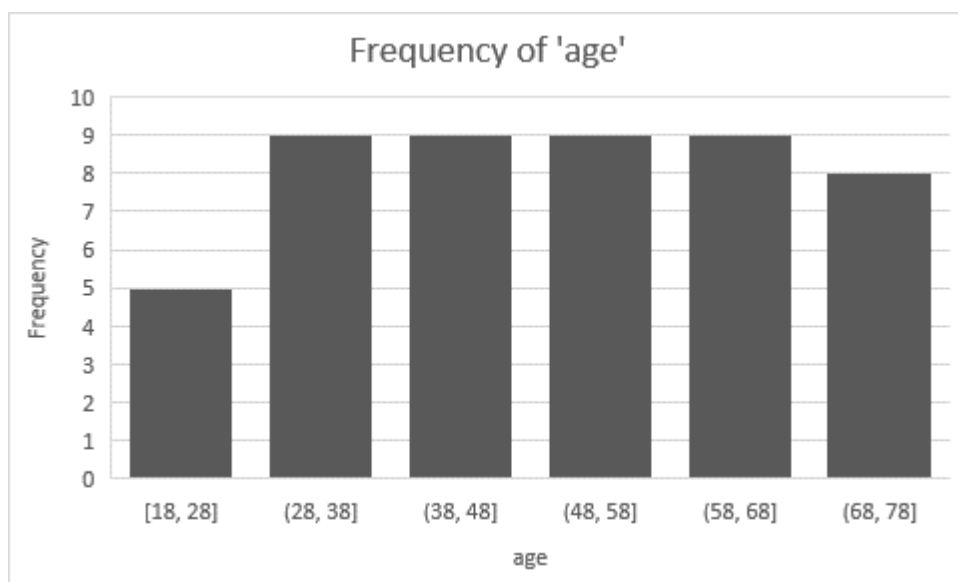


TABLE 2 DIAGNOSIS AND NUMBER OF CASES

S.NO.	DIAGNOSIS	NO. OF CASES	PERCENTAGE
1.	CHRONIC PYELONEPHRITISS	22	44.89
2.	XANTHOGRANULOMATOUS PYELONEPHRITIS	5	10.2
3.	PYELONEPHRITIS WITH ABSCESS	1	2.04
4.	CHRONIC PYELONEPHRITIS WITH CALCIFICATION	1	2.04
5.	CLEAR CELL RENAL CELL CARCINOMA	15	30.62
6.	PAPILLARY RENAL CELL CARCINOMA	1	2.04
7.	CLEAR CELL RCC WITH SARCOMATOID DIFFERENTIATION	1	2.04
8.	ANGIOMYOLIPOMA	1	2.04
9.	CHROMOPHOBE RCC	1	2.04
10.	LEIOMYOSARCOMA	1	2.04

TABLE 3 NO. OF CASES AS BENIGN AND MALIGNANT

NATURE OF LESION	NO. OF CASES N=49	PERCENTAGE
BENIGN/NONNEOPLASTIC	29	59.18
MALIGNANT	20	40.82
TOTAL	49	100

TABLE 4 NO. OF CASES DISTRIBUTED BASED ON SEX

SEX	NO. OF CASES N=49	PERCENTAGE
MALE	28	57.14
FEMALE	21	42.85
TOTAL	49	100

IMAGES:

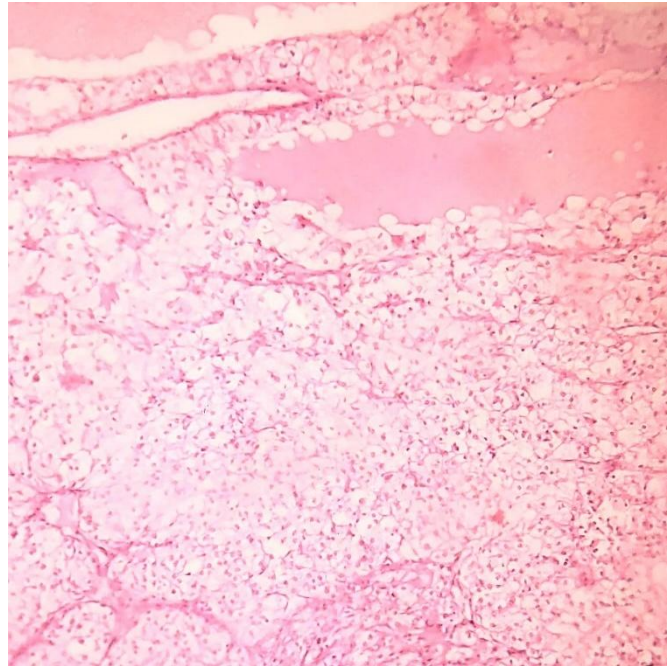


Fig.1. RENAL CLEAR CELL CARCINOMA 10X magnification H&E STAIN

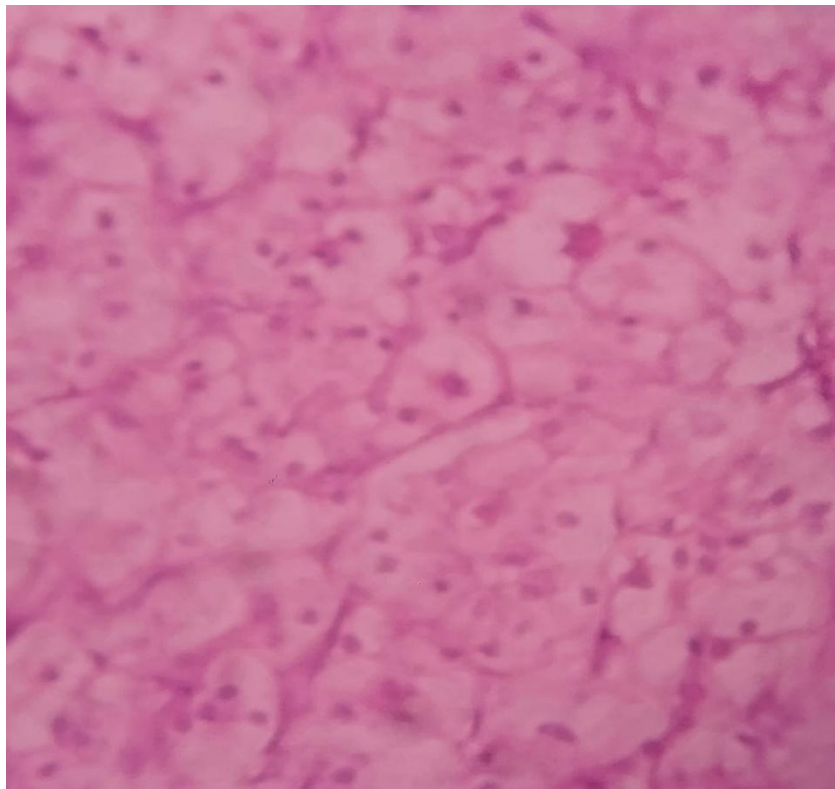


Fig.2 CLEAR CELL RCC 40X magnification H&E STAIN

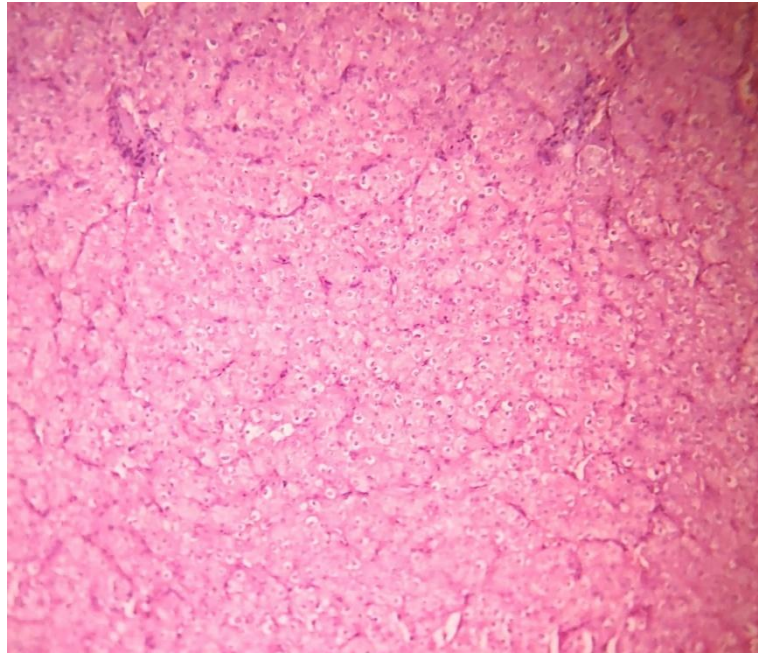


FIG.3 CHROMOPHOBE RCC 10X magnification-H&E STAIN

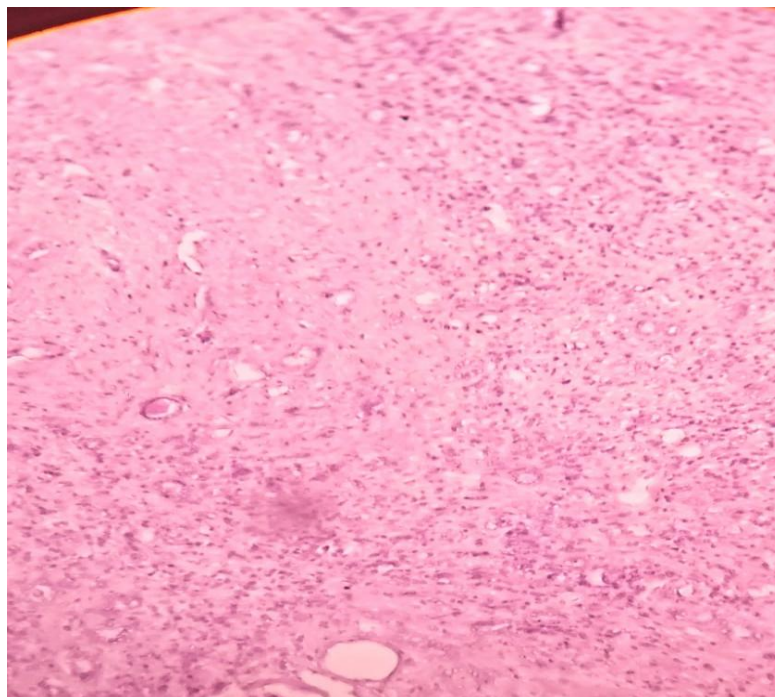


Fig.4 CHRONIC PYELONEPHRITIS 10X magnification H&E stain

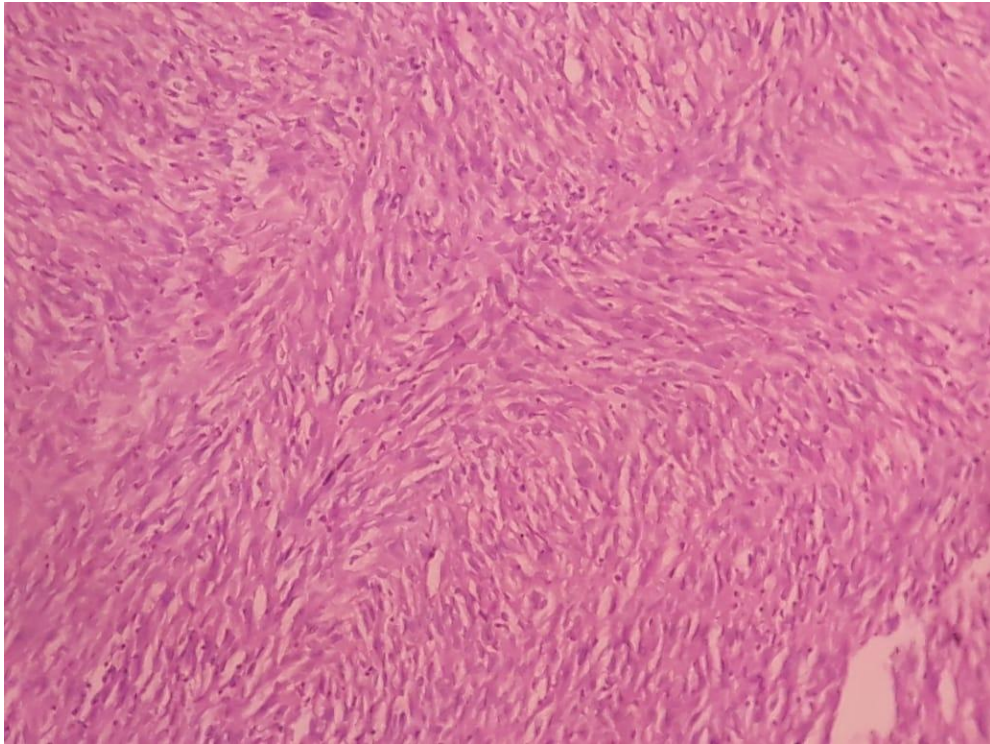


FIG.5 LEIMYOSARCOMA KIDNEY—10X magnification- H&E stain

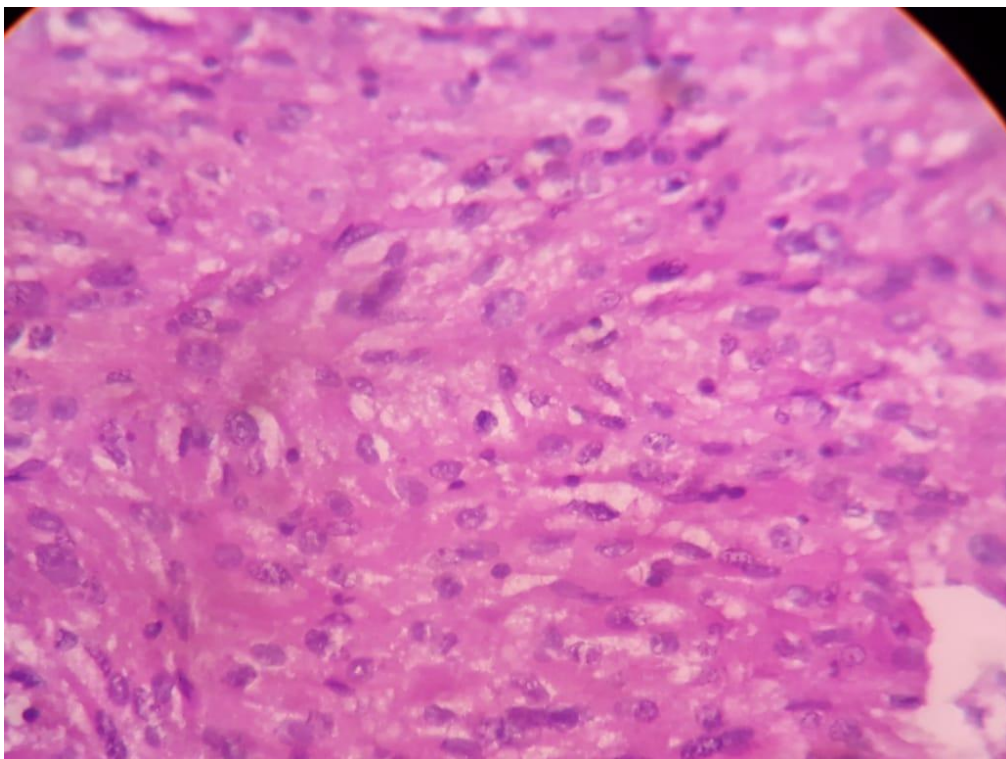


FIG.6 LEIOMYOSARCOMA KIDNEY-40X magnification-H&E STAIN

Dr.R.Nagaraj MS, et. al. "Analysis of Renal Specimens with Histopathology in South Tamilnadu Tertiary Care Hospital." *IOSR Journal of Dental and Medical Sciences (IOSR-JDMS)*, 22(2), 2023, pp. 12-18.