

“Role of Multidetector Ct in Diagnosis of Incidental Adrenal Lesions (Adrenal Incidentaloma)”

Dr.Kishan Soni

(3rd year Resident Doctor in SMIMER medical college, Surat).

1. Dr.Nirav Kadvani (Assistant professor ,SMIMER medical college, surat)
2. Dr.Mona Shastri (Professor and Head of Department, SMIMER medical college, surat)
3. Dr.Avani Bhatt (Senior resident,,SMIMER medical college, surat)
4. Dr.Yash Pandit (3rd year resident Doctor ,SMIMER medical college, surat)
5. Dr.Shripal Chauhan (2nd year resident Doctor,SMIMER medical college, surat)

Aims & Objectives: -

- ◆ To investigate the frequency of adrenal lesions incidentally detected in contrast enhanced CT scan for some other clinical indication
- ◆ To further investigate radiological and biochemical characteristics of the detected adrenal lesions if clinical indication warrants for the same.

Material and Methods: -

Observational study was carried out in Department of Radio-diagnosis, SMIMER, Surat.

This study was carried out on patients during the study period of 18 months.

CT examinations were performed by using a 16 slice multidetector CT system (Philips mx) and the following acquisition parameters were used: slice thickness 0.5 mm, and increment 0.5 mm, rotation time 0.5 s.

In all cases, images were acquired before and after intravenous injection of contrast material (Iohexol), injected in a quantity equal to 1.5 mL per kg of body weight, up to a maximum of 120 mL, at a flow rate of 3.5 mL per second. Scans were performed in the portal venous phase (50–60 seconds after the injection of contrast material) and in the late phases.

In order to calculate the APW and RPW values, the following formulas were used, respectively: $APW = 100 \left(\frac{[EA-DA]}{[EA-PA]} \right)$; $RPW = 100 \left(\frac{[EA-DA]}{[EA]} \right)$, where EA = early-phase postcontrast attenuation; DA = delayed-phase postcontrast attenuation; PA = precontrast attenuation. An APW of more than 60% and an RPW of more than 40% were considered significant for adenoma, independently from the used scan delay [12].

Inclusion criteria:

- ◆ Patients who underwent CT scan of abdomen for a different clinical indication and incidentally diagnosed with a adrenal lesion. Cases of all age groups irrespective of sex to be included in the study.
- ◆ Only those patients willing to participate and given informed consent for the study were included.

Exclusion criteria:

- ◆ Patient not willing to participate in the study.
- ◆ Patients with previously diagnosed adrenal pathology or Endocrinopathy.

Result –

In our study out of 25 patient majority of the patient were male (n=16)(67%),there are 8(33%) female patients.The most common age group in our study is 31-40 yrs (n =6 , 25 %).The most common lesion in our study was adrenal adenoma (n=8, 33%) followed by metastasis (n=4, 16.6%). Adrenal neoplasm of primary origin , Pheochromocytoma and adrenal calcification has least number of cases (n=1).There were 2 cases of chemically active lesion one of each from adrenal adenoma and pheochromocytoma.

Conclusion -

- ◆ The combination of a lower threshold value at unenhanced CT and a 15-30 minute delayed imaging may improve the sensitivity and specificity for diagnosing adrenal lesions in patients with or without history of malignant disease.
- ◆ We found that of the patients without any history of malignancy or any related clinical symptoms almost all patients had radiologically benign lesions.
- ◆ Of all the benign lesions we found that at detection of small percentage of our adrenal study patients had hypersecretory lesions

- ◇ Small fraction had incidentally detected malignant adrenal lesion. Metastatic lesions were detected in cases of primary malignancy from lung, prostate and testis.
- ◇ Radiological follow-up of adrenal lesions still has a place for indeterminate lesions

Keywords: -

Adrenal adenoma, adrenal computed tomography, adrenal cortical carcinoma, adrenal incidentaloma, autonomous cortisol secretion, pheochromocytoma, angiomyolipoma.

Date of Submission: 13-02-2023

Date of Acceptance: 26-02-2023

I. Introduction

In recent years, the detection of adrenal expansive lesions during CT examinations has become common, even in patients without endocrinological symptoms, because of the increasing number of investigations carried out for different clinical problems, with a prevalence varying from 0.35% to 9% in different series [1, 2].

After recognizing an expansive adrenal lesion, the differentiation between adenomas and nonadenomas becomes crucial for patient’s prognosis and for the choice of the therapeutic approach [3–6].

The role of CT for differential diagnosis has been studied in numerous investigations, and the accuracy of CT scans before and after injection of contrast material has been reported, even using dual energy CT scanners [7].

In case of unenhanced CT scans, intralesional density values of less than 10 HU indicate an adenoma with high accuracy. In contrast, intralesional density values greater than 10 HU are more common in nonadenomas, but they cannot exclude the possibility of adenomas with low-intra-cytoplasmic fat content [8–11].

CT scans after injection of contrast material mainly offer the evaluation of the peak density and intralesional washout for differential diagnosis between adenomas and nonadenomas. There is no unanimous agreement in the literature for the optimal scan delay to evaluate this parameter; according to some authors, the optimal delay is represented by 10 minutes after intravenous injection of contrast material, to others 15 minutes, and according to other experiences, earlier CT scans performed at 5 minutes can be used in this field [12–21].

The purpose of this study is to evaluate the accuracy of the wash-out in the differential diagnosis between adenomas and nonadenomas and to compare the results obtained in CT scans performed at 5, 10, and 15 minutes after intravenous injection of contrast material.

II. Result

In our study out of 25 patient majority of the patient were male (n=16)(67%),there are 8(33%) female patients.The most common age group in our study is 31-40 yrs (n =6 , 25 %).The most common lesion in our study was adrenal adenoma (n=8, 33%) followed by metastasis (n=4, 16.6%). Adrenal neoplasm of primary origin , Pheochromocytoma and adrenal calcification has least number of cases (n=1).There were 2 cases of chemically active lesion one of each from adrenal adenoma and pheochromocytoma.

Table 1: Age Distribution

AGE GROUP	NO. OF CASES	PERCENTAGE(%)
0-10	0	0
11-20	0	0
20-30	4	16.6
31-40	6	25
41-50	4	16.6
51-60	4	16.6
61-70	4	16.6
>70	3	12.5
Total	24	100

Table 2: Sex Distribution

MALE	16	67%
FEMALE	8	33%
TOTAL	24	100%

Table 3: Distribution of lesions

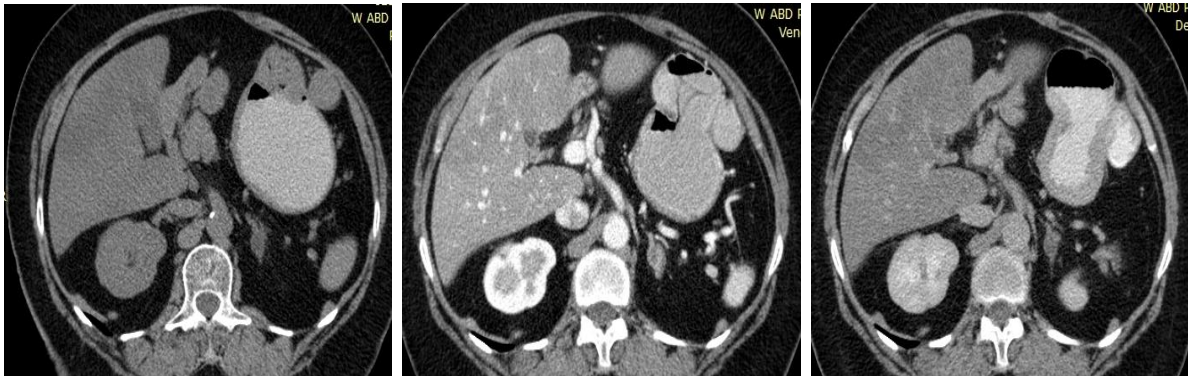Lesions	No.	Percentage
Adrenal adenoma	8	33.33
Adrenal cyst	2	8.33
Adrenal hypertrophy	2	8.33
Adrenal haemorrhage	3	12.5
Pheochromocytoma	1	4.1
Myelolipoma	2	8.33
Metastasis	4	16.6
Adrenal neoplasm of primary origin	1	4.4
Adrenal calcification	1	4.4
Total	24	100

Table 4: Distribution of chemically active lesions

Diagnosis	No. of cases
Adrenal adenoma	1
Pheochromocytoma	1
Total	2/24 (8%)

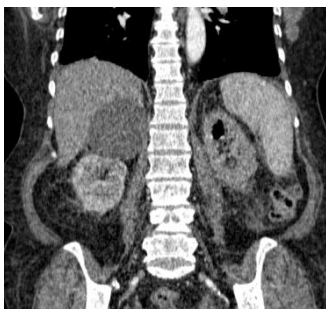III. Discussion

Adrenal Adenoma



Small sized well defined homogenous lesion involving medial limb of left adrenal gland. The lesion has HU of less than 10 (0 to -3) and shows more than 60 % absolute washout and 40 % relative washout on 15 minutes delayed scan highly suggestive of *Adrenal adenoma*.

ADRENAL CYST



A 46 years old diabetic female patient presented with abdominal pain. On CECT abdomen, both kidney shows changes of emphysematous pyelonephritis. Incidentally right adrenal cyst was noted.

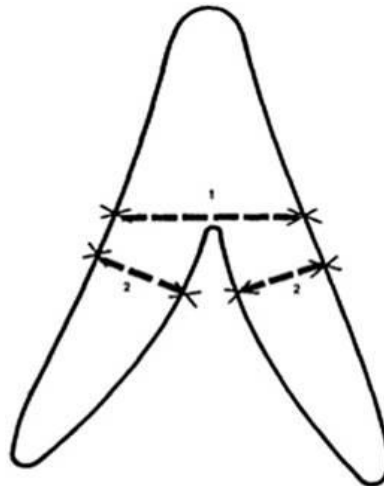
ADRENAL HYPERTROPHY

To quantify the degree of the adrenal enlargement, classified as mild, moderate, or severe.

Mild enlargement - limb measuring greater than 5 mm to 7.5 mm, or a body greater than 10 mm to 12.5 mm.

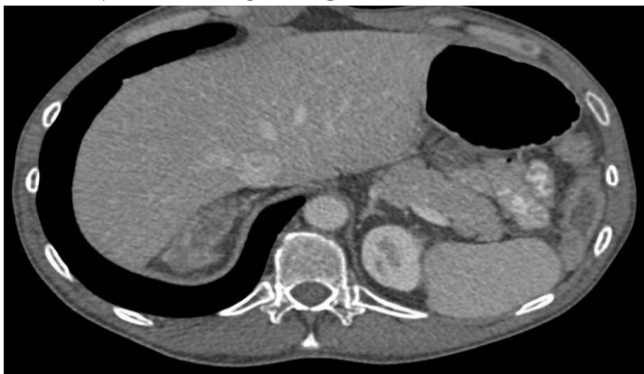
Moderate enlargement - limb measuring 7.5 mm to 10 mm, or a body measuring 12.5 mm to 15 mm.

Severe enlargement - the limb measures greater than 10 mm or the body was greater than or equal to 15 mm.



Schematic diagram of an adrenal gland demonstrating the measurement technique. No. 1 indicates the maximum width of the adrenal gland, and no. 2 indicates the maximum width of the limbs of the adrenal gland. The type of enlargement, based on subjective evaluation of the adrenal glands could be either smooth or nodular. Nodular enlargement was diagnosed if the adrenal gland had an irregular contour, contained nodules, and had normal adrenal tissue interspersed between the nodules. Smooth enlargement was defined as enlargement of the gland with a smooth contour and no measureable or diffuse nodules

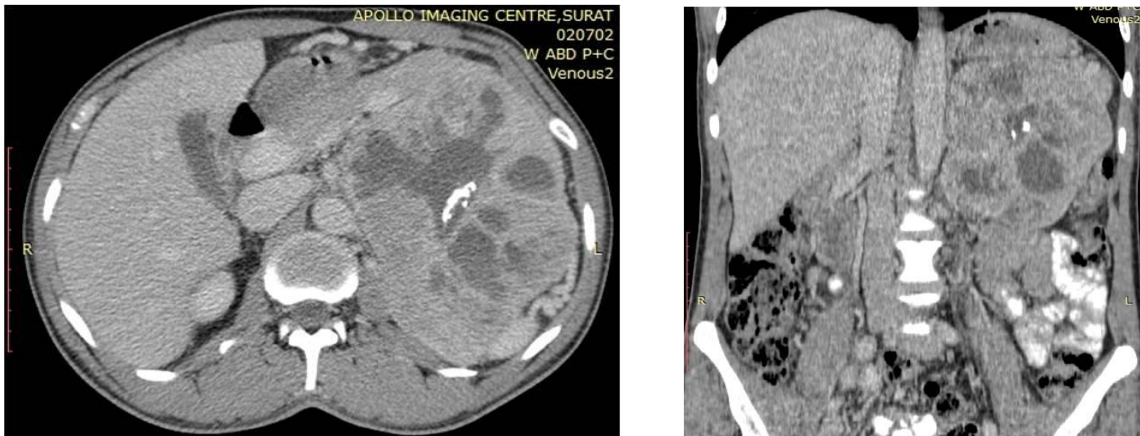
ADRENAL HEMMORHAGE



Case of 35 year old male patient with blunt abdominal trauma to the mesentery and minimal hemoperitoneum shows acute to subacute hematoma within the right adrenal with hyperdense area of high attenuation (55HU)

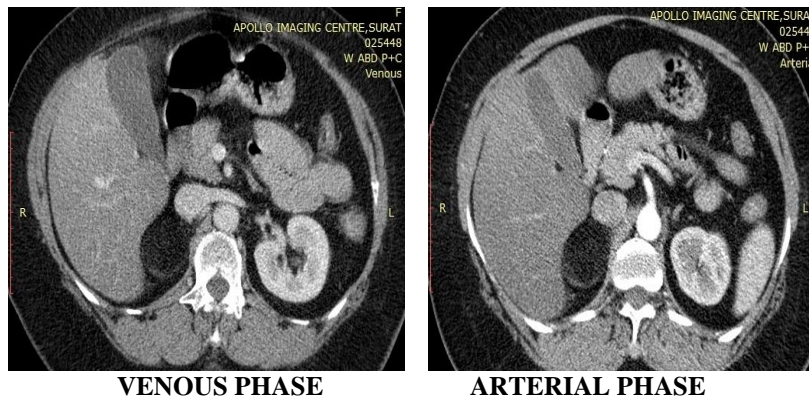
- **Adrenal hemorrhage** can result from a variety of traumatic and non-traumatic causes. When unilateral, it is often clinically silent. In contrast, bilateral adrenal hemorrhage can lead to adrenal insufficiency. Other non traumatic causes of adrenal hematoma includes-
- Sepsis, especially meningococcaemia (also known as Waterhouse-Friderichsen syndrome)
- Disseminated intravascular coagulation (DIC)
- Primary antiphospholipid syndrome
- Heparin-induced thrombocytopenia
- Steroid usage
- Anticoagulation
- Underlying adrenal tumor.

ADRENAL PHEOCHROMOCYTOMA



CECT of a 26 year old male patient presented with headache and palpitation shows a large well defined heterogeneously enhancing retroperitoneal lesion with multiple non – enhancing necrotic/ cystic areas noted involving left adrenal gland with Multiple calcific foci noted within central part of the lesion. The lesion shows intense enhancement on arterial phase (~ HU 120) and shows washout on venous phase (~ HU 70). Mass effect over adjacent vessels in form of compression and displacement and mass effect over adjacent viscera was also seen. The lesion turned out to be a pheochromocytoma from left adrenal gland.

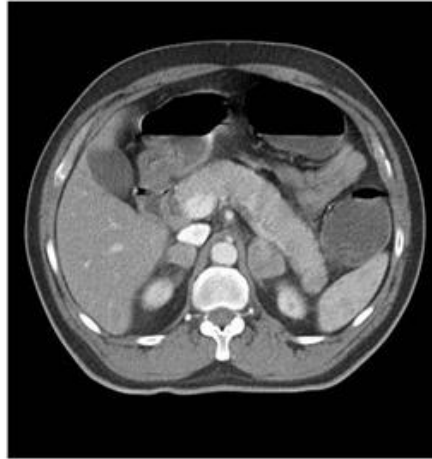ADRENAL MYELOLIPOMA



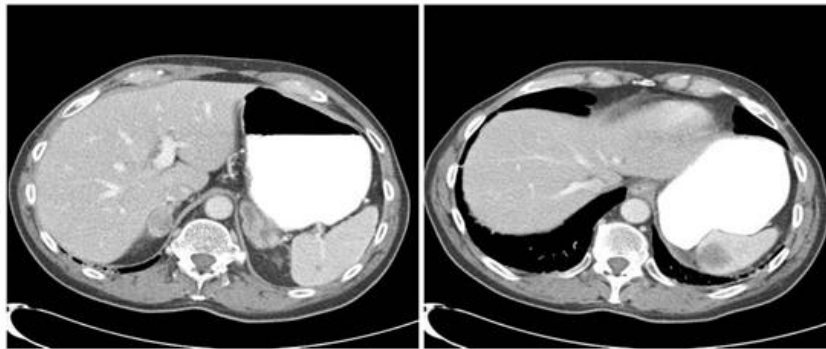
CECT of a 50y old female reveals a large well defined predominantly fat density lesion from right adrenal gland showing subtle contrast enhancement. Lesion was right adrenal myelolipoma.

ADRENAL METASTASIS

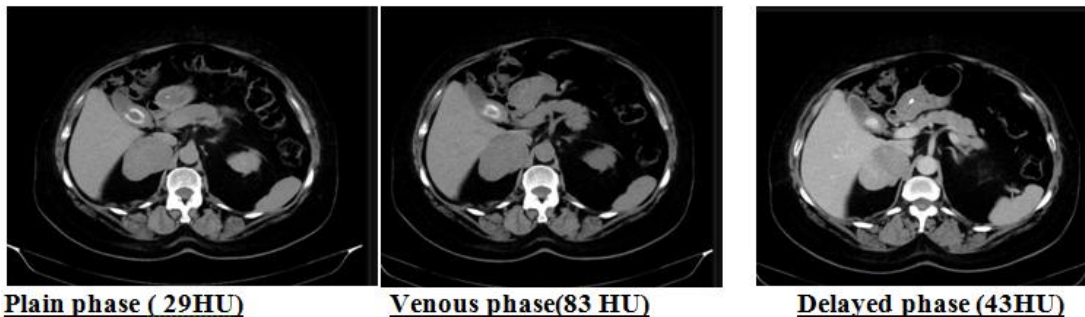
CECT reveals bilateral adrenal metastasis in a 55year old female patient with lung carcinoma that was extensively spread involving the mediastinum, ribs, sternum, vertebra and bilateral adrenal glands. No liver metastasis were seen.



A 75 y male patient with primary testicular malignancy showing bilateral adrenal and splenic metastasis.

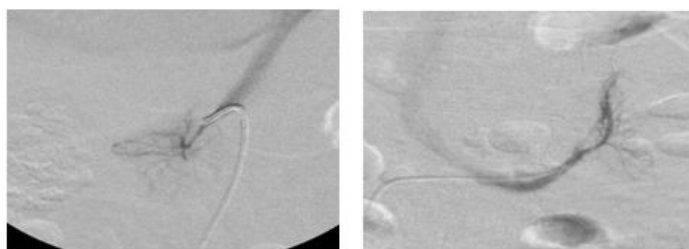


ADRENAL NEOPLASM



CECT in a 65 year old male patient shows a large right adrenal mass lesion which is relatively well demarcated abutting the posterior margin of the IVC with no evidence of local invasion. 74% absolute washout and 49% relative washout. Lesion turned out to be primary adrenocortical carcinoma.

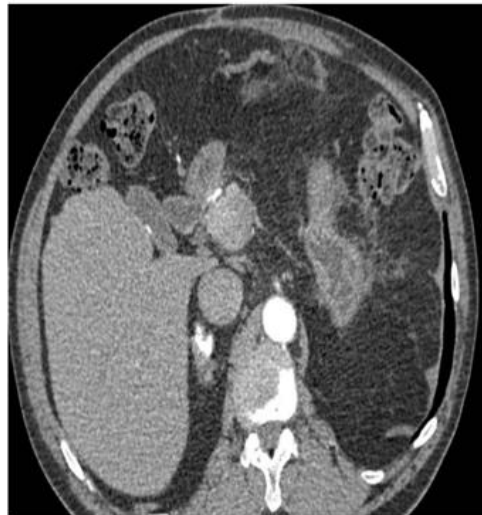ADRENAL ADENOMA AND ADRENAL VEIN SAMPLING UNDER DSA GUIDANCE



A 35 year old male patient with cect revealing right adrenal small adenoma. Patient referred to our institutes' department of interventional radiology for adrenal vein sampling. Right and left adrenal vein catheterized and sample taken from them respectively. Sample from IVC taken for comparison simultaneously.

ADRENAL CALCIFICATION

Incidental adrenal calcification seen after old case of blunt trauma to liver in a 30 year old male patient in the right adrenal gland. Here the calcification represents the old adrenal haemorrhage.



Other causes of adrenal calcification includes.

Infection: tuberculosis, histoplasmosis,hydatid disease

Adrenal tumours

Others: Addison disease, Wolman disease in yound children and infants and is often bilateral with organomegaly.

ADRENAL VENOUS SAMPLING (WITHOUT STIMULATION)

	Cortisol (ug/dl)	Aldostreron (ng/dl)	Cortiosl AV:P	A/C
RT ADRENAL VEIN	39.61	474.5	6.57	11.97
LT ADRENAL VEIN	63.44	145	10.53	2.2
IVC	6.02			

RESULT: Lateralised to right side

Result lateralizing the lesion to the right side.

The detection of adrenal expansive lesions during CT examination is frequent, with a prevalence varying between 0.35% and 9% in different series [1, 2]. In 50%–80% of cases, they are represented by adenomas, whereas nonadenomas are most often represented by metastases, adrenal carcinomas (<5%), pheochromocytomas (5%), myelolipomas (5%–10%), and cysts (1%–5%) [22–24]. The metastases originate more often from carcinomas of the lung, breast, kidney, thyroid, colon, and melanoma and represent 20%–50% of adrenal masses diagnosed in patients with known neoplastic disease [3, 22, 25]. The differential diagnosis between adenomas and nonadenomas with imaging techniques is of particular importance for an adequate prognostic and therapeutic approach, being able to avoid the use of invasive procedures such as biopsy or unnecessary prolonged followup

Many lesions could not be definitively characterized when found serendipitously at CT, because venous phase enhancement levels do not enable distinction. A specific diagnosis can be made if the examination includes unenhanced images that show attenuation less than 10 HU (adenoma) or the lesion contains macroscopic fat (myelolipoma).

In patients with clinical signs or symptoms of hormonal function, laboratory analysis is indicated, but this is not a reliable means of identifying all adenomas, because only 11% of adenomas are functional. Nearly all pheochromocytomas secrete metanephrines, except in patients with early preclinical disease [3, 6, 7].

In the differentiation between adenomas and nonadenomas, morphological, histological, and physiological criteria are usually used.

The morphological criteria considering the size and the homogeneous or inhomogeneous appearance of the lesion provide useful elements for differential diagnosis between adenomas and nonadenomas but need to be always combined with other parameters. In particular, adenomas are most often lesions with regular margins, small in size, with a mean value of less than 3 cm, and have a homogeneous density. In autopsy series, only 2% of adrenal adenomas had a diameter greater than 4 cm and 0.03% over 6 cm. Metastases, carcinomas, and pheochromocytomas, on the contrary, have more frequently a diameter larger than 4 cm, irregular contours, and an inhomogeneous appearance for the presence of areas of necrosis, hemorrhage, and intralesional cystic degeneration [21, 22,23, 24, 25,26].

The histological criteria are based on the evaluation of intracellular lipids within the adrenal lesion. About 70% of adrenal adenomas, in fact, are made up of cells containing intracytoplasmic lipid deposits, which represent the precursors of their secreted hormone and confer a low density to the mass in the unenhanced CT scans.

The morphological criteria represent, therefore, an important parameter of evaluation but have some limitations.

- i. They do not allow a diagnostic orientation in case of lipid-poor adenomas (approximately 30% of cases), which have a density greater than 10 HU.
- ii. Unenhanced CT scans are often not used in the followup of cancer, and therefore the histological criteria cannot be evaluated.
- iii. The possibility exists that an adrenal carcinoma contains foci of intracytoplasmic lipids [27], as well as exceptionally metastatic from clear cell renal carcinoma and hepatocellular carcinoma [21].

The physiological criteria are represented by the vascular enhancement and the washout of the lesion. Some authors have evaluated the contribution of the late scans performed at 15' after the injection of contrast material, reporting a sensitivity and specificity of 79%–89% and 92%–96% for APW values of more than 60% and a sensitivity and a specificity of 82%–83% and 92%–93% for RPW values of more than 40% [28-31].

IV. Conclusion

- ◆ The combination of a lower threshold value at unenhanced CT and a 15-30 minute delayed imaging may improve the sensitivity and specificity for diagnosing adrenal lesions in patients with or without history of malignant disease.
- ◆ We found that of the patients without any history of malignancy or any related clinical symptoms almost all patients had radiologically benign lesions.
- ◆ Of all the benign lesions we found that at detection of small percentage of our adrenal study patients had hypersecretory lesions
- ◆ Small fraction had incidentally detected malignant adrenal lesion. Metastatic lesions were detected in cases of primary malignancy from lung, prostate and testis.
- ◆ Radiological follow-up of adrenal lesions still has a place for indeterminate lesions

Financial support and sponsorship:Nil.

Conflicts of interest:There are no conflicts of interest.

References

- [1]. M. Korobkin, I. R. Francis, R. T. Kloos, and N. R. Dunnick, “The incidental adrenal mass,” *Radiologic Clinics of North America*, vol. 34, no. 5, pp. 1037–1054, 1996.
- [2]. J. H. Song, F. S. Chaudhry, and W. W. Mayo-Smith, “The incidental adrenal mass on CT: prevalence of adrenal disease in 1,049 consecutive adrenal masses in patients with no known malignancy,” *The American Journal of Roentgenology*, vol. 190, no. 5, pp. 1163–1168, 2008.
- [3]. M. Taffel, S. Haji-Momenian, P. Nikolaidis, and F. H. Miller, “Adrenal imaging: a comprehensive review,” *Radiologic Clinics of North America*, vol. 50, no. 2, pp. 219–243, 2012.
- [4]. J. H. Song and W. W. Mayo-Smith, “Incidentally discovered adrenal mass,” *Radiologic Clinics of North America*, vol. 49, no. 2, pp. 361–368, 2011.
- [5]. G. W. L. Boland, “Adrenal imaging: from addison to algorithms,” *Radiologic Clinics of North America*, vol. 49, no. 3, pp. 511–528, 2011.
- [6]. G. W. Boland, “Adrenal imaging,” *Abdominal Imaging*, vol. 36, no. 4, pp. 472–482, 2011. View
- [7]. Y. K. Kim, B. K. Park, C. K. Kim, and S. Y. Park, “Adenoma characterization: adrenal protocol with dual-energy CT,” *Radiology*, 2013.
- [8]. M. J. Lee, P. F. Hahn, N. Papanicolaou et al., “Benign and malignant adrenal masses: CT distinction with attenuation coefficients, size, and observer analysis,” *Radiology*, vol. 179, no. 2, pp. 415–418, 1991.
- [9]. M. Korobkin, F. J. Brodeur, G. G. Yutzy et al., “Differentiation of adrenal adenomas from nonadenomas using CT attenuation values,” *The American Journal of Roentgenology*, vol. 166, no. 3, pp. 531–536, 1996.
- [10]. G. W. L. Boland, M. J. Lee, G. S. Gazelle, E. F. Halpern, M. M. J. McNicholas, and P. R. Mueller, “Characterization of adrenal masses using unenhanced CT: an analysis of the CT literature,” *The American Journal of Roentgenology*, vol. 171, no. 1, pp. 201–204, 1998.
- [11]. P. L. Choyke, “ACR appropriateness criteria on incidentally discovered adrenal mass,” *Journal of the American College of Radiology*, vol. 3, no. 7, pp. 498–504, 2006.
- [12]. M. Korobkin, F. J. Brodeur, I. R. Francis, L. E. Quint, N. R. Dunnick, and F. Londy, “CT time-attenuation washout curves of adrenal adenomas and nonadenomas,” *The American Journal of Roentgenology*, vol. 170, no. 3, pp. 747–752, 1998.
- [13]. D. H. Szolar and F. H. Kammerhuber, “Adrenal adenomas and nonadenomas: assessment of washout at delayed contrast-enhanced CT,” *Radiology*, vol. 207, no. 2, pp. 369–375, 1998.
- [14]. E. M. Caoili, M. Korobkin, I. R. Francis, R. H. Cohan, and N. R. Dunnick, “Delayed enhanced CT of lipid-poor adrenal adenomas,” *The American Journal of Roentgenology*, vol. 175, no. 5, pp. 1411–1415, 2000.
- [15]. M. Korobkin, “CT characterization of adrenal masses: the time has come,” *Radiology*, vol. 217, no. 3, pp. 629–632, 2000.
- [16]. C. S. Pena, G. W. L. Boland, P. F. Hahn, M. J. Lee, and P. R. Mueller, “Characterization of indeterminate (lipid-poor) adrenal masses: use of washout characteristics at contrast-enhanced CT,” *Radiology*, vol. 217, no. 3, pp. 798–802, 2000.
- [17]. E. M. Caoili, M. Korobkin, I. R. Francis et al., “Adrenal masses: characterization with combined unenhanced delayed enhanced CT,” *Radiology*, vol. 222, no. 3, pp. 629–633, 2002.
- [18]. M. A. Blake, M. K. Kalra, A. T. Sweeney et al., “Distinguishing benign from malignant adrenal masses: multi-detector row CT protocol with 10-minute delay,” *Radiology*, vol. 238, no. 2, pp. 578–585, 2006.
- [19]. T. Kamiyama, Y. Fukukura, T. Yoneyama, K. Takumi, and M. Nakajo, “Combined use of diagnostic parameters of unenhanced and short 5-minute dynamic enhanced CT protocol,” *Radiology*, vol. 250, no. 2, pp. 474–481, 2009.
- [20]. M. J. Sangwaiya, G. W. L. Boland, C. G. Cronin, M. A. Blake, E. F. Halpern, and P. F. Hahn, “Incidental adrenal lesions: accuracy of characterization with contrast-enhanced washout multidetector CT—10-minute delayed imaging protocol revisited in a large patient cohort,” *Radiology*, vol. 256, no. 2, pp. 504–510, 2010.
- [21]. G. Foti, N. Faccioli, W. Mantovani, G. Malleo, R. Manfredi, and R. P. Mucelli, “Incidental adrenal lesions: accuracy of quadriphasic contrast enhanced computed tomography in distinguishing adenomas from nonadenomas,” *European Journal of Radiology*, vol. 81, no. 8, pp. 1742–1750, 2012.
- [22]. Taffel M, Haji-Momenian S, Nikolaidis P, Miller FH. Adrenal imaging: a comprehensive review. *Radiologic Clinics of North America*. 2012;50(2):219–243
- [23]. Boland GWL. Adrenal imaging: from addison to algorithms. *Radiologic Clinics of North America*. 2011;49(3):511–528.
- [24]. oung WF. The incidentally discovered adrenal mass. *The New England Journal of Medicine*. 2007;356(6):601–610
- [25]. Dalrymple NC, Leyerdecker JR, Oliphant M. Problem Solving in Abdominal Imaging. Elsevier Health Sciences Division; 2009
- [26]. .Krestin GP, Steinbrich W, Friedmann G. Adrenal masses: evaluation with fast gradient-echo MR imaging and Gd-DTPA-enhanced dynamic studies. *Radiology*. 1989;171(3):675–680.
- [27]. Mackay B, El-Naggar A, Ordonez NG. Ultrastructure of adrenal cortical carcinoma. *Ultrastructural Pathology*. 1994;18(1-2):181–190.
- [28]. Caoili EM, Korobkin M, Francis IR, Cohan RH, Dunnick NR. Delayed enhanced CT of lipid-poor adrenal adenomas. *The American Journal of Roentgenology*. 2000;175(5):1411–1415.
- [29]. Korobkin M. CT characterization of adrenal masses: the time has come. *Radiology*. 2000;217(3):629–632.
- [30]. Pena CS, Boland GWL, Hahn PF, Lee MJ, Mueller PR. Characterization of indeterminate (lipid-poor) adrenal masses: use of washout characteristics at contrast-enhanced CT. *Radiology*. 2000;217(3):798–802.
- [31]. Caoili EM, Korobkin M, Francis IR, et al. Adrenal masses: characterization with combined unenhanced delayed enhanced CT. *Radiology*. 2002;222(3):629–633.

Dr.Kishan Soni, et. al. “Role of Multidetector Ct in Diagnosis of Incidental Adrenal Lesions (Adrenal Incidentaloma).” *IOSR Journal of Dental and Medical Sciences (IOSR-JDMS)*, 22(2), 2023, pp. 50-58.