

## Supernumerary Teeth in Premolar Region – Report of Two Cases

Aiswareya G, Mohammad Tariq, Nabeela Ibrahim, Saherish Farhan

1. Aiswareya G, Junior Resident, Department of Orthodontics and Dentofacial orthopaedics, Dr.Z.A.Dental College, Aligarh Muslim University, Aligarh, India. E-mail address:
2. Mohammad Tariq, Professor, Department of Orthodontics and Dentofacial Orthopaedics, Dr.Z.A.Dental College, Aligarh Muslim University, Aligarh, India. E-mail address:
3. Nabeela Ibrahim, Junior Resident, Department of Orthodontics and Dentofacial orthopaedics, Dr.Z.A.Dental College, Aligarh Muslim University, Aligarh, India. E-mail address:
4. Saherish Farhan, Junior Resident, Department of Orthodontics and Dentofacial orthopaedics, Dr.Z.A.Dental College, Aligarh Muslim University, Aligarh, India. E-mail address:

---

### ABSTRACT

Supernumerary teeth are quite common in the premolar region. Most supernumerary teeth in the premolar region were believed to be of supplemental type. The supernumerary teeth are generally asymptomatic and are frequently detected during routine radiographic examination. However, these supernumerary teeth occasionally develop complications, including cystic degeneration and displacement of adjacent teeth. It is important to not ignore these asymptomatic additional teeth. Proper diagnosis and treatment planning is essential in the management of supernumerary teeth.

**KEY WORDS:** Supernumerary teeth, Premolar

---

Date of Submission: 13-02-2023

Date of Acceptance: 26-02-2023

---

### I. INTRODUCTION

Supernumerary tooth (ST) is defined as “any tooth or odontogenic structure that is formed from tooth germ in excess of usual number for any given region of the dental arch”.<sup>1</sup> 8–9% of all supernumerary teeth are localized in the premolar area, where they are quite prevalent.<sup>2,3,4</sup> The supernumerary teeth generally are classified based on their shape as conical, tuberculate, supplemental, and odontoma.<sup>5</sup> The majority of supernumerary teeth in the premolar region are supplementary type, i.e they resemble the normal premolars and are frequently located in the mandible.<sup>2,3,6</sup> The conical shape and smaller size of these supernumerary teeth set them apart from the normal premolars, allowing for easy identification.<sup>7,8,9</sup> The supernumerary premolars can be erupted or impacted and are usually asymptomatic.

The etiology in the development of supernumerary teeth involves both genetic and environmental factors. It has been suggested that these supernumerary teeth belong to a post-permanent series that develops from the extension of dental lamina. Therefore, these supplemental teeth are rudimentary with incomplete root formation.<sup>10</sup>

The onset of the development of supernumerary premolars is difficult to detect and still remains controversial. Ohler et al stated that the roots of the supernumerary premolars continue to grow till twenty-three years of age.<sup>11</sup> The supernumerary premolars are usually located lingual to the normal premolar and can be single or multiple. It is often difficult to establish whether these supernumerary teeth are part of the premolar normal series or arise from the dental lamina extensions of molars. It has been found that the majority of supernumerary teeth that were originally a part of the molar region can be found between the second and third molars (paramolars) or behind the third molars (fourth molars).<sup>10</sup>

The supernumerary teeth occasionally can develop various complications ranging from crowding to cyst formation.<sup>5</sup> Hence, proper diagnosis and treatment planning in the management of supernumerary teeth is necessary, particularly in individuals undergoing orthodontic treatment.

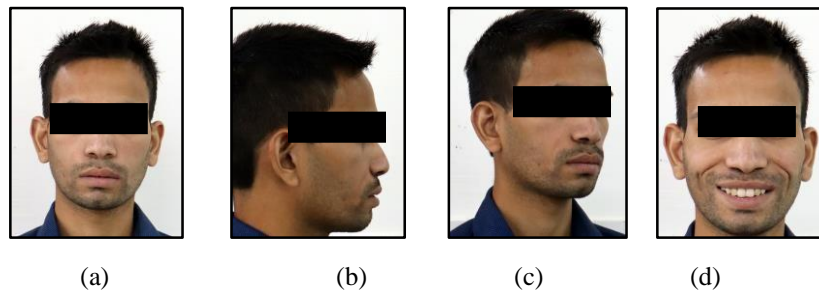
In the present paper, two case reports of supernumerary premolars are discussed.

### CASE REPORT-1

A 21-year-old male patient reported to the Department of Orthodontics and Dentofacial orthopedics with the chief complaint of irregularly placed teeth with the presence of additional teeth in both upper and lower dental arches. The patient was apparently healthy with no contributory medical or dental history.

**CLINICAL EXAMINATION**

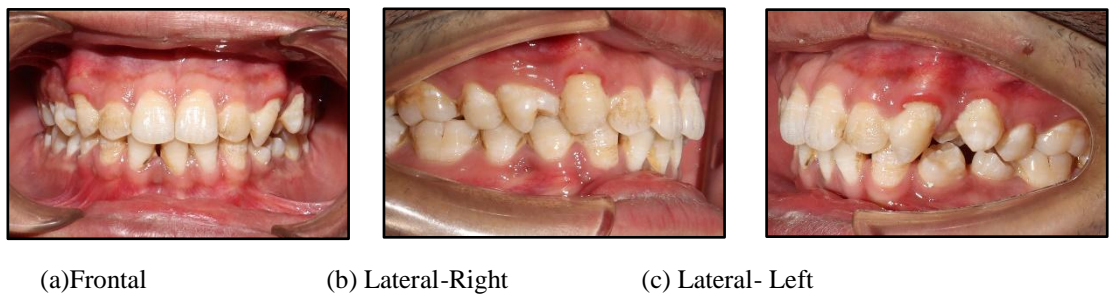
Extraoral features (Figure 1) revealed an apparently symmetrical, mesoprosopic face with competent lips and a straight profile. Smile analysis (Figure 1-d) shows Morley’s ratio of 95% with an average smile index and non-consonant smile arc.



**Figure 1- Extraoral photographs**

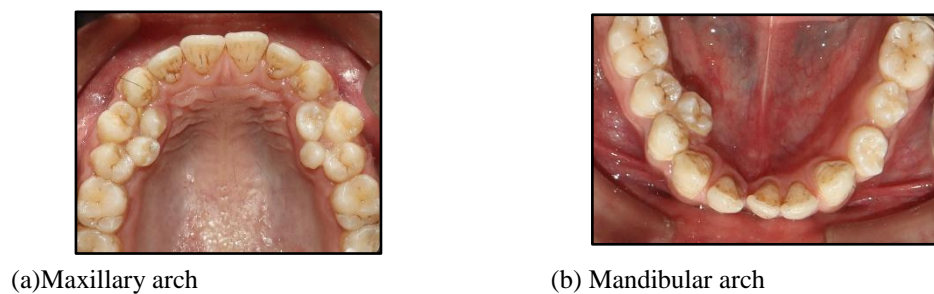
TMJ examination displayed no deviation or deflection on the inspection with normal mouth opening. No pain or tenderness on palpation of TMJ.

Intraoral examination showed Class I molar and canine relationship bilaterally with congenitally missing lower central incisor (Figure 2)



**Figure 2- Intraoral photographs**

In the maxillary arch, four supernumerary teeth were observed, two on each quadrant in relation to the palatal aspect of the right and left premolar region causing rotation of the adjacent permanent premolars. (Figure 3-a)



**Figure 3 – Occlusal photographs**

On the right side of the mandibular arch, a supernumerary tooth was located in relation to the lingual aspect of permanent premolars. On the left side, two supernumerary teeth were observed in the premolar region with unerupted 1<sup>st</sup> and 2<sup>nd</sup> premolars. (Figure 3-b)

**RADIOGRAPHIC EXAMINATION**

**CBCT FINDINGS - MAXILLA**

The panoramic and axial sections (Figure 4 & 5-a) of CBCT revealed the presence of four supernumerary teeth, two on each quadrant, palatal to 14 and 24,25

On the right side, two supernumerary teeth erupted mesio-palatal and distopalatal to the first premolar, at the occlusal level. The first premolar rotated along the long axis with a buccolingual surface lying mesiodistally. (Figure 6-a)

On the left side, the mesial supernumerary tooth noted erupted mesio-palatal to first premolar lying at the occlusal level between the first and second premolar. The root is curved slightly, with the root apex impinging the mesially dilacerated first premolar root, and the distal occlusal ridge impinging the mesial occlusal third of the first premolar crown. The cervical half of the root is apposed to the palatal cortex, with thinning and protuberance.

On the left side, the distal supernumerary tooth was noted to erupt distopalatal to the first premolar, lying at the occlusal level, with the cervical half of the root apposed to the palatal cortex, with thinning and protuberance.

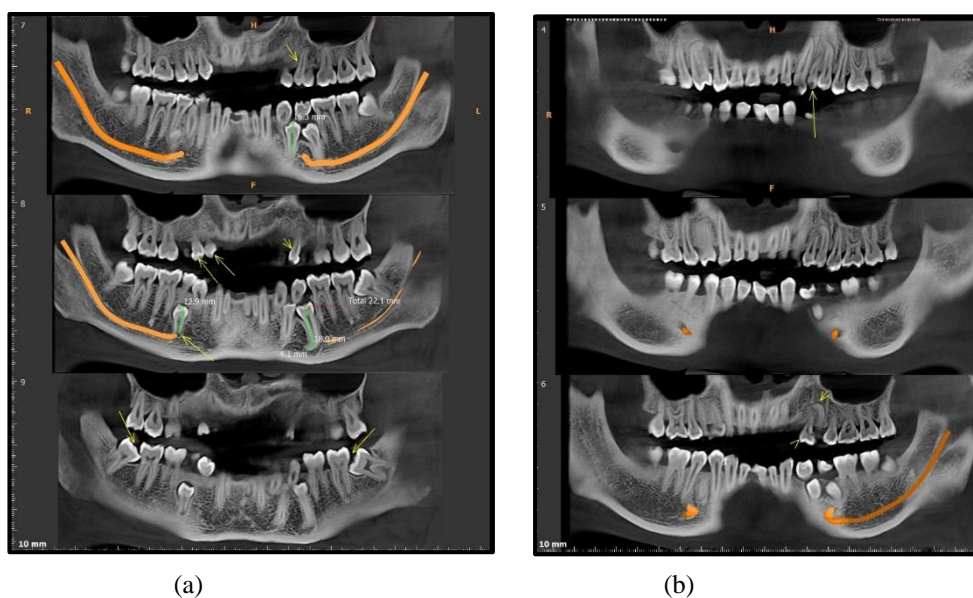
**CBCT FINDINGS - MANDIBLE**

Four supernumerary teeth were noted with respect to the mandible body region, 2 on each quadrant.

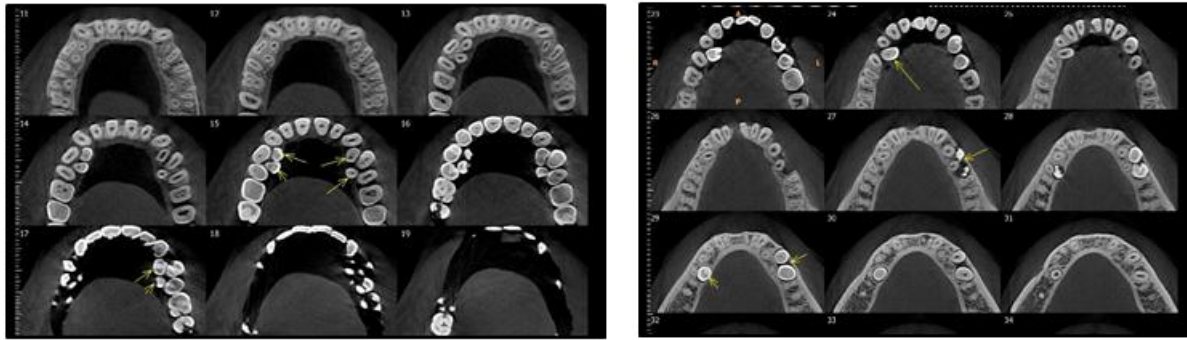
On the right side, mesial supernumerary tooth lies erupted, lingual to the interdental area between the first and second premolars, with roots of adjacent premolars splayed away. The tooth lies at the level of the lingual mid-occlusal aspect of premolars, interdently. The roots are inclined more buccally. (Figure 5-b & 6-b)

On the right side, the distal supernumerary tooth lies impacted vertically, at the level of lingual mid-apical of the second premolar root, apposed to the lingual cortex, with thinning and protuberance. Root resorption of the second premolar was noted. (Figure 5-b & 6-b)

On the left side, two supernumerary teeth erupted in the region of the first and second premolars with their roots resorbed by vertically impacted premolars. (Figure 6-c&d)

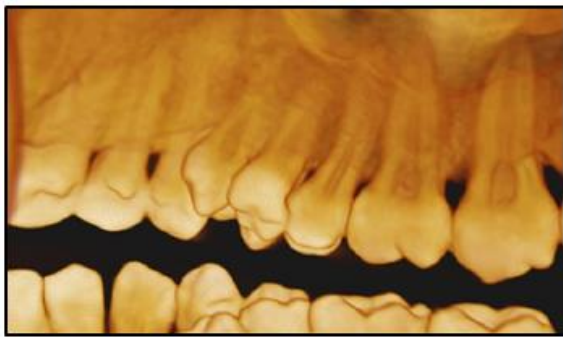


**FIGURE 4 - PANORAMIC SECTIONS**

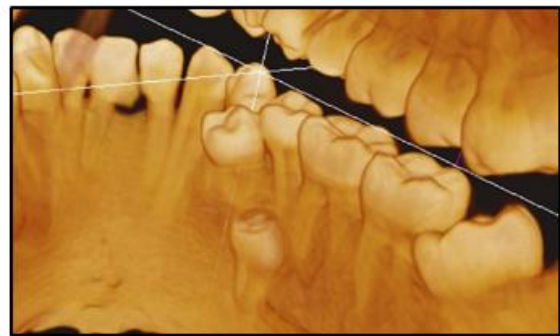

(a) Maxilla - Axial sections (b) Mandible- Axial sections

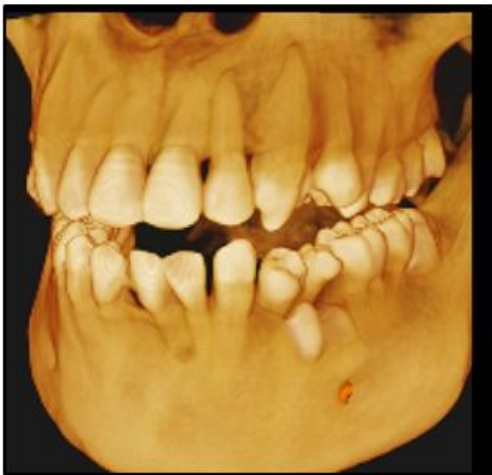**FIGURE 5- AXIAL SECTIONS**



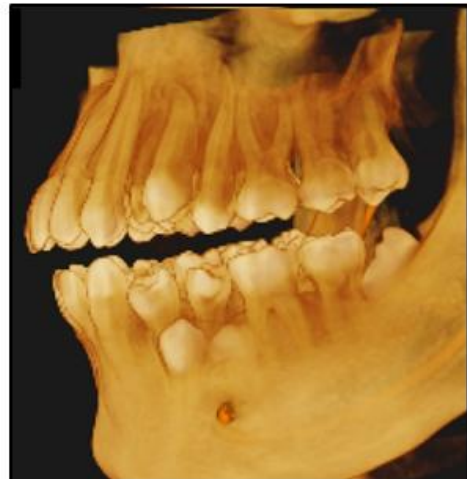(a)



(b)



(c)



(d)

**FIGURE 6 - 3D IMAGES**

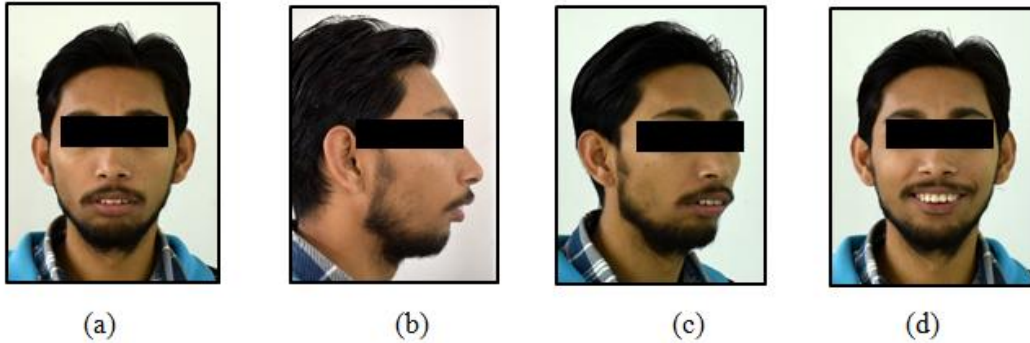


**CASE REPORT -2**

A 21 years old male patient reported to the Department of Orthodontics and Dentofacial orthopedics with the chief complaint of forwardly placed upper front teeth. The patient was apparently healthy with no contributory medical or dental history.

**CLINICAL EXAMINATION**

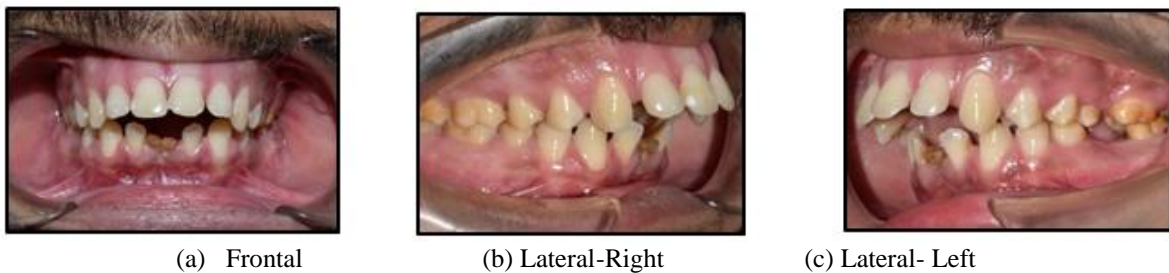Extraoral features (Figure 7) revealed an apparently symmetrical, mesoprosopic face with incompetent lips and a convex profile. Smile analysis (Figure 7-d) shows Morley’s ratio of 95% with an average smile index and non-consonant smile arc.



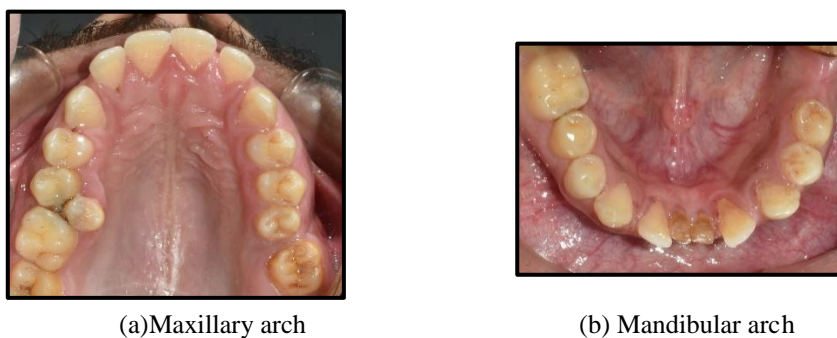
**FIGURE 7- EXTRAORAL PHOTOGRAPHS**

TMJ examination displayed no deviation or deflection on the inspection with normal mouth opening. No pain or tenderness on palpation of TMJ.

Intraoral examination revealed class II molar relation on right side and missing 26 and 36, class II canine relation bilaterally with increased overjet on a skeletal class II base.(Figure 8)



**FIGURE 8- INTRAORAL PHOTOGRAPHS**

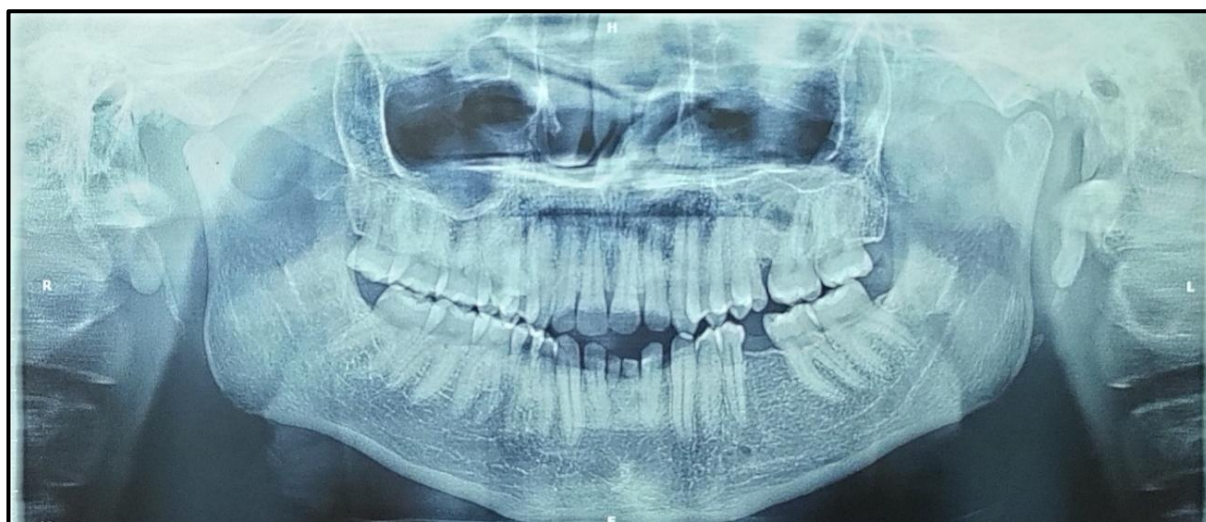

**FIGURE 9 – OCCLUSAL PHOTOGRAPHS**

In the occlusal photographs of the maxillary arch (Figure 9-a), two supernumerary teeth were observed, one on each quadrant. On the right side, the supernumerary tooth was present distopalatal to the second premolar. On the left side, the supernumerary tooth was present distal to the second premolar in the place of first molar.

In the mandibular arch (Figure 9-b), the two permanent central incisors and left mandibular first molar were missing with retained deciduous central incisors.

#### **RADIOGRAPHIC EXAMINATION**



**FIGURE 10 – OPG**

The OPG examination (Figure 10) revealed the presence of supernumerary teeth in relation to the premolar region on the right side and distal to the second premolar on the left side. The root length of the two supernumerary teeth was smaller than the roots of adjacent normal premolars. Congenitally missing lower permanent central incisors.

## **II. DISCUSSION**

The determination of the location of supernumerary teeth and their relation with the adjacent teeth is crucial in treatment planning. The supernumerary teeth can be impacted or erupted. The impacted supernumerary teeth were most frequently detected during routine radiographic examination, particularly during orthodontic treatment. The development of 3D imaging has made it easier to locate and relate supernumerary teeth, especially impacted ones, in recent times.

The supernumerary teeth can be differentiated from the normal dentition by their shape and size. The supernumerary teeth in the premolar region were believed to be of a supplemental type and occasionally conical or smaller than normal.<sup>10</sup> In case -1, the supernumerary teeth in the maxillary arch were similar to the normal premolar but were smaller in size (supplemental type) except for the distal supernumerary tooth on the left side, which was conical in shape. The small conical shaped supernumerary teeth have been found to be common in the upper premolar region.<sup>10</sup> In the mandibular arch, all the erupted supernumerary teeth were of supplemental type. Similarly, in case- 2, the two supernumerary teeth in the maxillary arch were supplemental type.

The supernumerary teeth are usually asymptomatic. However, various complications of these teeth must be considered during treatment planning. These teeth can cause crowding, which can affect gingival health due to increased plaque accumulation. The impacted supernumerary teeth can cause root resorption of adjacent teeth or can undergo cystic degeneration.<sup>5</sup> In case 1, the impacted supernumerary teeth on the mandibular right side displayed root resorption of these second premolar. Also, these supplemental teeth caused the rotation of adjacent normal premolars. It is important to observe that in both the patients discussed, the lower central incisors were congenitally missing.

During orthodontic treatment, the presence of supernumerary teeth can interfere with the orthodontic tooth movement. It is always advisable to extract these additional teeth during orthodontic treatment. However, in the case of multiple supernumerary teeth, patients often refuse to extract multiple teeth. Hence, in the case of multiple supernumerary teeth, the teeth that are present in the path of tooth movement can be extracted, and periodic evaluation of other supernumerary teeth can be advised. In case 1, extraction of all the erupted supernumerary teeth in the maxilla and lingually erupted teeth on the right side was planned. The patient refused to undergo surgical removal of impacted supernumerary teeth. Also, the patient was not willing for fixed orthodontic treatment. Hence, periodic evaluation of impacted supernumerary teeth was advised. In case 2, the

patient was willing to orthodontic treatment. Hence, the extraction of all supernumerary teeth followed by orthodontic treatment was advised.

### **III. Conclusion**

Supernumerary teeth are usually asymptomatic, particularly impacted teeth. They are found during routine radiographic examinations. It is important to not ignore these asymptomatic additional teeth. Proper diagnosis and treatment planning is essential for these supplemental teeth, because of their propensity to develop various complications.

### **References**

- [1]. R. S. Omer, R. P. Anthonappa, and N. M. King, "Determination of the optimum time for surgical removal of unerupted anterior supernumerary teeth," *Pediatric Dentistry*, vol. 32, no. 1, pp. 14–20, 2010.
- [2]. E. C. Stafne, "Supernumerary teeth," *Dental Cosmos*, vol. 74, pp. 653–659, 1932.
- [3]. M. M. Nazif, R. C. Ruffalo, and T. Zullo, "Impacted supernumerary teeth: a survey of 50 cases," *Journal of the American Dental Association*, vol. 106, no. 8, pp. 201–204, 1983.
- [4]. H. Grahnen and B. Lindahl, "Supernumerary teeth in the permanent dentition: a frequency study," *Odontologisk Revy*, vol. 12, pp. 290–294, 1961.
- [5]. Mallineni SK. Supernumerary Teeth: Review of the Literature with Recent Updates. Vol. 2014, Conference Papers in Science. 2014.
- [6]. W. H. R. Still, "A short study of supernumerary teeth in Southern Nigeria," *British Dental Journal*, vol. 79, pp. 215–217, 1945.
- [7]. E. K. Tratman, "Compound composite odontomes: a case of six supernumerary premolars," *British Dental Journal*, vol. 58, p. 239, 1940.
- [8]. C. Price and G. S. Hoggins, "A category of supernumerary premolar teeth," *British Dental Journal*, vol. 126, pp. 224–228, 1969.
- [9]. R. M. Shah and V. Pauls, "Supernumerary premolars: report of two cases," *Journal of the Canadian Dental Association*, vol. 44, pp. 114–115, 1978.
- [10]. Khalaf K, Al Shehadat S, Murray CA. A Review of Supernumerary Teeth in the Premolar Region. *Int J Dent*. 2018 Dec 3;2018.
- [11]. F. A. C. Oehlers, "Postpermanent premolars," *British Dental Journal*, vol. 93, pp. 157–158, 1952.

Aiswareya G, Mohammad Tariq, et. al. "Supernumerary Teeth in Premolar Region – Report of Two Cases." *IOSR Journal of Dental and Medical Sciences (IOSR-JDMS)*, 22(2), 2023, pp. 04-10.