

## Outcomes of Trochanteric Fractures Treated by Proximal Femoral Nail Anti-Rotation 2: An Interventional Study

Dr.Karimi Rama Naidu\*<sup>1</sup>, Dr.Kranthi Kiran Sanapala<sup>2</sup>, Dr Pasinibilli Satish Kumar<sup>3</sup>, Dr. Gundakaram Samhitha<sup>4</sup>

<sup>1</sup>(Postgraduate, Department of Orthopedics, Great Eastern Medical School & Hospital, Srikakulam, Dr YSR UHS, Andhra Pradesh, India)

<sup>2</sup>(Postgraduate, Department of Orthopedics, Great Eastern Medical School & Hospital, Srikakulam, Dr YSR UHS, Andhra Pradesh, India)

<sup>3</sup>(Postgraduate, Department of Orthopedics, Great Eastern Medical School & Hospital, Srikakulam, Dr YSR UHS, Andhra Pradesh, India)

<sup>4</sup>(Intern, Great Eastern Medical School & Hospital, Srikakulam, Dr YSR UHS, Andhra Pradesh, India)

### Abstract:

**Background:** Intertrochanteric hip fracture is a common major public health issue among elderly patients. Indians are at more risk of osteoporosis and hip fractures, as per Malhotra et al. The proximal femoral nail anti-rotation (PFNA) is a modification of proximal femoral nail (PFN), and it was introduced in 2003. PFNA was designed for proper femoral geometric proportions, but variations exist between Asian and Caucasian femoral geometry.

**Objective:** This study was done to know the clinical outcomes of treating unstable intertrochanteric fractures of femur fixed using PFNA2.

**Materials and Methods:** This study was done at tertiary care teaching hospital in the Department of Orthopaedics at Great Eastern Medical School, Srikakulam, Andhra Pradesh, India from March to August 2022. 100 patients were included as per the eligibility criteria. Age, gender, type of fracture, grade of osteoporosis, blood loss, weight bearing to tolerate mobilization and intraoperative reduction: good or acceptable were assessed.

**Results:** Most of the patients were aged 61 to 70 years. 67% of the patients were females. 62% of the patients had A2 type of fracture. Most of the patients had above 3 Singh's grade of osteoporosis. Blood loss was more than 100ml for most of the patients. Outcome of reduction was good for 37% of patients.

**Conclusion:** An intra-medullary device that needs a minimally invasive procedure is the implant of choice for managing unstable inter-trochanteric osteoporotic fractures. It allows a shorter duration of surgery with minimal blood loss, which is possible with PFNA 2.

**Key Words:** Implant, Osteoporosis, outcomes, proximal femoral nail anti-rotation 2, Trochanteric fractures

Date of Submission: 13-02-2023

Date of Acceptance: 26-02-2023

### I. Introduction

Intertrochanteric hip fracture is a common major public health issue among elderly patients. Indians are at more risk of osteoporosis and hip fractures, as per Malhotra et al.<sup>1</sup> One study showed that 50% women and 36% men aged above 50 years in India have low bone mass.<sup>2</sup> Around half of the hip fractures among elderly patients are intertrochanteric and most of them were of unstable type.<sup>3</sup> Hip fractures can increase the risk of bedsores, pneumonia, urinary tract infections, and thromboembolic complications. Management of these fractures effectively can cause early mobilization of the patient. Internal fixation is the method of choice for treating these fractures.<sup>4</sup> Internal fixation devices are of two types: Sliding compression hip screw like Dynamic Hip Screw (DHS) and intramedullary fixation devices. DHS is an ideal implant in managing stable intertrochanteric fractures<sup>5,6</sup> but in cases of unstable intertrochanteric fractures, it can cause cut-out failure, which ranges from 6% to 19%.<sup>7,8</sup> But an intramedullary device with shorter lever can enhance the biomechanics, giving more load sharing at the fracture site.<sup>9</sup> The proximal femoral nail anti-rotation (PFNA) is a modification of proximal femoral nail (PFN), and it was introduced in 2003. PFNA was designed for proper femoral geometric proportions, but variations exist between Asian and Caucasian femoral geometry.<sup>10</sup> But it leads to certain complications when used for Asians. New PFNA 2 is suitable for Asian femoral geometry.<sup>11</sup> Previously there were no Indian studies, which have established the role of factors that affect the outcome of these fractures fixed with PFNA2.

**Objective:** This study was done to know the clinical outcomes of treating unstable intertrochanteric fractures of femur fixed using PFNA2.

## **II. Materials And Methods**

This interventional study was carried out at a tertiary care centre in India from March 2022 to August 2022.

**Study Design:** Interventional study

The study is interventional, as fracture fixation was done, as a part of the study.

**Study Location:** This study was done at a tertiary care teaching hospital in the Department of Orthopaedics at Great Eastern Medical School and Hospital, Srikakulam, Andhra Pradesh, India.

**Study Duration:** March 2022 to August 2022

**Sample size:** 100 Patients

**Sampling procedure:** Simple random sampling

**Sample size calculation:** As per International osteoporosis foundation facts<sup>12</sup>, the prevalence of osteoporosis was 6.2% among men and 21.2% among women aged above 50 years. Clubbing these two, the prevalence was 13.7%.

At a confidence level of 85%, taking error as 5%, the minimum sample size obtained was 99. So, we included 100 patients.

**Subjects & selection method:** The study population was drawn from patients who were admitted in the department of orthopaedics with intertrochanteric osteoporotic fractures.

### **Inclusion criteria:**

1. Patients aged above 50 years with unilateral, unstable intertrochanteric fractures (A2 and A3 in AO classification)
2. Either sex
3. Patients who provided informed consent to participate in the study.

### **Exclusion criteria:**

1. Patients with fractures of subtrochanteric extension
2. Patients with inflammatory arthritis
3. Patients with fractures that are more than 2 weeks old
4. Patients with incomplete data
5. Patients with active infection

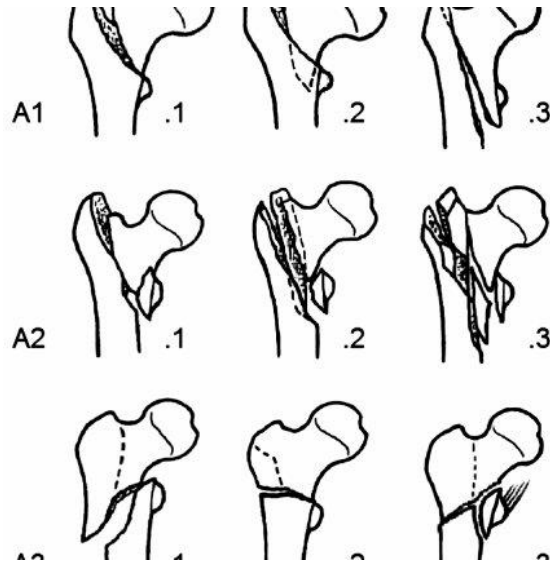
### **Methodology:**

After involving patients as per the inclusion and exclusion criteria, data collection was done. A detailed history was taken from each patient. Thorough physical examination, vital signs and systemic examination, local examination was done. The data was subjected to statistical analysis and then a conclusion was drawn.

### **Parameters assessed:**

- Age
- Gender
- AO classification of fractures
- Singh index of grading of osteoporosis- Singh Index (SI) is a simple, assessment tool for diagnosing osteoporosis using plain radiographs.<sup>13</sup> It is based on the trabecular pattern of the proximal femur that classifies osteoporosis into 6 grades.
- Blood loss
- Weight bearing to tolerate mobilization
- Intraoperative reduction: It was assessed using modified Harris hip score (MHHS).

Image 1 shows AO classification of intertrochanteric fractures<sup>14</sup>



**MHHS:**

A score of below 70 indicates poor result, 70–79 indicates fair results, a score of 80–89 indicates good result and >90 score indicates excellent result. This score is based on the patient’s pain, gait, functional activities, range of motion and deformity<sup>15</sup>

**Ethical considerations:**

Every patient was explained the whole process and advantages of the study. After he/she accepts, an informed consent form is given in the local language or the patient’s understandable language and the person was asked to sign it or put a thumb impression.

**Statistical analysis**

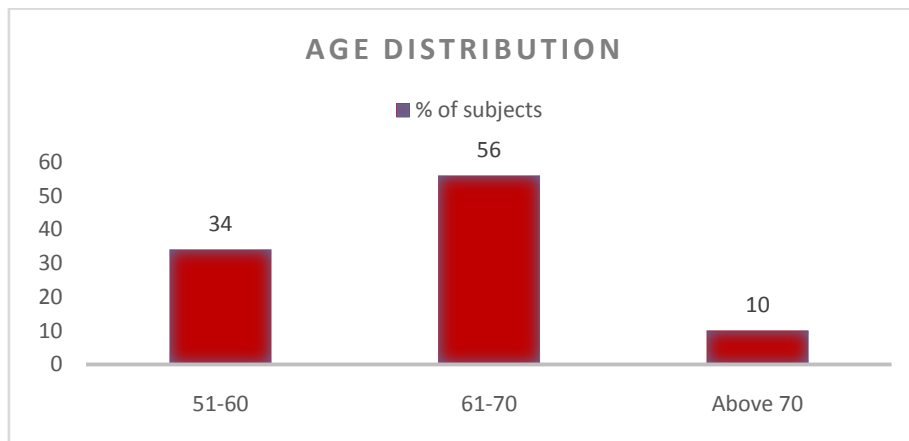
Data was analyzed using SPSS software version 26.0. Results were expressed as percentages and mean with standard deviation. Numerical parameters were compared using students t test. Results were presented in tabular forms and graphs in pie and bar diagrams. P value below 0.05 is considered significant.

**III. Results**

The current study included 100 patients with unstable intertrochanteric fractures.

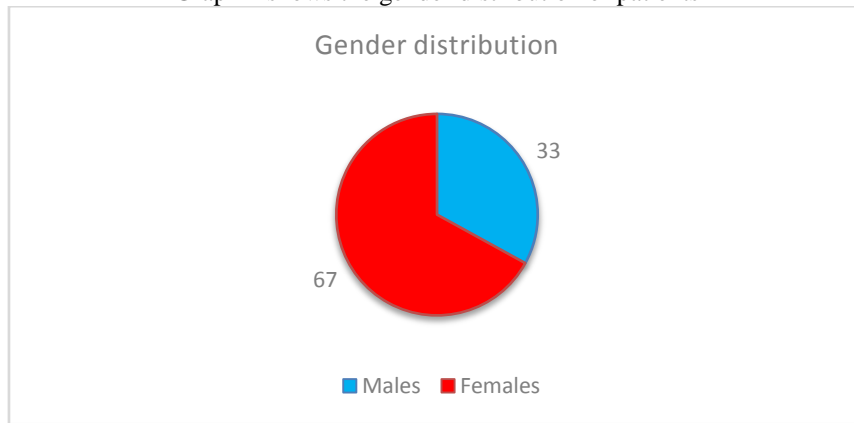
**Age:** Most of the patients belonged to the age group 61 to 70 years, followed by 51 to 60 years.

**Graph 1:** Shows the age distribution of patients



**Gender:** Most of the patients were females. 67% were females and 33% were males.

Graph 2 shows the gender distribution of patients



**Type of fractures:**

A2 fractures were seen in 62% of patients.

A3 were seen in 38% of patients.

A2 fractures show several intermediate fragments that extend more than 1 cm distal to the lesser trochanter. A3 - have a fracture line through lateral femoral wall.

Table 1 shows type of fractures among study patients

Type of fracture	No of patients	% of patients
A2	62	62%
A3	38	38%

**Singh index of osteoporosis:**

Most of the patients had an osteoporosis grade  $\geq 3$

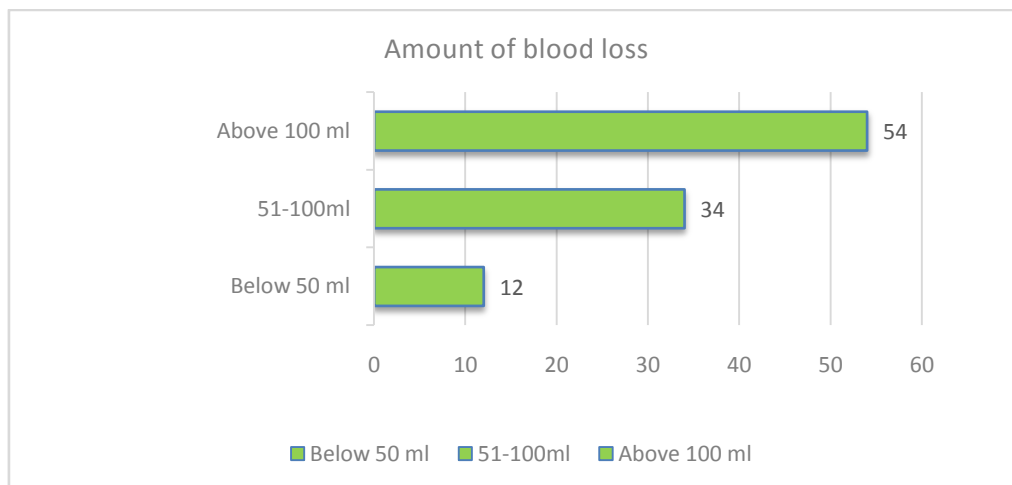
Table 2: Singh grade of osteoporosis

Singh grade	No of patients	% of patients
$\geq 3$	66	66%
$< 3$	34	34%

**Blood loss:**

54% of the patients had above 100ml of blood loss.

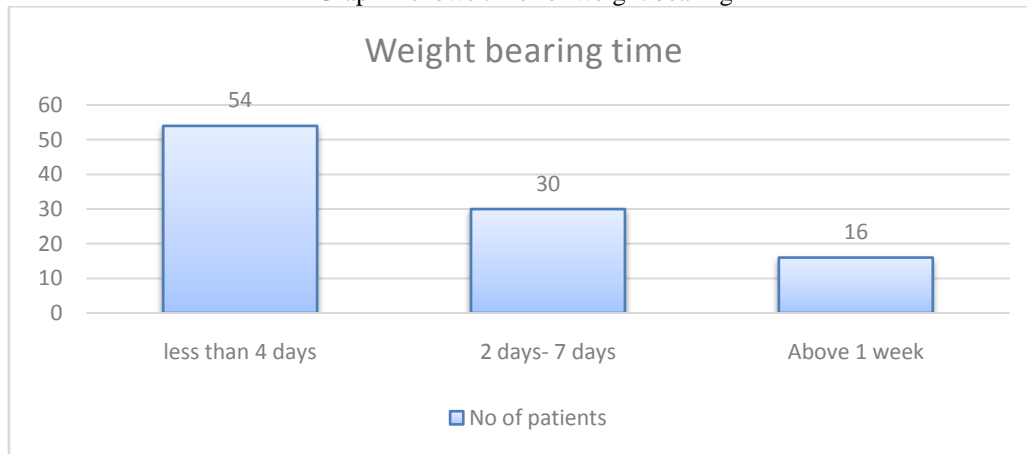
Graph 3 shows amount of blood loss among study patients



**Time for weight bearing to tolerate mobilization:**

Most of the patients were able to move within 4 days.

Graph 4 shows time for weight bearing



**Outcome of intraoperative reduction:**

Patients were followed up till 20 weeks after surgery. Outcome was assessed using modified harris hip score. Outcome was excellent in 19% of patients.

Table 3 shows outcome of intraoperative reduction at 20 weeks

Intraoperative reduction	No of patients	% of patients
Poor	12	12%
Good	37	37%
Fair	32	32%
Excellent	19	19%

**Non-union and infection:** No patient had non-union or developed infection, died or had anterior thigh pain in our study.

**IV. Discussion**

The current study included 100 patients with unstable intertrochanteric fractures.

Most of the patients were aged 61 to 70 years. 67% of the patients were females. Most common fracture is A2 in AO classification. Most of the patients were able to move within 4 days. Most of the patients had an osteoporosis grade  $\geq 3$ . Patients were followed up till 20 weeks after surgery. 54% of the patients had above 100ml of blood loss in our study. As per few studies, patients for whom PFNA 2 was used, had significantly less blood loss compared to PFNA and DHS.<sup>16</sup>

As per the study of **Swaroop et al.**<sup>17</sup> 82.1% of patients who underwent PFNA2 fixation had good MHH score at the end of 1 year. In our study also, the outcome was assessed using modified Harris hip score. Outcome was excellent in 19% of patients, good in 37% of patients and fair in 32% of patients at the end of 20 weeks after surgery.

**Lv Chiaoling et. al.**<sup>18</sup> reported good to excellent results among 78.2% of their study patients.

**Li Ming et. al.**<sup>19</sup> also found good to excellent outcome in 81.9% of patients.

**Wei et. al.**<sup>20</sup> did a retrospective review on 204 patients and reported good outcomes associated with good reduction. He also suggested that osteoporosis severity did not affect the outcome in intertrochanteric fractures, which were fixed with PFNA2.

No patient had non-union or developed infection in our study. However, migration of helical blade was reported by **Simmermacher et. al., PU JSet. al.**<sup>21-22</sup>

Implant breakage was not seen, which could be due to improved design of the distal end of the PFNA 2 with a flexible tip.<sup>23</sup>

Limitations:

1. Small sample size
2. Duration of surgery was not assessed.
3. Patients were not followed up for long duration.

## V. Conclusion

An intra-medullary device that needs a minimally invasive procedure is the implant of choice for managing unstable inter-trochanteric osteoporotic fractures. It allows a shorter duration of surgery with minimal blood loss, which is possible with PFNA. We recommend appropriate fracture reduction to achieve union and prevent cut-out.

The study is self-sponsored.

There were no conflicts of interest.

## References

- [1]. Malhotra N, Mithal A. Osteoporosis in Indians. *Indian J Med Res.* 2008 Mar;127(3):263-8. PMID: 18497441.
- [2]. Pande KC. Prevalence of low bone mass in healthy Indian population. *J Indian Med Assoc.* 2002 Oct;100(10):598-600, 602. PMID: 12452513.
- [3]. Koval KJ, Aharonoff GB, Rokito AS, Lyon T, Zuckerman JD. Patients with femoral neck and intertrochanteric fractures. Are they the same? *Clin Orthop Relat Res.* 1996 Sep;(330):166-72. doi: 10.1097/00003086-199609000-00020. PMID: 8804287.
- [4]. Koval KJ, Zuckerman JD. *Subtrochanteric Fractures.* In: Hip Fractures. New York, NY: Springer New York; 2000. p. 191–252.
- [5]. Calvert PT. The Gamma nail--a significant advance or a passing fashion? *J Bone Joint Surg Br.* 1992 May;74(3):329-31. doi: 10.1302/0301-620X.74B3.1587869. PMID: 1587869.
- [6]. Jensen JS, Sonne-Holm S, Tøndevold E. Unstable trochanteric fractures. A comparative analysis of four methods of internal fixation. *Acta Orthop Scand.* 1980 Dec;51(6):949-62. doi: 10.3109/17453678008990900. PMID: 7211302.
- [7]. Jensen JS, Sonne-Holm S, Tøndevold E. Unstable trochanteric fractures. A comparative analysis of four methods of internal fixation. *Acta Orthop Scand.* 1980 Dec;51(6):949-62. doi: 10.3109/17453678008990900. PMID: 7211302.
- [8]. Domingo LJ, Cecilia D, Herrera A, Resines C. Trochanteric fractures treated with a proximal femoral nail. *Int Orthop.* 2001;25(5):298-301. doi: 10.1007/s002640100275. PMID: 11794263; PMCID: PMC3620810.
- [9]. Harrington P, Nihal A, Singhanian AK, Howell FR. Intramedullary hip screw versus sliding hip screw for unstable intertrochanteric femoral fractures in the elderly. *Injury.* 2002 Jan;33(1):23-8. doi: 10.1016/s0020-1383(01)00106-1. PMID: 11879828.
- [10]. Adams CI, Robinson CM, Court-Brown CM, McQueen MM. Prospective randomized controlled trial of an intramedullary nail versus dynamic screw and plate for intertrochanteric fractures of the femur. *J Orthop Trauma.* 2001 Aug;15(6):394-400. doi: 10.1097/00005131-200108000-00003. PMID: 11514765.
- [11]. Siddiqi N, Valdevit A, Chao EYS. Differences in femoral morphology among the Orientals and Caucasians: a comparative study using plain radiographs. *Anat Sci Int.* 2019 Jan;94(1):58-66. doi: 10.1007/s12565-018-0450-1. Epub 2018 Jun 27. PMID: 29951777.
- [12]. Epidemiology of osteoporosis and fragility fractures [Internet]. Osteoporosis.foundation. International Osteoporosis Foundation; 2019 [cited 2023 Feb 20]. Available from: <https://www.osteoporosis.foundation/facts-statistics/epidemiology-of-osteoporosis-and-fragility-fractures>
- [13]. Singh M, Nagrath AR, Maini PS. Changes in trabecular pattern of the upper end of the femur as an index of osteoporosis. *J Bone Joint Surg Am.* 1970;52(3):457-67. doi: 10.2106/00004623-197052030-00005. [PubMed] [CrossRef] [Google Scholar]
- [14]. Palm H, Lysén C, Krashennnikoff M, Holck K, Jacobsen S, Gebuhr P. Intramedullary nailing appears to be superior in pertrochanteric hip fractures with a detached greater trochanter: 311 consecutive patients followed for 1 year. *Acta Orthop.* 2011 Apr;82(2):166-70. doi: 10.3109/17453674.2011.566143. Epub 2011 Mar 24. PMID: 21434790; PMCID: PMC3235286.
- [15]. Vishwanathan K, Akbari K, Patel AJ. Is the modified Harris hip score valid and responsive instrument for outcome assessment in the Indian population with pertrochanteric fractures? *J Orthop.* 2018 Jan 3;15(1):40-46. doi: 10.1016/j.jor.2017.12.001. PMID: 29326497; PMCID: PMC5760250.
- [16]. Singh NK, Sharma V, Trikha V, Gamanagatti S, Roy A, Balawat AS, Aravindh P, Diwakar AR. Is PFNA-II a better implant for stable intertrochanteric fractures in elderly population? A prospective randomized study. *J Clin Orthop Trauma.* 2019 Oct;10(Suppl 1):S71-S76. doi: 10.1016/j.jcot.2019.02.004. Epub 2019 Feb 7. Erratum in: *J Clin Orthop Trauma.* 2020 Nov-Dec;11(6):1169-1171. Erratum in: *J Clin Orthop Trauma.* 2021 Aug 05;21:101557. PMID: 31700206; PMCID: PMC6823828.
- [17]. ISwaroop S, Gupta P, Bawari R, Marya SK, Patnaik S. Factors Affecting the Outcome of Unstable Intertrochanteric Fractures Managed With Proximal Femoral Nail Anti-Rotation 2: A Prospective Outcome Study in Elderly Indian Population. *Cureus.* 2020 Dec 8;12(12):e11973. doi: 10.7759/cureus.11973. PMID: 33425545; PMCID: PMC7790322.
- [18]. Lv C, Fang Y, Liu L, Wang G, Yang T, Zhang H, Song Y. The new proximal femoral nail antirotation-Asia: early results. *Orthopedics.* 2011 May 18;34(5):351. doi: 10.3928/01477447-20110317-26. PMID: 21598887.
- [19]. Li M, Wu L, Liu Y, Wang C. Clinical evaluation of the Asian proximal femur intramedullary nail antirotation system (PFNA-II) for treatment of intertrochanteric fractures. *J Orthop Surg Res.* 2014 Nov 13;9:112. doi: 10.1186/s13018-014-0112-5. PMID: 25391985; PMCID: PMC4233078.
- [20]. Zhang W, Antony Xavier RP, Decruz J, Chen YD, Park DH. Risk factors for mechanical failure of intertrochanteric fractures after fixation with proximal femoral nail antirotation (PFNA II): a study in a Southeast Asian population. *Arch Orthop Trauma Surg.* 2021 Apr;141(4):569-575. doi: 10.1007/s00402-020-03399-2. Epub 2020 Apr 15. PMID: 32296964.
- [21]. Simmermacher RK, Ljungqvist J, Bail H, Hockertz T, Vochteloo AJ, Ochs U, Werken Cv; AO - PFNA studygroup. The new proximal femoral nail antirotation (PFNA) in daily practice: results of a multicentre clinical study. *Injury.* 2008 Aug;39(8):932-9. doi: 10.1016/j.injury.2008.02.005. Epub 2008 Jun 25. PMID: 18582887.
- [22]. Pu JS, Liu L, Wang GL, Fang Y, Yang TF. Results of the proximal femoral nail anti-rotation (PFNA) in elderly Chinese patients. *Int Orthop.* 2009 Oct;33(5):1441-4. doi: 10.1007/s00264-009-0776-3. Epub 2009 Apr 15. PMID: 19367404; PMCID: PMC2899136.
- [23]. Mereddy P, Kamath S, Ramakrishnan M, Malik H, Donnachie N. The AO/ASIF proximal femoral nail antirotation (PFNA): a new design for the treatment of unstable proximal femoral fractures. *Injury.* 2009 Apr;40(4):428-32. doi: 10.1016/j.injury.2008.10.014. Epub 2009 Feb 20. PMID: 19230885.