

Nmda Antibody Encephalitis Associated With Ovarian Teratoma, Intracranial Cryptococcal Infection And Neurosarcoidosis Possible: A Quadruple Peril!

Siham Bahbouh ¹⁻², Rafida Braham Chaouche ², Yasmine Hamouda ²,
Lina Manel Hamedi ².

Faculty Of Medicine Of Algiers, University Of Algiers 1.

Department Of Neurology Ali Ait Idir Specialized Hospital –Algiers-Algeria.

Abstract

Anti-NMDA receptor encephalitis is an immune-mediated paraneoplastic encephalitis. It mainly affects young women, with a high frequency of ovarian teratoma, indicating the underlying paraneoplastic pathogenesis. The clinical presentation is protean and evolves in several stages. We report here a 31-year-old immunocompetent patient with a history of toxemia of pregnancy, hospitalized for memory disorders evolving for 4 months. The neuropsychological evaluation showed a massive deficit of retrograde and anterograde memory, a severe alteration of episodic memory, false recognitions, a discrete dysexecutive syndrome, a lack of access to lexicons, with the preservation of instrumental functions. Brain magnetic resonance imaging had objectified a right temporal and a bilateral thalamic signal anomaly of non-specific nature associated with a right lenticular sequela deficiency. Blood count, blood ionogram, liver and kidney functions, anti-nuclear antibodies, anti-phospholipids and thiamine dosages were without abnormalities. Serologies of human immunodeficiency virus, hepatitis B and C, syphilis, cytomegalovirus and herpes simplex virus were also negative. Cerebrospinal fluid (CSF) was citrin, with hyperproteinorachia (1.43 g/l), hypoglycorachia (0.17 g/l) and 140 lymphocyte elements. Direct examination and culture of CSF revealed the presence of cryptococcal yeasts (*Cryptococcus neoformans*). The angiotensin conversion enzyme assay in CSF was increased to 5 times higher than normal and the anti-NMDA antibody assay was positive. The course was fatal despite treatment with immunoglobulins and fluconazole. The coexistence of anti-NMDA receptor encephalitis, teratoma, intracranial cryptococcal infection and possible neurosarcoidosis is rare. The underlying pathogenic roles remain to be identified.

Keywords: encephalitis, anti-NMDA receptor antibody, teratoma, cryptococcal meningitis, dysautonomia

Date of Submission: 21-10-2023

Date of Acceptance: 31-10-2023

I. Introduction

Anti-NMDA receptor encephalitis is an immune-mediated paraneoplastic encephalitis. It mainly affects young women, with a high frequency of ovarian teratoma, indicating the underlying paraneoplastic pathogenesis. The clinical presentation is protean and evolves in several stages. The symptoms include a very characteristic set of neurological, but also psychiatric manifestations that can be in the foreground. However, the triggering of the immune response to NMDA receptors is precipitated by the presence of concomitant factors of infectious nature whose mechanism remains undetermined [1]. The case of cryptococcal meningoencephalitis caused by *Cryptococcus neoformans* infection which is a serious infection of the central nervous system in immunocompromised patients [2] but which can also occur rarely in immunocompetent subjects. We report here a 31-year-old immunocompetent patient with anti-NMDA receptor encephalitis with ovarian teratoma, a concomitant intracranial cryptococcal infection, associated with possible neurosarcoidosis during the same period of hospitalization.

II. Case Report

A 31-year-old married woman, mother of 2 children and with a history of toxemia of pregnancy, was admitted to our service for memory disorders evolving for 4 months. She claimed to be single without children and frequently presented an omission of doing things, tidying up, and events. During the discussions, she lost track of ideas and no longer remembered the subject. She also had a lack of words, sometimes using blend words and paraphrases. The entourage also reported confabulations. The patient was afebrile and the neurological examination was without abnormalities. Neuropsychological evaluation showed an amnesic syndrome (marked by a massive deficit of retrograde and anterograde memory, severe alteration of episodic memory, false

recognition, spontaneous and induced confabulations), a discrete dysexecutive syndrome, a lack of access to lexicons, with the preservation of instrumental functions. Behaviorally, the patient reported her disorder, but underestimated the symptoms. Magnetic resonance imaging (MRI) of the brain revealed a right temporal and a bilateral thalamic signal anomaly of non-specific nature associated with a right lenticular sequelae deficiency (Figure 1).

Before the clinical picture, the results of the neuropsychological evaluation and brain MRI, the diagnoses evoked were a herpetic viral origin, a deficiency (vitamin B1) or a probably emboligenic vascular origin. In this sense, the blood count, blood ionogram, hepatic and renal functions, anti-nuclear antibodies, anti-phospholipids and thiamine dosage were without abnormalities. HIV, hepatitis B and C, syphilis, a cytomegalovirus and herpes simplex viruses serologies were also negative. Subsequently the lumbar puncture showed a citrin cerebrospinal fluid (CSF), with hyperproteinorachia (1.43 g/ l), hypoglycorachia (0.17 g/ l) and 140 lymphocyte elements, a meningitic type profile with the presence of oligoclonal bands. Electroencephalogram (EEG) showed nonspecific slow waves. In this context of a hyperprotenorachic and hypoglycorachic meningitis, the infectious origin was the most probable (tuberculosis, cryptococcosis) or inflammatory (neurosarcoidosis). Cultures of BK, *Cryptococcus neoformans* were initiated, as well as the assay of the angiotensin conversion enzyme in CSF. The search for anti-NMDA antibodies has also been initiated with the aim of a broad sweep. The patient was given intravenous corticosteroid boluses at a dose of 1 g of solumedrol for 5 days. In the meantime, the anti-NMDA antibody test was positive. In this context, anti-NMDA receptor encephalitis was confirmed, underlying neoplasia was urgently sought by thoraco-abdomino-pelvic scanner. It was found the presence of a heterogeneous left latero-uterine formation of 63 mm x 44 mm with a fatty component developed on the left ovary, evoking a teratoma a priori (Figure 2)..

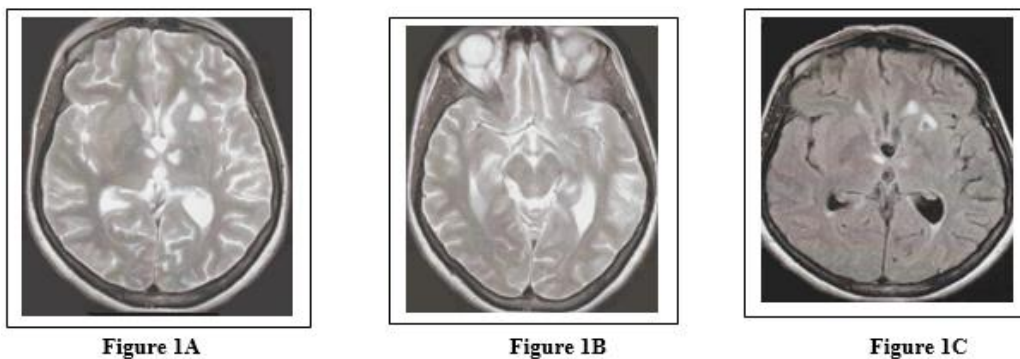


Figure 1 (A, B, C): Brain MRI showed bilateral thalamic and right temporal nodular signal abnormalities presenting as T2 hypersignal without diffusion restriction or no enhancement after contrast injection (Fig A and B). It is associated with a left lenticular signal anomaly surrounded by a border of gliosis in T2 FLAIR hypersignal with a sequelae appearance (Fig C).

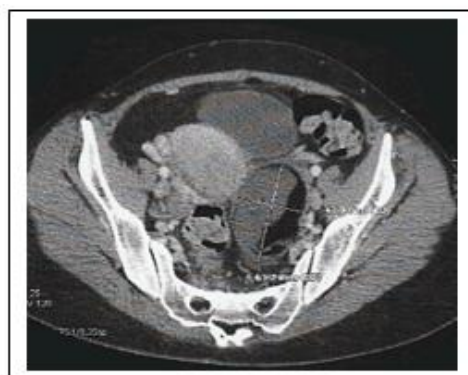

Figure 2: left latero uterine mass

III. Treatment

Intravenous immunoglobulin treatment was initiated with a total dose of 110 mg in 5 days, but this did not allow clinical improvement, it was observed on the 4th day of treatment, the appearance of persistent frontal headaches accompanied by vomiting and dysautonomy marked by fluctuations in blood pressure, and heart rate requiring standard treatments. Clinical examination showed stiffness of the neck, right hemiparesis with a normal

fundus and a temperature of 36.7. A cerebral MRI was performed urgently, and showed a dilation of the ventricular system predominant on the lateral ventricles, with persistence of bilateral lesions of the thalamo-sub-thalamic and lower lenticular central gray nuclei and on vascular sequences an irregular appearance of the M1 segments of the middle cerebral arteries and the A1 segment of the left anterior cerebral artery and a slender appearance of the distal divisional branches. In addition, CSF direct examination and culture showed cryptococcal yeasts (*Cryptococcus neoformans*) and the angiotensin conversion enzyme (ACE) in CSF was increased to 5 times higher than normal (11 U/L; normal value < 2). As a result, our patient presented with an anti-NMDA receptor encephalitis associated with teratoma, intracranial cryptococcal infection and also stigmata of possible neurosarcoidosis. Emergency treatment was initiated with fluconazole 1200 mg per day divided into 3 times, associated with subtractive lumbar punctures that showed high CSF opening pressures at 55 cmH₂O and 35 cmH₂O requiring the placement of a lumbar drain. Two days later, the symptomatology changed rapidly with a fluctuation of disorders of consciousness (10/15 Glasgow score), followed by severe bradycardia and cardiac arrest requiring external cardiac massage, intubation, ventilation and transfer to intensive care. The patient had recovered, the heart rate became sinus with 98% oxygen saturation. Unfortunately the next day, she presented with left hemiparesis, intermittent episodes of sinus tachycardia, hypertension, and tachypnea. During one episode, the heart rate was 123 to 182 beats per minute with blood pressure figures of 180 to 210/90 to 110 mmHg and a respiratory rate of 20 to 25 cycles per minute. Each episode lasted between 30 and 120 minutes and was repeated 3 times a day, taking the patient away.

IV. Discussion

Anti-NMDA receptor encephalitis in adults is an acute form of encephalitis and its association with ovarian teratomas is well documented in the literature [3, 4]. The diagnosis of anti-NMDAR encephalitis was retained on the following diagnostic criteria: rapid onset (less than 3 months) of a cognitive disorder, altered consciousness, autonomous dysfunction, CSF with pleocytosis and oligoclonal bands, positive anti-NMDA antibody test and presence of ovarian teratoma [5]. In our patient, we know little about the duration between contact with *Cryptococcus neoformans*, the occurrence of clinical symptoms, the duration between the initial onset of symptoms and consultation with the doctor. The same is true for the mechanism of concomitant occurrence of cryptococcal meningitis and anti-NMDA receptor encephalitis which remains unknown. Recall that the antibody of the NMDA receptor was present in the initial CSF which also contained cryptococcal yeasts. Our patient had first presented with cognitive symptoms and then other neurological manifestations settled including essentially a dysfunction of the autonomic nervous system (ANS). Neurovegetative instability with hypoventilation can be seen in about 70% of cases of anti-NMDA receptor encephalitis [6]. It can occur at different stages of the disease, and is manifested by a sudden deregulation of the sympathetic system associated with tachy-bradycardia, hypertension or low blood pressure, thermal deregulation, and also hypersalivation [7], [8].

All this can affect the prognosis and lead to death, via central hypoventilation, which requires management in intensive care [9], [10]. Hence the recommendations for first-line and emergency treatment of anti-NMDAR encephalitis in adult patients include intravenous methylprednisolone, immunoglobulins or plasma exchanges, and the removal of the teratome when it is present. Although potentially treatable, anti-NMDA receptor encephalitis can cause death in the absence of an appropriate treatment [11]. In our case, despite immunotherapy, symptoms of autonomic nervous system dysfunction appeared, they were immediately severe. And to complicate matters, the concomitant discovery of cryptococcal meningitis, which is the most common fungal infection of the central nervous system and most patients with it are immunocompromised. However, our patient was immunocompetent and had no precipitating factors, namely immunosuppressive treatments, autoimmune diseases, hematological disorders [12] and no contact with pigeons. According to a Chinese study, patients with no identified underlying conditions accounted for about 30% of non-infected HIV patients with cryptococcal infection [13]. In the brain, *Cryptococcus neoformans* can cause a localized infection, namely cerebral cryptococcomas, dilation of Virchow-Robin spaces and/or obstructive hydrocephalus [14]. The disturbances of consciousness in our patient would be the consequence of intracranial hypertension linked to a poor resorption of the CSF whose viscosity was increased, in connection with a high concentration of cryptococcal yeasts causing in some cases a fulminant rise in intracranial pressure [15]. Moreover, cryptococcal meningitis alone is associated with significant morbidity and mortality, hence the benefit of an early treatment. The reference treatment that improves the prognosis of neuromeningeal cryptococcosis includes dual therapy associating amphotericin B and flucytosine for 2 weeks with a fluconazole relay for at least 8 weeks [16]. However, given the unavailability of amphotericin B, fluconazole was administered as monotherapy in the patient. Unexpectedly, MRI angiography showed irregular aspects of the left middle and anterior cerebral arteries and a slender aspect of the distal divisional branches. It is well established that *Cryptococcus neoformans* tends to spread via the hematogenous route to the brain inducing meningitis and when it reaches the perivascular space of the perforating arteries, it spreads to the deeper parts of the brain, resulting in small lacunar-type cerebral infarctions mainly in the basal ganglia in 4 to 32% of CM patients on MRI [17,18]. The mechanisms involved in cryptococcal cerebral vasculopathy can be

direct, linked to the pathogen or indirect in relation to immunological or inflammatory reactions induced by the pathogen, or thrombotic mediated by platelet activation [19]. Moreover, the significant increase of the conversion enzyme in the CSF further complicates the diagnosis and therapeutic management. Indeed the differentiation between cryptococcal meningitis and neurosarcoidosis is difficult, because they both manifest a common symptomatology namely chronic meningitis, and can be complicated by hydrocephalus [20]. Abnormalities in CSF are similar, with mild pleocytosis, hyperproteinorachia and hypoglycorrachia [21]. However, vascular neurological damage is rare in neurosarcoidosis. They are of ischemic origin, more rarely hemorrhagic and most often reach the arteries of medium caliber by various mechanisms: granulomatous angiopathy, secondary vasculitis or fibrinoid necrosis of the vascular wall [22], [23]. In addition, in our patient, clinical elements frequently found in neurosarcoidosis are missing, such as cranial nerve damage particularly that of nerves VII, uni or bilaterally, or nerves V, VIII and II, and also radiological elements on brain MRI such as hyperintensities of the white matter of evocative topography such as the involvement of optic nerves, floor of V4, brain stem, cerebellar peduncles, hypothalamic-pituitary axis, and there is often a typically micronodular leptomeningeal enhancement after gadolinium injection. Thoraco-abdominopelvic CT scan showed no hilar and/or mediastinal adenopathies. Biologically, the elevation of ACE in CSF is possible but inconclusive compared to other inflammatory diseases. Its interest in the diagnosis of neurosarcoidosis is not contributory or even controversial and is therefore not part of the diagnostic criteria [20]. Nevertheless our patient presented a clinical picture with cognitive disorders associated with headaches with abnormal CSF (proteinorrachia, cellularity, oligoclonal bands) and an hydrocephalus on MRI that may suggest neurosarcoidosis without histological evidence according to the diagnostic classification of Zajicek et al [24]. However, regarding the temporal evolution of possible neurosarcoidosis and also cryptococcal meningitis and anti-NMDA receptor encephalitis, we cannot conclude anything on this. Our patient reportedly developed cryptococcus neoformans meningitis as the first clinical manifestation of a latent possible sarcoidosis, even though she was apparently immunocompetent and not on treatment with corticosteroids or other immunosuppressive drugs. This clinical condition was reported in the literature or in 18% of cases, cryptococcal meningitis was the initial presentation of sarcoidosis [21]. As for the mechanism by which cryptococcal meningitis and NMDA anti-receptor encephalitis occurred simultaneously, it would probably be autoimmune given that anti-NMDAR encephalitis is caused by an autoimmune reaction, mainly against the NR1 subunit of the NMDAR. It would be of double origin in our patient: paraneoplastic because of its association with the teratoma of the ovary, and post-infectious in connection with cryptococcal meningitis which can trigger an auto-immune deregulation targeting post synaptic NMDA receptors and potentially other brain autoimmunities, involving mechanisms of mimicry or a rupture of immunological tolerance to NMDAR expressed by neurons damaged by an inflammatory process [25].

V. Conclusion

The coexistence of anti-NMDAR encephalitis with ovarian teratoma, cryptococcal meningitis and neurosarcoidosis is rare, and raises the issue of their optimal treatment. Therefore, future studies are needed to identify the underlying pathogenic processes.

Conflicts of Interest:

The authors do not declare any conflicts of interest

References

- [1]. Venkatesan A, Benavides DR. Autoimmune Encephalitis And Its Relation To Infection. *Curr Neurol Neurosci Rep.* 2015 Mar; 15(3):3. Doi: 10.1007/S11910-015-0529-1. PMID: 25637289
- [2]. Bicanic T, Harrison TS. Cryptococcal Meningitis. *Br Med Bull.* 2005 Apr 18; 72:99-118. Doi: 10.1093/Bmb/Ldh043. PMID: 15838017
- [3]. Titulaer MJ, McCracken L, I Gabilondo, Armangué T, C Glaser, Iizuka T, Et Al. Treatment And Prognostic Factors For Long-Term Outcome In Patients With Anti-NMDA Receptor Encephalitis: An Observational Cohort Study. *Lancet Neurol.* 2013 Feb;12(2):157-65. Doi: 10.1016/S1474-4422(12)70310-1. PMID: 23290630
- [4]. Viacoz A, Desestret V, Ducray F, Picard G, Cavillon G, Rogemond V, Et Al. Clinical Specificities Of Adult Male Patients With NMDA Receptor Antibodies Encephalitis. *Neurology.* 2014 Feb 18; 82(7):556-63. Doi: 10.1212/WNL.000000000000126. PMID: 24443452.
- [5]. Graus F, Titulaer MJ, Balu R, Benseler S, Bien CG, Cellucci T, Et Al. A Clinical Approach To Diagnosis Of Autoimmune Encephalitis. *Lancet Neurol.* 2016 Apr; 15(4):391-404. Doi: 10.1016/S1474-4422(15)00401-9. PMID: 26906964
- [6]. Liu CY, Zhu J, Zheng XY, Ma C, Wang X. Anti-N-Methyl-D-Aspartate Receptor Encephalitis: A Severe, Potentially Reversible Autoimmune Encephalitis. *Mediators Inflamm.* 2017; 2017:6361479. Doi: 10.1155/2017/6361479. PMID: 28698711
- [7]. Gastaldi M, Nosadini M, Spatola M, Sartori S, Franciotta D. N-Methyl-D-Aspartate Receptor Encephalitis: Laboratory Diagnostics And Comparative Clinical Features In Adults And Children. *Expert Rev Mol Diagn.* 2018 Feb; 18(2):181-193. Doi: 10.1080/14737159.2018.1431124. PMID: 29376438