

Challenges During Resection Of Head And Neck Carcinoma- How To Tackle The Limitations Of Flaps In Such Cases

Dr suman Babu¹, DrGautam prakash², Dr Nikhil Prasad³

1 senior resident department of plastic surgery institute of medical sciences, bhuvanarasi.

2 assistant professor department plastic surgery institute of medical sciences, bhuvanarasi

3 senior resident department of plastic surgery institute of medical sciences, bhuvanarasi

Abstract

In patients with extensive head and neck carcinoma invading the orbit, the role of orbital exenteration is still widely debated. The aim of treatment is complete surgical resection with negative oncologic margins. However, this is seldom possible in patients of advanced malignancy, especially in recurrent lesions.

However, with improved microsurgical techniques, free flaps can be utilised to cover unsightly scars and extensive defects.

Here we present a unique case of extensive maxillary carcinoma eroding the orbit, and our surgical management with a rectus femoris flap and rotational forehead free flap

Additionally, a brief literature review is also presented to address the various challenges faced by plastic and reconstructive surgeons in such cases, and various methods to overcome it.

Keywords-*microvascular, free flaps, advanced head and neck cancer, orbital exenteration*

Date of Submission: 17-10-2023

Date of Acceptance: 27-10-2023

I. INTRODUCTION

25–40% of oral carcinomas are diagnosed in the oral cavity [1, 2], and due of their distinctive histologic structure (rich lymphatic network and extensively muscularized structure), they exhibit significantly more aggressive behaviour. Thus, compared to other oral cavity cancers, OTSCC is more often associated with metastases to draining lymph glands [4]. Chronic exposure to the oral mucosa to cigarettes, alcohol, and betel nuts has been identified as the main risk factor for OTSCC. Leukoplakia and tongue submucous fibrosis are the two most prevalent premalignant lesions, and submucous fibrosis has typically been attributed to a practise of chewing betel nut [5, 6].

3 to 5% of head and neck malignant neoplasms and 0.2 to 0.8% of all tumours are sinonasaltumours. 1 Various histological kinds exist, and each has a unique clinical behaviour. Squamous cell cancer (SCC), intestinal-type sinonasal adenocarcinoma, sinonasal tract adenoid cystic carcinoma (StACC), sinonasal undifferentiated carcinoma (SNUC), and neuroendocrine carcinoma (NEC) are the primary tumours that are most frequently diagnosed. In advanced disease, orbital involvement is typical. The case for orbital exenteration is still widely debated. The aim of treatment is complete surgical resection with negative oncologic margins. Regarding orbital compromise, three things need to be taken into account: (1) organ preservation, (2) tumour removal, and (3) functional condition

With the advancement of microsurgical reconstructive techniques over the past 30 years, a number of free flaps have been documented for extensive defects.

The radial forearm flap leaves an unsightly scar and compromises a significant artery at the donor site, though. The anterolateral thigh (ALT) flap has gained popularity during the past ten years. (7) With its lengthy pedicle and potential for flap thinning, the ALT flap can provide a significant amount of soft tissue, and surgery is typically performed by two teams with little to no donor site morbidity [8, 9]. The anteromedial thigh (AMT) perforator flap, on the other hand, is usually thin, pliable, and nearly hairless, making it particularly suitable to repair defects of the head and neck.

However, there are some rare circumstances where neither of the above can be utilized for oral carcinoma due to lack of perforators. Hence, we present an interesting scenario where rectus femoris was harvested to fill the defect and a rotational forehead flap was subsequently employed to complete the reconstruction.

II. CASE REPORT

This is a 62-year-old that presented with a ulcer on the left side of the inner aspect of the oral cavity, with an extension to the overlying skin (fig 1). Patient gives history of smoking and tobacco chewing since 40 years, with no history of associated co-morbidities. He was diagnosed with a 2 X 3 cm malignant ulcer in the left maxillary sinus region involving the left orbit, with collapse of the nasal bridge, for which he underwent wide local excision, enucleation of the left eyeball and radiotherapy 4 years back. Patient defaulted treatment and was lost to follow up for that duration.

On examination, patient had stable haemodynamics with associated pallor. Oral cavity examination revealed trismus grade III, diffuse oral submucous fibrosis with a 10 x 6 cm ulcer over the left maxillary region with erosion of the posterior aspect of the orbit. The ulcer had everted edges, blood tinged discharge, indurated edge and adherent to the body and ramus of the mandible.

Patient was evaluated for surgery, and hence underwent Computed tomography of the head and neck region, with a evaluation of the thorax and abdomen region to rule out metastases. CT scan revealed a heterogeneously enhancing mucosal lesion in the left maxillary sinus extruding into the left orbital ridge and zygomatic arch(fig 2). There was also evidence of enlarged level II, III and V lymph nodes bilaterally, largest measuring 2.3 x 1.2 cm with central necrosis. A working diagnosis of recurrence was made, and the histopathology confirmed the pathology of squamous cell carcinoma, poorly differentiated.

After thorough work-up, and once metastases was ruled out, patient was planned for wide local excision, hemimandibulectomy with reconstruction using the anterolateral thigh flap. Following the wide local excision, when we attempted to dissect the anterolateral lateral thigh flap, we observed that there was a paucity of perforators in this region.

Hence, the plan to harvest the anteromedial thigh flap was made. This too, lacked the essential perforators required for good flap transfer and uptake. After careful deliberation, it was decided to harvest and rotate the forehead to cover the defect, while the cavity was filled with the rectus femoris muscle(fig 3)with anastomosis to facial artery vessels.(fig 4).

The immediate post operative period was uneventful. Patient made a full recovery, and received adjuvant chemoradiotherapy. Patient is now on regular follow-up(fig 5), and there is no clinical or radiological evidence of recurrence.

III. DISCUSSION

The thigh makes a great donor site since it has a lot of skin that may be used, a lateral circumflex femoral artery system that is expendable, and low donorsite morbidity. The ALT flap is most frequently utilised to restore soft-tissue abnormalities. Variable vascular pedicle and perforator anatomy, however, define it. When the ALT flap is unavailable due to varied perforator architecture, perforator injury, the necessity for an intermediate thickness between the distal and proximal thigh, or the need for a chimeric flap, the AMT flap is a fantastic backup option. The ALT flap has nearly taken the role of the radial forearm and rectus abdominis flaps in current practise for tongue restoration. Major advantages over most alternative treatments are the decreased risk of donor site complications, avoidance of the requirement for skin grafts, and acceptance of the site of the resulting scar. However, some research indicates that the ALT flap in obese people exhibited extra size. Although mentioned, methods to thin the ALT flap appear to be technically challenging. Patients with oral squamous cell carcinoma have a good alternative for soft tissue reconstruction with the single perforator-based ALT flap.

The LCFA (lateral circumflex femoral artery) contains the ascending branch, oblique branch, descending branch, and transverse branch. These variations in the source of blood vessels and the number of perforators (10,11) make bi-paddle ALT free flap harvest extremely uncertain. Only 50% of through-and-through defects resulted in the lobulated flap being successfully harvested, according to Kubo et al. (12). In a study of 110 patients who underwent ALT flap surgery, Lee et al. discovered that 18.2% of the time there was only one perforator, indicating that the patient's anatomy is ineligible for a bi-paddle flap in nearly 1 in 5 instances (13). Therefore, even for skilled microsurgeons, dealing with flap harvesting failure continues to be difficult (3, 12, 14,15)

In this case, we observed that rectus femoris was a good alternative to ALT and AMT, and this can be harvested with the same incision for the latter. Forehead flaps are commonly used to cover nasal bone defects and hence are a good alternative for patients with extensive excision of oral SCC.(16,17)

IV. CONCLUSION

While ALT and AMT remain gold-standard reconstruction flaps for patients with oral squamous cell carcinoma following wide local excision, there are other viable options when there is a paucity of perforators.

REFERENCES

- [1]. Wong CH, Wei FC. Anterolateral Thigh Flap. *Head Neck* 2010;32:529-40. [Pubmed]

- [2]. Hsu CC, Loh CYY, Wei FC. The Anterolateral Thigh Perforator Flap: Its Expanding Role In Lower Extremity Reconstruction. *Clin Plast Surg* 2021;48:235-48. [Crossref] [PubMed]
- [3]. He J, Qing L, Wu P, Et Al. Individualized Design Of Double Skin Paddle Anterolateral Thigh Perforator Flaps To Repair Complex Soft Tissue Defects Of The Extremities: An Anatomical Study And Retrospective Cohort Study. *J Plast Reconstr Aesthet Surg* 2021;74:530-9. [Crossref] [PubMed]
- [4]. Fukuta T, Ichikawa Y, Mizuno H, Et Al. Split-Skin Paddle Anterolateral Thigh Flap For Reconstruction Of Giant Dermatofibrosarcoma Protuberans In Groin. *Plast Reconstr Surg Glob Open* 2019;7:E2528. [Crossref] [PubMed]
- [5]. Ahmad QG, Yadav PS, Shankhdhar VK, Et Al. Anterolateral Thigh Twin Free Flaps From A Single Donor Site-A Modification Based On The Oblique Branch Of The Lateral Circumflex Femoral Artery. *Indian J Surg* 2014;76:165-8. [Crossref] [PubMed]
- [6]. Shivanand NB, Chavre S, Chandrashekar NH, Et Al. Bi-Paddled Radial Forearm Free Flap In The Reconstruction Of Bilateral Buccal Mucosal Defects-A Case Series. *Oral Surg Oral Med Oral Pathol Oral Radiol* 2016;122:E107-9. [Crossref] [PubMed]
- [7]. Tan NC, Shih HS, Chen CC, Et Al. Distal Skin Paddle As A Monitor For Buried Anterolateral Thigh Flap In Pharyngoesophageal Reconstruction. *Oral Oncol* 2012;48:249-52. [Crossref] [PubMed]
- [8]. Marsh DJ, Chana JS. Reconstruction Of Very Large Defects: A Novel Application Of The Double Skin Paddle Anterolateral Thigh Flap Design Provides For Primary Donor-Site Closure. *J Plast Reconstr Aesthet Surg* 2010;63:120-5. [Crossref] [PubMed]
- [9]. Okazaki M, Tanaka K, Kodaira S, Et Al. One-Stage Transfer Of 2 Paddles Of Thoracodorsal Artery Perforator Flap With 1 Pair Of Vascular Anastomoses For Barraquer-Simons Syndrome. *J Craniofac Surg* 2012;23:883-5. [Crossref] [PubMed]
- [10]. Deng C, Nie K, Wei Z, Et Al. Is The Oblique Branch A Preferable Vascular Pedicle For Anterolateral Thigh Free Flaps? *J Reconstr Microsurg* 2018;34:478-84. [Crossref] [PubMed]
- [11]. Wong CH. The Oblique Branch Trap In The Harvest Of The Anterolateral Thigh Myocutaneous Flap. *Microsurgery* 2012;32:631-4. [Crossref] [PubMed]
- [12]. Kubo T, Osaki Y, Hattori R, Et Al. Reconstruction Of Through-And-Through Oromandibular Defects By The Double-Skin Paddle Fibula Osteocutaneous Flap: Can The Skin Paddle Always Be Divided? *J Plast Surg Hand Surg* 2013;47:46-9. [Crossref] [PubMed]
- [13]. Lee YC, Chen WC, Chou TM, Et Al. Anatomical Variability Of The Anterolateral Thigh Flap Perforators: Vascular Anatomy And Its Clinical Implications. *Plast Reconstr Surg* 2015;135:1097-107. [Crossref] [PubMed]
- [14]. Lakhiani C, Lee MR, Saint-Cyr M. Vascular Anatomy Of The Anterolateral Thigh Flap: A Systematic Review. *Plast Reconstr Surg* 2012;130:1254-68. [Crossref] [PubMed]
- [15]. Song D, Li J, Pafitanis G, Et Al. Bilateral Anterolateral Thigh Myocutaneous Flaps For Giant Complex Chest Wall Reconstruction. *Ann Plast Surg* 2021;87:298-309. [Crossref] [PubMed]
- [16]. Shimbo K, Okuhara Y, Yokota K. Dual Purpose Of De-Epithelialized Latissimus Dorsi Musculocutaneous Flap For Treatment Of Chronic Frontal Sinusitis And Frontal Bone Defect. *J Craniofac Surg* 2021;32:1122-5. [Crossref] [PubMed]
- [17]. Ahmed A, Visavadia BG, Farrell R, Et Al. Use Of Double Skin Paddle For Pharyngoesophageal Reconstruction Using Tubed Radial Forearm Free Flap. *Br J Oral Maxillofac Surg* 2014;52:661-3. [Crossref] [PubMed]

Description of figures

Fig 1 : Describes the preoperative lesion

Fig (2): Preoperative CT Scan film view of the patient.

Fig 3 : Intraoperatively cavity of the lesion was filled using the bulk of the free rectus femoris muscle flap and laterally based forehead flap harvested

Fig 4: Intraoperatively post anastomosis

Fig 5: Follow up picture of the patient

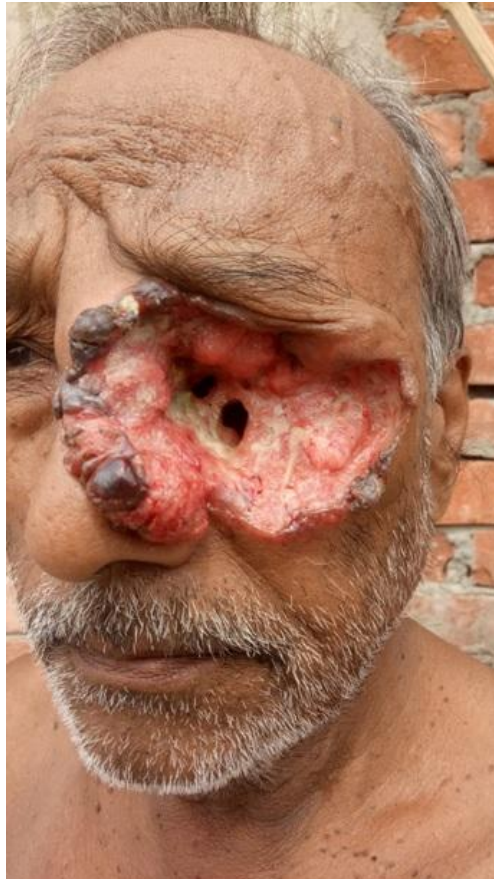

Figure 1: Your description here

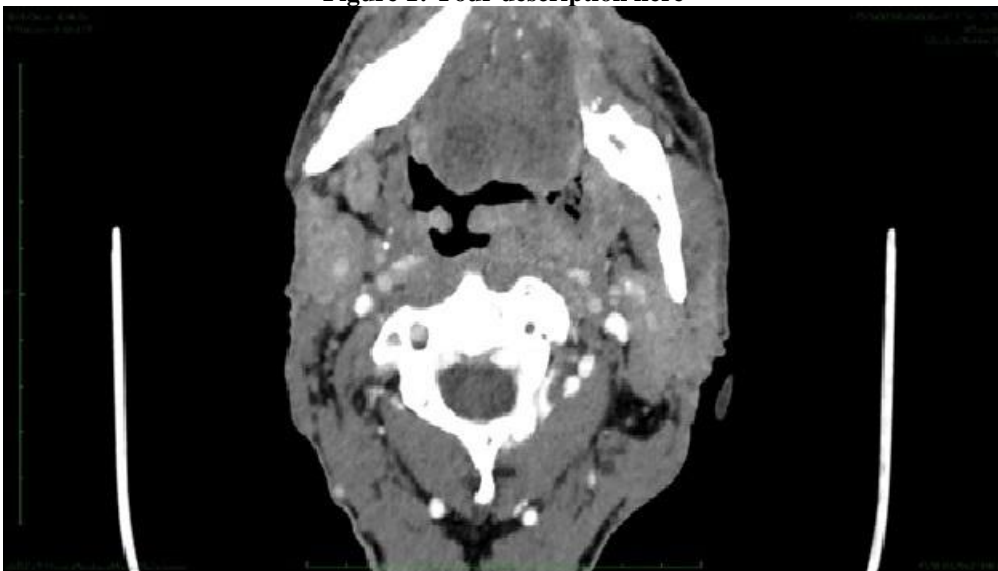


Figure 2 Description here

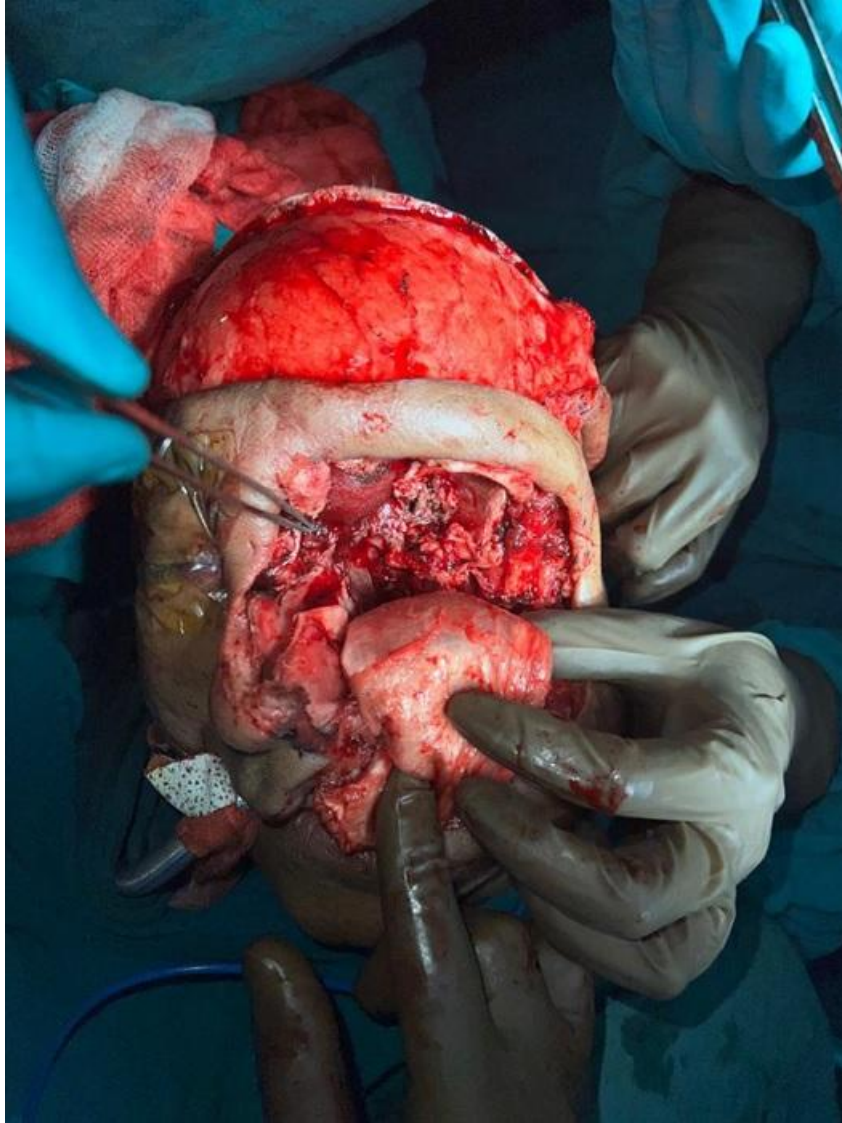

Figure 3 Description here

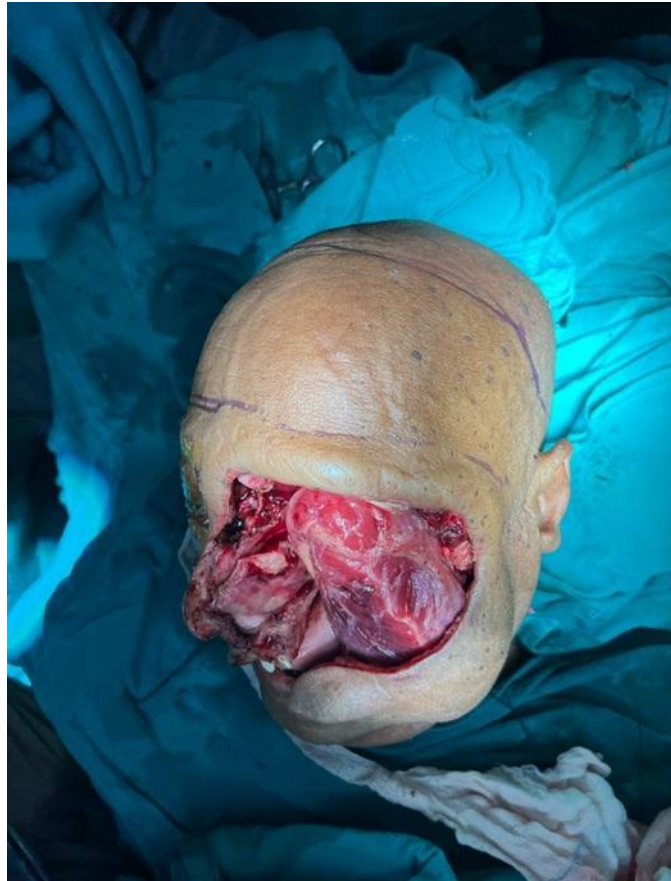

Figure 4 Description here

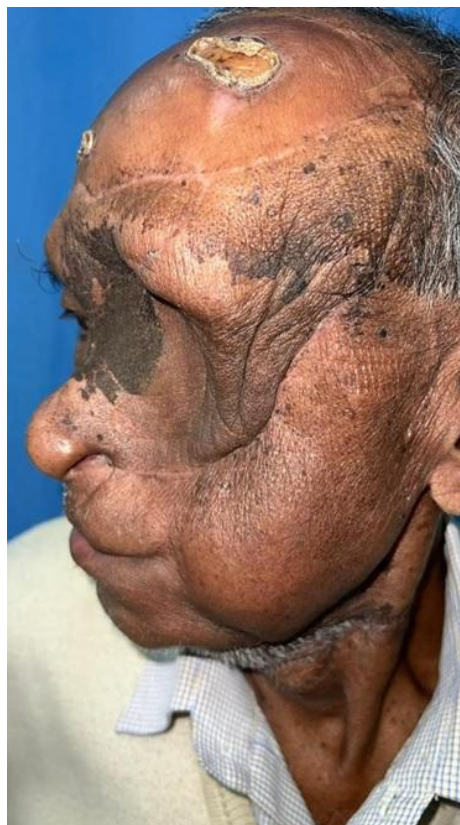

Figure 5 Description here