

## Management of Fairly Large Cervical Fibroid: A Rare Case

Dr. Khadiza Begum<sup>\*1</sup>, Dr. Saiful Islam<sup>2</sup>, Dr. Masud Ahmed<sup>3</sup>

<sup>1</sup>Consultant (Obs. & Gynae.), New Rogmukti General Hospital, Narsingdi, Dhaka, Bangladesh.

<sup>2,3</sup>Medical officer, New Rogmukti General Hospital, Narsingdi, Dhaka, Bangladesh.

### Abstract

A 45-years old woman mother of 5 children underwent a laparotomy procedure under spinal anesthesia at New Rogmukti Hospital, Narsingdi, on 28 July 2023. The surgical approach employed a Pfannenstiel incision measuring 10cm × 5cm. After opening the peritoneal cavity, a large solid mass measuring 15cm×10cm×10cm was found at the lower end of the uterus. That mass was stuck into the pelvic cavity. The patient presented with lower abdominal pain and heaviness with difficulty in voiding and defecation. She was regularly menstruating. During the physical examination, the patient was found mildly anaemic, BMI= 16kg/m<sup>2</sup>, and abdomen-distended, pelvic examination reveals a larger hand mass in the upper vagina where cervical lips were not felt around the mass. Radiological assessments demonstrated normalcy in various anatomical structures but a hypoechoic mass measuring 15cm × 10cm is seen in the cervix of the uterus. Color flow shows the presence of vascularity within the lesion. Endometrial echo is normal in thickness while laboratory results encompass hematological and immunochemistry reports, along with thyroid function and glucose levels within normal limits. The urinalysis highlighted a range of parameters, including specific gravity and pH levels within acceptable limits.

**Keywords:** cervical fibroid, laparotomy, spinal anesthesia, gallbladder, urinary bladder, uterus, cervix

Date of Submission: 08-09-2023

Date of Acceptance: 18-10-2023

### I. INTRODUCTION

Cervical fibroids, although relatively uncommon, are significant entities within the realm of gynecological conditions. These benign tumors originate in the cervix, the lower part of the uterus, and can exhibit a diverse range of clinical presentations depending on their location. Cervical leiomyomas are infrequent, constituting a mere 2% of cases. Depending on where they originate, cervical fibroids can be categorized as anterior, posterior, lateral, or central<sup>1</sup>. Symptoms associated with cervical fibroids can include discomfort and pressure-related effects such as urinary difficulties, constipation, painful intercourse (dyspareunia), and even post-coital bleeding. In some instances, these fibroids may contribute to infertility. They could also lead to uterovaginal prolapse due to a traction effect. Presentation-wise, they might resemble an abdominal mass akin to an ovarian growth or a sizable polyp. Differentiating cervical fibroids from an incarcerated procidentia or chronic uterine inversion can sometimes pose a diagnostic challenge<sup>1,2</sup>.

### II. CASE REPORT

On the operation date of 28 July 2023, at 10:00 PM, a 45-years-old lady underwent a surgical procedure at New Rogmukti Hospital, Narsingdi, involving a laparotomy under spinal anesthesia. The surgical approach utilized a Pfannenstiel incision, which measured approximately 10cm × 5cm in size. After opening the penitential cavity, a large solid mass measuring 15cm×10cm×10cm was found stuck in pelvic cavity which turned fungus and the body of the uterus as well as the urinary bladder upwards. The radiological and imaging assessment reveals unremarkable findings for most evaluated structures. The liver appears normal in size with a uniform echotexture and absence of focal lesions, and both intrahepatic biliary channels and blood vessels appear non-dilated. The gallbladder is within normal parameters, exhibiting a clear lumen and appropriate wall thickness. The common bile duct and pancreas show no signs of dilation, while the spleen and kidneys exhibit normal sizes and consistent echotextures. The urinary bladder is well-filled and displays a regular outline with no notable abnormalities. The uterus presents as normal in size and position, though a hypoechoic area is observed in the cervix, accompanied by vascularity within the lesion. Endometrial echo appears normal in thickness. Both ovaries are normal in size and echotexture. The hematology report indicates a white blood cell count of 8600, with a differential count showing 64.0% neutrophils, 28.4% lymphocytes, 5.8% monocytes, 1.8% eosinophils, and no basophils observed. Absolute counts reveal 5.51 neutrophils, 2.44 lymphocytes, 0.50 monocytes, 0.15 eosinophils, and no basophils. Red blood cell parameters include 4.11 million cells, a hemoglobin level of 10.80 g/dL, hematocrit at 34.18%, mean corpuscular volume (MCV) of 83.1, mean corpuscular hemoglobin (MCH) of 26.3, mean corpuscular hemoglobin concentration (MCHC) of 32%, and red cell distribution width (RDW) of 16.1%. The platelet count

is 309, the mean platelet volume (MPV) measures 5.7, and the erythrocyte sedimentation rate (ESR) by the Westergren method is 36. The individual's fasting blood sugar level is 5.6 mmol/L, within the reference range of 4.2-6.4 mmol/L. No fasting urine sugar is detected. The blood sugar level 2 hours after breakfast is 5.9 mmol/L, which falls below the threshold of 7.8 mmol/L or 0.3-0.8 m.mol/L. Correspondingly, there is no urine sugar present. The immunochemistry report displays the results of two tests. The CA 125 level is measured at 14.3 U/ml, falling below the reference range of <35 U/ml. For ferritin, the recorded value is 7.68 ng/ml, which lies within the normal range of 6-159 ng/ml for women and 28-397 ng/ml for men. Additionally, the thyroid function results indicate a TSH level of 2.59 uIU/ml (reference: 0.4-5.2 uIU/ml) and a Free T4 level of 1.10 Ng/dl (normal range: 0.8-2.0 Ng/dl). There is no detectable corresponding urine sugar present. The Blood group of the patient is A positive. Furthermore, the urinalysis revealed a specific gravity within the reference range of 1.003 to 1.030, a pH level of 6.5 (within the range of 4.5 to 8.0), absence of albumin, sugar, and bilirubin, normal urobilinogen levels, absence of nitrite, 11 pus cells (within the acceptable range of 0-5), and a low count of 1 epithelial cell (within the acceptable range of 0-5). No red blood cells (RBCs), hyaline casts, cellular casts, or RBC casts were observed in the microscopic examination.

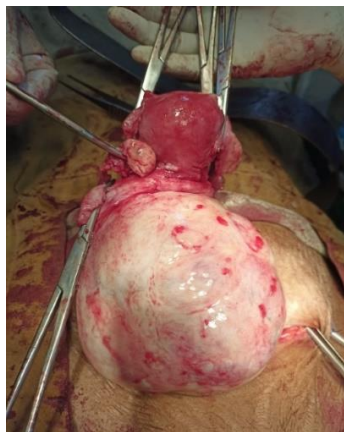


Fig-1: Large cervical fibroid.

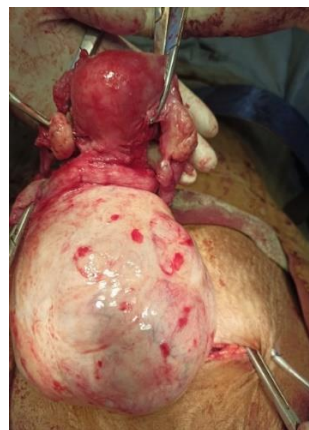

Fig-2: Fundus and body of uterus at the top of cervical fibroid.

### III. DISCUSSION

Significant cervical fibroids are seldom described in the literature in cases. Cervical fibroids seldom grow to a remarkable extent. Such growths frequently show symptoms that might be linked to pressure. The patient in this case, however, had just slight gastrointestinal pain and heaviness in lower abdomen and difficulty in voiding had essentially no noticeable symptoms. Samal SK et al, reported a case of large cervical fibroid 25x20x15 with mild hydroureteronephrosis<sup>3</sup>. In our study, the surgical approach utilized a Pfannenstiel incision, which measured approximately 10cm × 5cm in size. Central cervical fibroid expands the cervix equally in all directions and can be recognized easily on opening the abdomen because the cavity of the pelvis is filled by the tumor. Elevated on top of this fibroid is the uterus, thereby giving the appearance of “the lantern on the top of St Paul’s”<sup>3, 4</sup>. The radiological and imaging assessment reveals unremarkable findings for most evaluated structures. The cervical fibroid was carefully removed by total abdominal hysterectomy. Laparotomy is the most common mode of surgical dissection. Other management options include laparoscopic laser excision, diathermy/harmonic scalpel

loop morcellation, and uterine fibroid embolization<sup>5,6</sup>. Surgical treatment depends on the characteristics of the uterus, any concomitant uterine pathology and characteristics of myoma like number and location<sup>7,8</sup>. Additionally, hematology reports provided insight into the individual's blood cell composition, and the urinalysis results underscored the absence of abnormal components. These findings emphasize the importance of comprehensive preoperative assessments in informing clinical management decisions.

#### **IV. CONCLUSION**

In conclusion, cervical fibroids, though relatively uncommon, hold significance within gynecological conditions due to their diverse clinical presentations and potential impact on patient well-being. While they are typically associated with pressure-related symptoms, such as discomfort and urinary difficulties, cases like the one discussed here illustrate that some individuals may remain asymptomatic or experience only mild discomfort. The rarity of significant cervical fibroids underscores the need for thorough diagnostic evaluation and tailored surgical approaches, as exemplified by the Pfannenstiell incision employed in this study. Radiological assessments, along with meticulous surgical techniques like hemisection and enucleation, contribute to effective management strategies.

Funding: No funding sources

Conflict of interest: None declared

Ethical approval: Not required

#### **REFERENCE**

- [1]. Ribeiro A, Oliveira N, Moreira M, Ramos F. A Giant Cervical Fibroid: Case Report, *Clinical Case Reports International - Gynaecology And Obstetrics* 2019;3(1107):1- 2
- [2]. Gupta A, Gupta P, Manaktala U. Varied Clinical Presentations, The Role Of Magnetic Resonance Imaging In The Diagnosis, And Successful Management Of Cervical Leiomyomas: A Case-Series And Review Of Literature. *Cureus* 2018;10(5):E2653. Doi:10.7759/Cureus.2653.
- [3]. Samal SK, Rathod S, Rajsekar A, Rani R. An Unusual Presentation Of Central Cervical Fibroid: A Case Report. *Int J Res Med Sci.* 2014;2(3):1226-8.
- [4]. Mendiratta S, Dash S, Mittal R, Dath S, Sharma M, Sahai RN. Cervical Fibroid: An Uncommon Presentation, *Int J Reprod Contracept Obstet Gynecol* 2017;6:4161-3.
- [5]. Sunanda N. Large Cervical Fibroid: A Rare Case Report, *Int J Reprod Contracept Obstet Gynecol* 2019;8:3414-6.
- [6]. Wong M, Thompson OM. Large Cervical Fibroids: A Surgical Challenge, *Ultrasound In Obstetrics And Gynecology* 2015;46(1):156
- [7]. Ribeiro A, Oliveira N, Moreira M, Ramos F. A Giant Cervical Fibroid: Case Report, *Clinical Case Reports International - Gynaecology And Obstetrics* 2019;3(1107):1-2
- [8]. Gupta A, Gupta P, Manaktala U. Varied Clinical Presentations, The Role Of Magnetic Resonance Imaging In The Diagnosis, And Successful Management Of Cervical Leiomyomas: A Case-Series And Review Of Literature. *Cureus* 2018;10(5):E2653. Doi:10.7759/Cureus.2653.