

## **Obstetric Fistula Resulting From Unskilled Birth Attendance In Ilorin, Nigeria**

**Dr. Callistus Obinna Elegbua**

*Department of Obstetrics and Gynaecology, University of Ilorin Teaching Hospital Ilorin, Kwara State.*

**Dr. Angela Adaku Elegbua**

*Department of Community Medicine and Epidermiology, University of Ilorin Teaching Hospital Ilorin, Kwara State.*

**Dr. Abiodun Suleiman Adeniran**

*Department of Obstetrics and Gynaecology, University of Ilorin Teaching Hospital Ilorin, Kwara State.*

---

### **Abstract**

*Obstetric fistula is one of the major dehumanizing complications of poorly managed labour. It is a serious burden to the individual and her family members and results in psychological, physical, mental and social trauma. The commonest cause of obstetric fistula is prolonged obstructed labour which contributes tremendously to maternal morbidity and mortality. This is a case of a 22-year-old woman who presented to us in the Teaching Hospital with a history of fever, lower abdominal pain, foul-smelling vaginal discharge and leakage of urine and faeces through the vagina of one week duration following a delivery of a macerated stillbirth by unskilled birth attendance. Diagnosis of puerperal sepsis and obstetric fistula were made but unfortunately, she discharged against medical advice prior to the planned fistula repair.*

**Keywords:** *Fistula, Obstetric, Birth, Unskilled, Attendance.*

---

Date of Submission: 27-09-2023

Date of acceptance: 07-10-2023

---

### **I. INTRODUCTION**

Obstetric fistula is one of the devastating morbidities associated with childbirth especially in the low-income countries. It results in mental, psychological, social and physical trauma to the individual. It occurs mostly as a result of prolonged or obstructed labour particularly in young pregnant women<sup>1</sup>. Obstetric fistula is defined by World Health Organization as an abnormal opening between female private parts such as vagina, bladder and rectum leading to continuous leakage of urine or faeces<sup>2</sup>. Though the commonest causes of obstetric fistula are prolonged and obstructed labour; factors contributing to it include quack obstetric practice, illiteracy, poverty, poor health seeking behaviour, inadequate obstetric care services, lack of skilled birth attendants and poor referral system<sup>3</sup>. The purpose of this report carried out in a low-resource setting is to create awareness that unskilled birth attendance is a menace to the community and also illiteracy impacts negatively on health seeking behaviour. In view of the paucity of case reports on this topic in Nigeria and none has been documented in Ilorin, reporting this case will indeed add to the body of evidence.

She was a 22-year-old now para one (not alive) woman who presented to us in the University of Ilorin Teaching Hospital Ilorin, Nigeria with a history of fever, lower abdominal pain, foul-smelling vaginal discharge and leakage of urine and faeces through the vagina of one-week duration. Fever was high-grade in nature and continuous with no relieving factor. Abdominal pain was gradual in onset but later increased in both frequency and intensity. Subsequently she started noticing purulent foul-smelling vaginal discharge, inability to control urine and faeces and drainage of both urine and faeces per vaginam. There was no urge incontinence and the faeces was watery.

Two weeks prior to presentation to us she patronized a patent medicine dealer while in labour who monitored the labour in his house and conducted the delivery of a macerated male stillbirth after two days of prolonged labour. She was kept for observation in the place of delivery until the above-mentioned symptoms developed before, she sought medical intervention by coming to the Teaching Hospital.

Pregnancy was unbooked in any hospital, not desired and spontaneously conceived. She did not receive any antenatal care and was not on any hematinics throughout the pregnancy. She was the third child in a monogamous family setting of five children, not married and her highest level of education was primary school. She did not have any source of income and both parents had no formal education. She was impregnated by a 25-year-old secondary school drop-out who refused to take responsibility of the pregnancy.

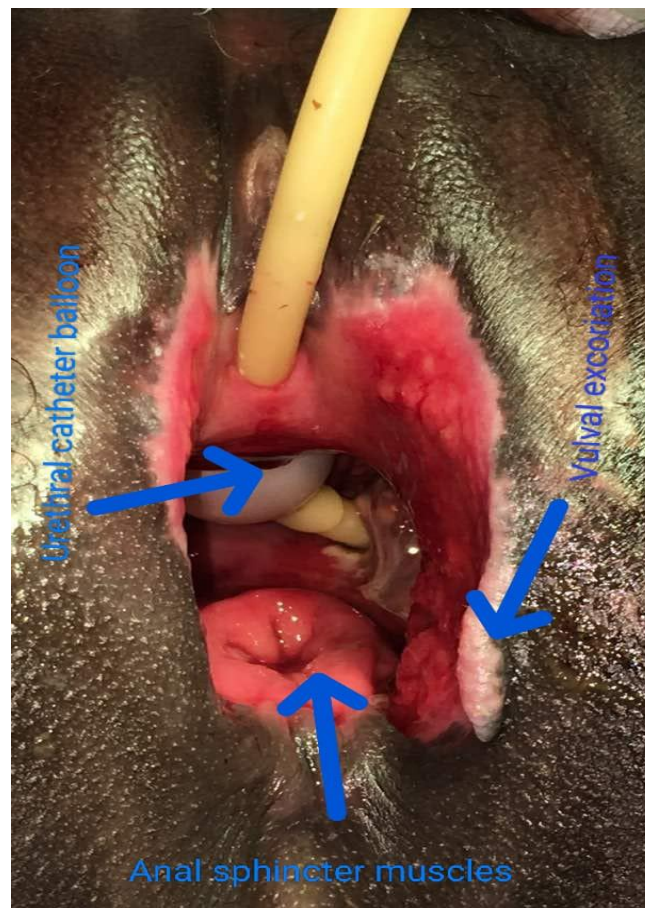
On general examination at presentation to us she was conscious and alert though depressed, severely pale, anicteric, acyanosed, moderately dehydrated and no pedal oedema. Pulse rate was fast and tready (120b/m) and there was hypotension (90/60mmHg). Respiratory rate was normal, chest was clear clinically, vesicular breath sound and heart sounds were normal. Body temperature was 40°C.

Abdominal examination revealed lower abdominal tenderness with guarding and rebound tenderness. The uterus was tender to touch and there was sub- involution (22 weeks size uterus).

On pelvic examination, yellowish foul-smelling vulval discharge was observed. There were necrotic tissues and fecal matter around the vulva and perineum and the anatomy of these regions was distorted. About 4cm of the distal portion of the vaginal wall has sloughed off that part of the inserted urethral catheter, its inflated ballon and the anal muscles could be visualized through the vulva thus, showing wide multiple fistulae involving the bladder, vagina and rectum. Urine was observed trickling down from the urethra and bladder irrespective of the presence of the urethral catheter that was inserted at presentation. Irrespective of how obvious the fistulae were methylene blue dye test was conducted to check for presence of tiny fistulae. Diagnosis of puerperal sepsis and obstetric fistula were made.

The following investigations were carried out; full blood count which showed packed cell volume of 18%, elevated white blood cells and normal platelet, serum electrolyte, urea and creatinine which were essentially normal and abdominopelvic ultrasonography which detected bulky uterus. She had six unit of blood transfused and intravenous 10mls of 10% calcium gluconate was given to prevent hypocalcemia due to blood transfusion. She also had broad-spectrum antibiotics which took care of the sepsis. Twice daily vulval and perineal cleaning with antiseptics was instituted while continuous bladder draining with a urethral catheter continued. A multidisciplinary approach of management involving the urogynaecologists, general surgeons, urologists and plastic surgeons was instituted with the aim of creating a colostomy, repairing the fistulae and reconstructive surgery where applicable after the treatment of infection.

However, while the vulval and perineal wounds were granulating well and signs and symptoms of sepsis were gone the patient in collaboration with her parents discharged herself against medical advice. She promised to come back for the fistulae repair but was lost to follow up.



**Figure 1: Multiple pelvic organ fistulae involving the urinary bladder, vagina and rectum. Arrows show urethral catheter balloon herniating through the vesico-vaginal fistula, anal sphincter muscles visible via recto-vaginal fistula and vulval excoriation.**

## II. DISCUSSIONS

Obstetric fistula is an abnormal opening between a woman's genital tract and her urinary tract or rectum causing urinary and faecal incontinence, ongoing genital infections, anaemia and neurological symptoms of the lower limb<sup>4</sup>. Prolonged obstructed labour is the most common cause of obstetric fistula. In most cases the pregnancy outcome is stillbirth and future fertility is at risk if cervical damage occurs<sup>5</sup>. The index case agreed with the above statement because it was a prolonged obstructed labour managed by a quack and resulted in macerated stillbirth.

Obstetric fistula being a devastating and stigmatizing condition impacts negatively on the mental and social state of the individual as well as the marital relationship<sup>6</sup>. Annually, between 50 000 to 100 000 women globally are affected by obstetric fistula and more than 2 million young women live with untreated obstetric fistula in Asia and sub-Saharan Africa<sup>7</sup>. This was applicable to our patient who discharged herself against medical advice prior to the planned fistula repair and was lost to follow up.

Socio-cultural factors contributing to obstructed labour include; lack of access to maternal health services, poverty, lack of education, reduced role of women in decision making, early marriage, harmful traditional practices such as Female Genital Mutilation, lack of access to and uptake of family planning resulting in the planned spacing of childbearing. Our patient had only primary level of education. Girl-child education empowers a woman to play active role in decision making concerning her health.

Obstructed labour which subsequently results in obstetric fistula can be prevented by delaying the age of first pregnancy so that the pelvic ring will be fully developed, cessation of harmful traditional practices, timely access to maternal and obstetric care thus avoiding the three levels of delay<sup>7</sup>.

Obstetric fistula affects the renal system, the female reproductive system and in obstructed labour; the neurological system and consequently the musculoskeletal system of the lower limbs<sup>8</sup>. The fistula involves an abnormal opening between the vagina and the bladder (a vesico-vaginal fistula or VVF) or the vagina and the rectum (a recto-vaginal fistula RVF). The case reported had both vesico-vaginal and recto-vaginal fistulae. Renal damage includes; bladder tissue loss from necrosis causing reduced volume and reduced bladder compliance, fibrosis of the urethra causing urine incontinence, substantial damage to the bladder neck affecting the ureteral orifices and ascending infection to the kidneys. Genital tract injuries include; fibrosis and stenosis of the vagina leading to infertility, cervical and uterine injury causing Asherman's syndrome, pelvic and cervical incompetence. Neurological injuries include; lumbo-sacral plexus compression during the obstruction resulting in lower limb neurological deficiencies, such as altered sensation, muscle weakness and contractures, peroneal nerve compression caused by prolonged squatting during labour and result in foot drop and neurogenic bladder from bladder nerve injury. Musculoskeletal injuries include; foot drop and resulting contractures, muscle weakness from nerve injury and dysfunctional pelvic floor muscle group and connective tissue.

Obstetric fistula intervention involves surgery by specially trained surgeons, supportive nursing pre- and post-operative care including catheter management and education, physical rehabilitation to address nerve injury, musculoskeletal issues, gait disturbances and pelvic floor deficiency<sup>5</sup>. Other form of care include education on the cause of the injuries and incontinence, the treatment and the rehabilitation required as well as psychological support<sup>10</sup>.

## III. CONCLUSION

Unskilled birth attendance and inadequate girl-child education are instrumental to maternal morbidity.

## REFERENCES

- [1]. Kalembo FW, Zgambo M. Obstetric Fistula: A Hidden Public Health Problem In Sub-Saharan Africa. *Arts Soc Sci J* 2012;41:1-8.
- [2]. World Health Organization. *Obstetric Fistula*; World Health Organization; 1991. Available From: [Http://Www.Who\\_MCH\\_MSM\\_91.5.Pdf](http://www.who_mch_msm_91.5.pdf).
- [3]. Swain D, Parida SP, Jena SK, Das M, Das H. Obstetric Fistula: A Challenge To Public Health. *Indian J Public Health* 2019;63:73-8.
- [4]. Muleta M, Hamlin C, Fantahun M, Kennedy R And Tafesse B. Health And Social Problems Encountered By Treated And Untreated Obstetric Fistula Patients In Rural Ethiopia. *Journal Of Obstetrics And Gynaecology Canada*. 2008.30(1). Pp. 44-50. 30(1). Pp. 44-50
- [5]. Lombard L, St. Jorre J, Geddes R, El Ayadi A And Grant L. Rehabilitation Experiences After Obstetric Fistula Repair: Systematic Review Of Qualitative Studies. *Tropical Medicine And International Health*. 2015 20(5). Pp. 554-568
- [6]. Desalliers J, Pare ME, Kouraogo S And Corcos J. Impact Of Surgery On Quality Of Life Of Women With Obstetric Fistula: A Qualitative Study In Burkina Faso. *International Urogynecological Journal*. 2017. 28(7). Pp.1091- 1100.
- [7]. World Health Organisation. *Obstetric Fistula* [Online]. 2021. Available From: [Https://Www.Who.Int/News-Room/Facts-In-Pictures/Detail/10-Facts-On-Obstetric-Fistula](https://www.who.int/news-room/facts-in-pictures/detail/10-facts-on-obstetric-fistula).
- [8]. Wall LL, Arrowsmith SD, Briggs ND, Lasseby A. Urinary Incontinence In The Developing World: The Obstetric Fistula. *Proceedings Of The Second International Consultation On Urinary Incontinence, Paris 2001:1-67*.
- [9]. Vogel JD, Johnson EK, Morris AM, Paquette IM, Saclarides TJ, Feingold DL Steele SR. *Clinical Practice Guideline For The Management Of Anorectal Abscess, Fistula-In-Ano, And Rectovaginal Fistula. Diseases Of The Colon & Rectum*. 2016 59:12.
- [10]. Lewis G, De Bernis L. *Obstetric Fistula: Guiding Principles For Clinical Management And Programme Development*. Prepared For World Health Organisation.2006.