

## Giant Anterior Abdominal Wall Lipoma- Case Report

1. Dr.K.S.Saravana Raju MS(GS)

2. Dr.P.Balamurugan MS(GS) 3. Dr.M.Vennila MS(GS).

1,2,3 Senior assistant professor, department of general surgery, GMC & ESI hospital,  
Coimbatore.Tamilnadu,India.

---

### **Abstract:**

Lipoma are benign tumor composed of adipose tissue. They may be localized and almost all part of body. Rarely lipomas can grow to acquire gigantic proportions, turning into an entity termed as giant lipoma. Some of these giant lipomas may transform malignant. Giant lipoma cause problem in daily living and deteriorate quality of life. Mass localization also restrict body functions.

**Keywords:** Giant lipoma, Pseudo lipoma, Mass, Surgery, Quality of life.

---

Date of Submission: 01-01-2023

Date of Acceptance: 11-01-2023

---

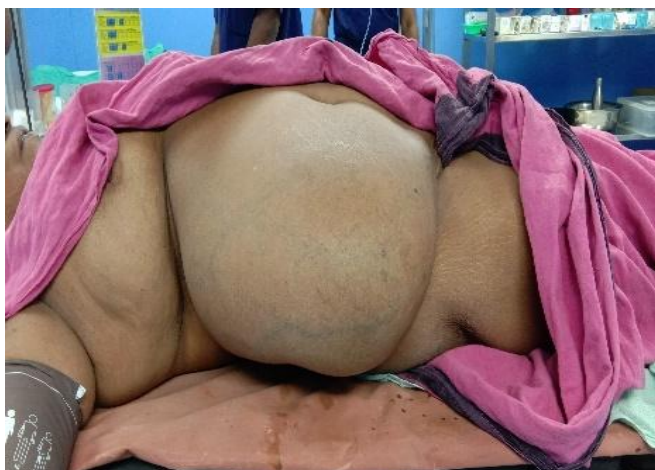### **I. Introduction**

Lipoma is a slow growing benign tumor of adipose tissue and can occur anywhere in the body. Hence, it is also known as universal or ubiquitous tumor. Usually, lipomas develop on the extremities and trunk. However, 13% of lipomas grow in the head and neck region. A lipoma is considered giant when it is greater than 10 cm in any dimension or weighs more than 1000 gm. We hereby report a rare case of giant abdominal wall lipoma which was around 42cm in greatest dimension affecting the quality of life and daily day today activity.

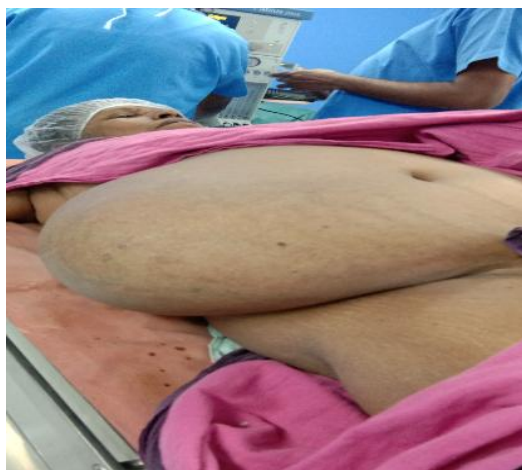### **II. Case Report**

72-years-old women reported in surgical OPD with a giant lump hanging from the right side of abdomen. The swelling was present for the past 35 years. It was insidious in onset and was of small size when she noticed it first. It gradually increased in size to attain the present gigantic proportions. There was no history of pain and sudden change in size of swelling. There was not any history of trauma, fever, loss of appetite, loss of weight, difficulty in breathing. Personal and family histories were unremarkable. General and systemic examinations were unremarkable. Upon local examination, a huge lump was evident hanging upon anterior aspect of the right side of abdomen. It was approximately 28cm × 28 cm × 26cm in dimensions and occupying right hypochondrium, right lumbar, and extending up to right iliac fossa and from here the mass was hanging freely (figure 1,2 & 3). The surface appeared to be lobulated. The overlying skin was normal with dilated veins seen. It was soft in consistency. The surface was lobulated. The lump was not fixed to the overlying skin and surrounding structures. There was no regional lymph node enlargement. Sensory and motor examination of Right lower limb was normal. Per rectal Examination was normal. A provisional diagnosis of lipoma was made. Routine investigations were unremarkable. FNAC (figure 10) from the swelling was suggestive of a benign lipoma. A contrast enhanced CT scan of abdomen was obtained to rule out any suspicious foci of malignant transformation in the mass. The mass however turned out to be essentially benign and showed no infiltration of surrounding vital structures.

**Fig: 1** (Lateral view)



**Fig: 2** (Oblique view)



**Fig: 3** ( On supine)

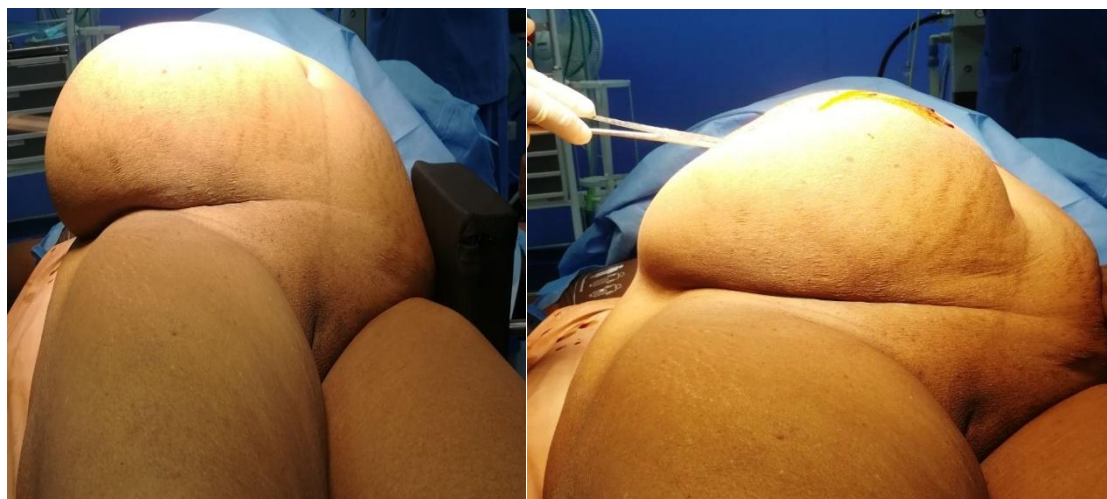
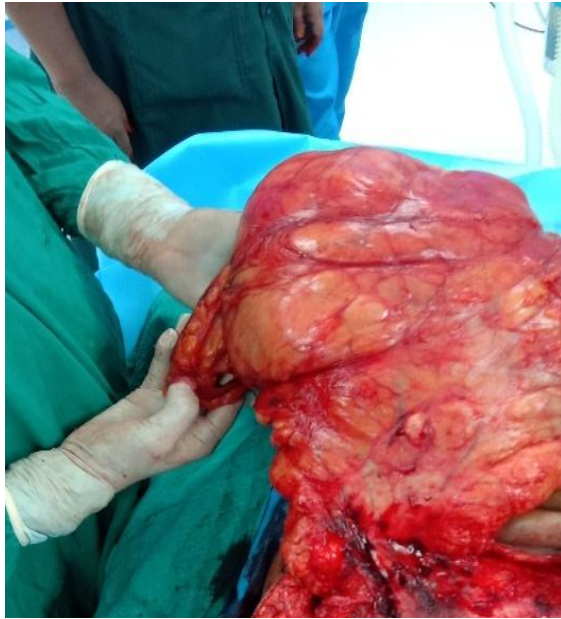
Fig 1, 2 and 3 Pre-operative pictures.

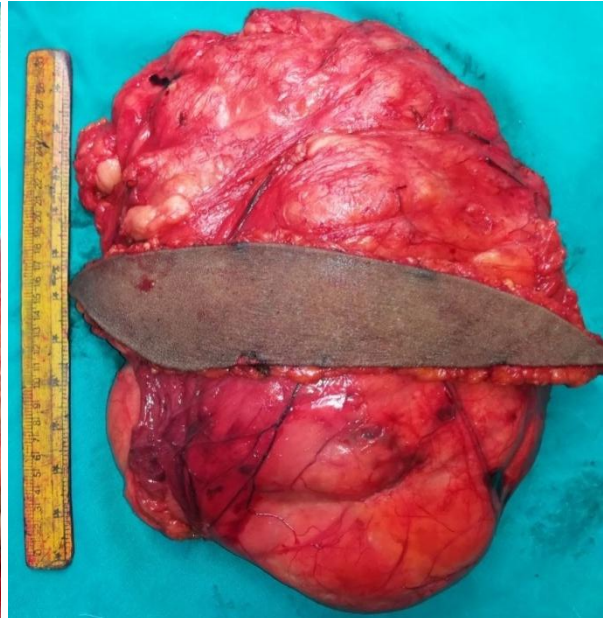The patient was taken up for surgery after proper preanesthetic checkup. The mass was excised completely under spinal anaesthesia through an elliptical incision, weighed about 3.9kgs (figure 4,5,6 & 7) and sent for histopathological examination.

Postoperative period was uneventful. Histopathology (figure 11) report confirmed the finding of lipoma. The patient was doing well until his last follow-up visit (figure 8 & 9).

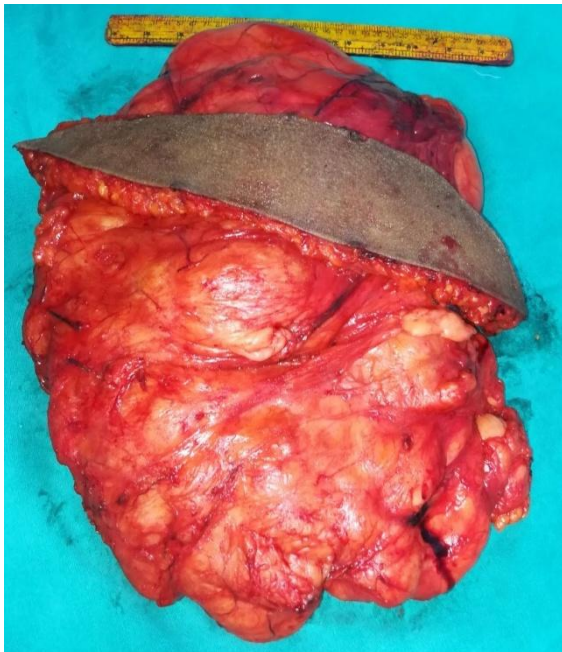**Fig :4**



**Fig :5**



**Fig :6**



**Fig :7**

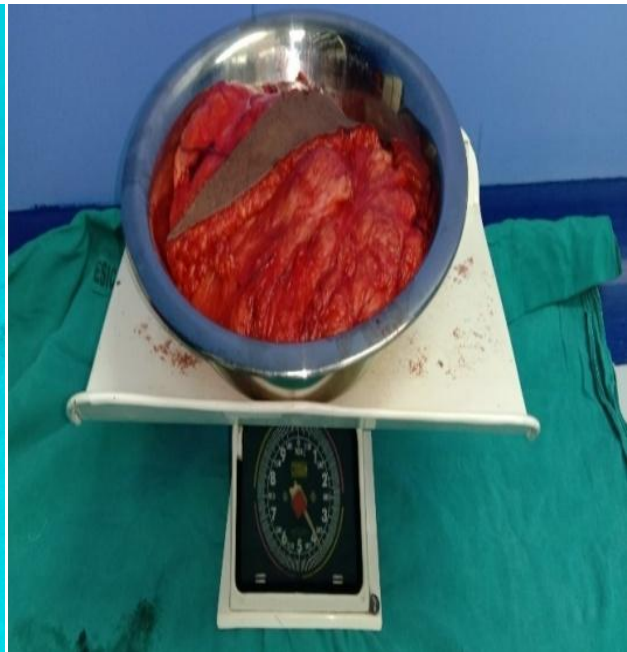
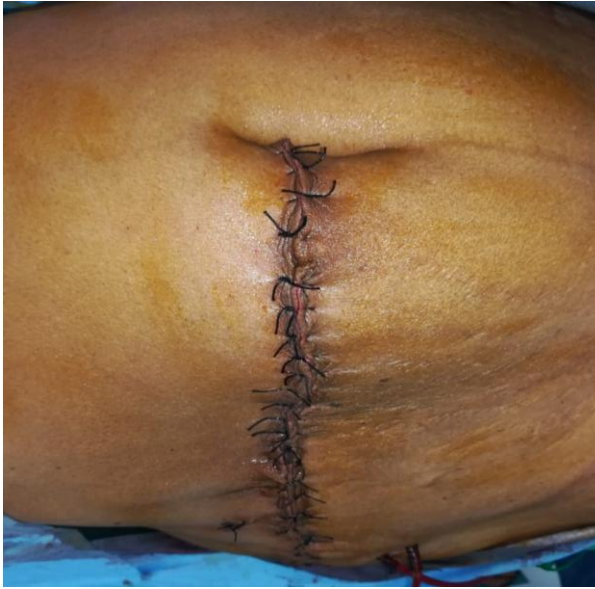

Fig: 4,5,6 & 7 Intra op pictures.

**Fig :8**



**Fig:9**

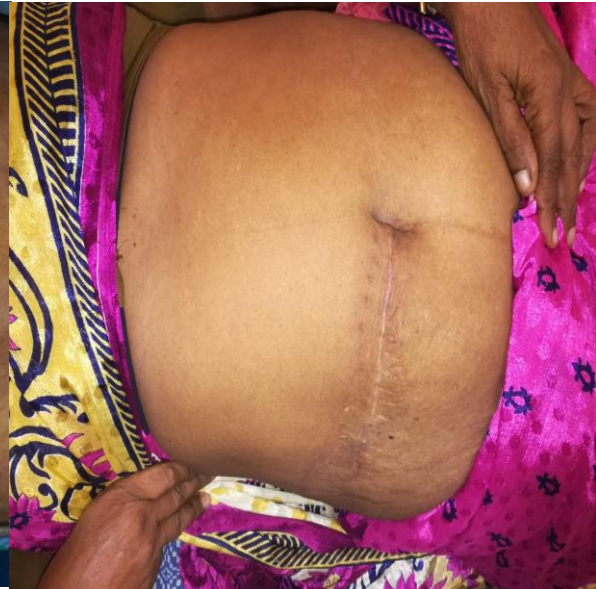

Fig 8 and 9 Post operative pictures

**Fig :10**

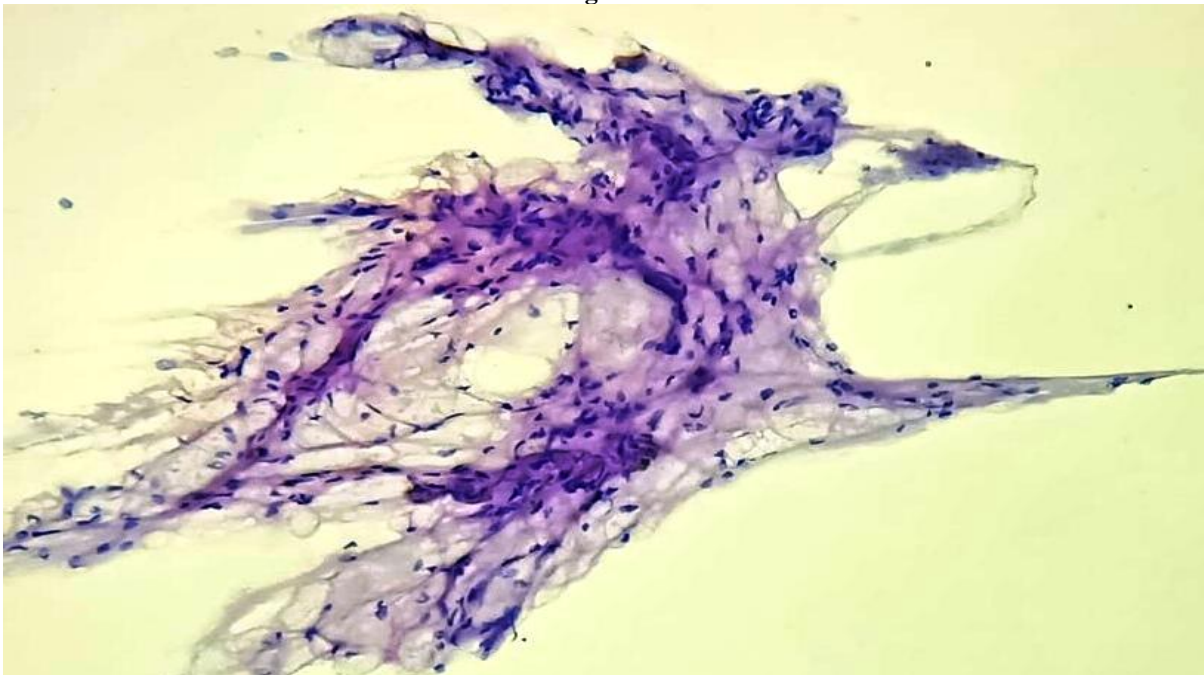
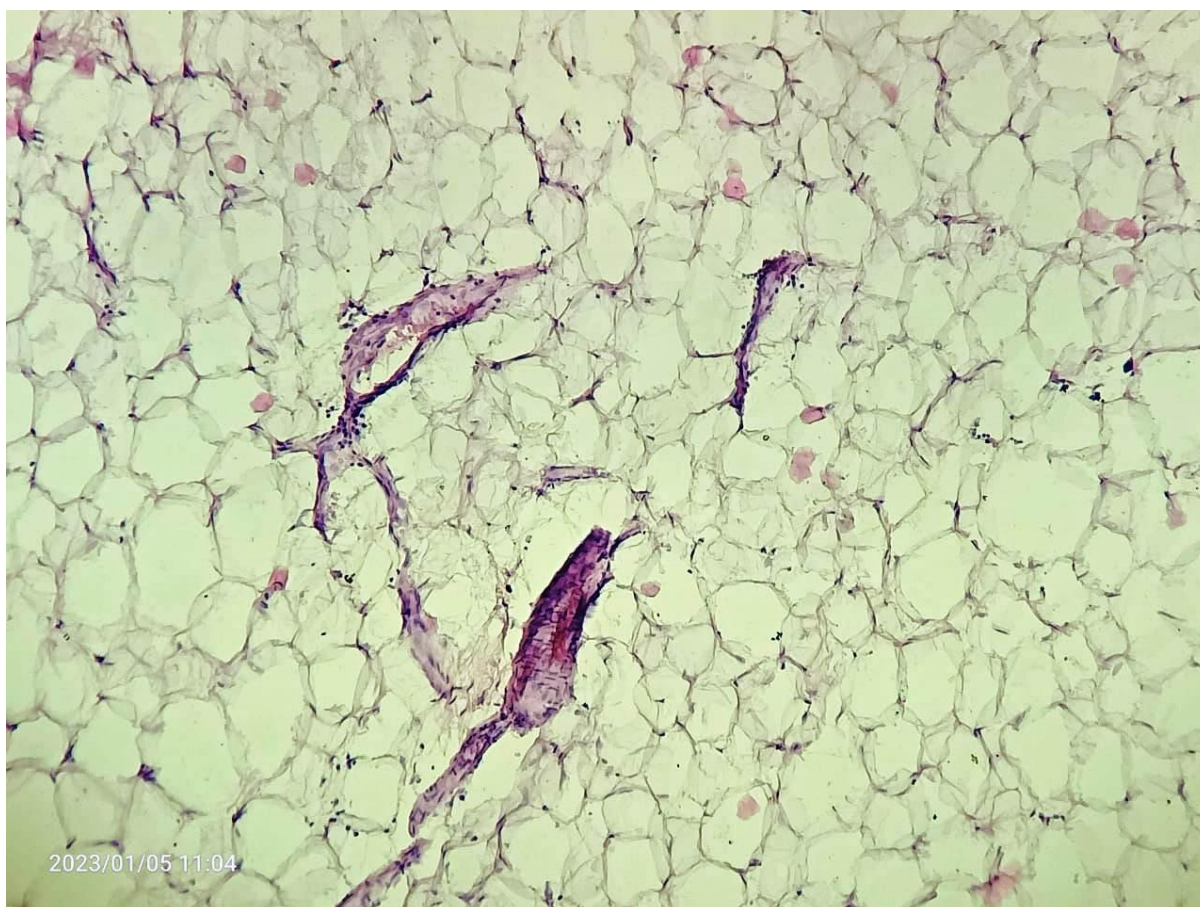


Fig 10 FNAC slide – smear shows mature adipocytic cluster with attached lining of endothelium.

**Fig :11**



**Fig:11.** Histology shows sheets of adipocytes with tiny capillaries.

### **III. Discussion**

Lipomas are typically slow growing tumors and only a few grow into the massive lump known as giant lipoma. Mechanism behind such gigantic growth is unclear. A few studies have postulated the role of trauma, suggesting that blunt trauma can cause rupture of the fibrous septa and anchorage connections between the skin and deep fascia, allowing the adipose tissue to proliferate rapidly. One theory suggests that trauma-related fat herniation through tissue planes creates so-called pseudo lipomas.

It has also been suggested that trauma-induced cytokine release triggers pre-adipocyte differentiation and maturation. Regardless of the mechanism, the main concern while dealing with a giant lipoma is to rule out malignancy. Liposarcoma is the most common soft tissue malignancy in the long-standing lipomas; however, such occurrence is very rare. Histopathological features of dedifferentiation are the hallmark of malignant change in a benign lipoma. Dedifferentiated liposarcomas occur most frequently in the sites in which there is a chance of delayed diagnosis such as retroperitoneum. Therefore, malignant changes in giant lipomas are most commonly encountered in the retroperitoneum.

Benign or malignant nature of a lipomatous lesion has to be established by various investigations such as ultrasonography, CT scan, and fine needle aspiration cytology. In our case, benign nature of the lipoma was confirmed by FNAC and CT scan of abdomen.

### **IV. Conclusion**

The treatment of choice for the lipoma remains open surgical excision. It is a relatively straight forward procedure, considering the encapsulated nature of lipoma. Blunt dissection along with an optimal hemostasis usually serves the purpose and preserves the surrounding structures as well. In the end, a careful histopathological examination of the excised specimen is necessary to rule out malignancy and to ensure the longevity of patient.

### References

- [1]. Martin H.S. Massive lipoma of the subcutaneous tissue of the back: report of case. *JAMA*. 1928; 90:2013–2015. [Google Scholar]
- [2]. Bissel A.H. Large lipoma of back. *Am. J. Surg.* 1929; 6:366–367. [Google Scholar]
- [3]. Silistreli O.K., Durmuş E.U., Ulusal B.G., Oztan Y., Görgü M. What should be the treatment modality in giant cutaneous lipomas? Review of the literature and report of 4 cases. *Br. J. Plast. Surg.* 2005;58(3):394–398. [PubMed] [Google Scholar]
- [4]. Aydoğdu E., Yıldırym S., Eker G., Aköz T. Giant lipoma of the back. *Dermatol. Surg.* 2004;30(1):121–122. [PubMed] [Google Scholar]
- [5]. Terzioglu A., Tuncali D., Yuksel A., Bingul F., Aslan G. Giant lipomas: a series of 12 consecutive cases and a giant liposarcoma of the thigh. *Dermatol. Surg.* 2004;30(3):463–467. [PubMed] [Google Scholar]
- [6]. Sanchez M.R., Golomb F.M., Moy J.A., Potozkin J.R. Giant lipoma: case report and review of the literature. *J. Am. Acad. Dermatol.* 1993;28(2 Pt 1):266–268. [PubMed] [Google Scholar]
- [7]. Rubinstein A., Goor Y., Gazit E., Cabili S. Non-symmetric subcutaneous lipomatosis associated with familial combined hyperlipidemia. *Br. J. Dermatol.* 1989;120(5):689–694. [PubMed] [Google Scholar]

Dr.K.S.Saravana Raju MS(GS), et. al. “Giant Anterior Abdominal Wall Lipoma- Case Report.”  
*IOSR Journal of Dental and Medical Sciences (IOSR-JDMS)*, 22(1), 2023, pp. 11-16.