

Ocular Metastasis: A Case Report

Dr. Monika Prajapati , Dr. Kinjal Trivedi
(Ophthalmology , B J medical college/Gujarat university , India)

Abstract:

Background: Metastatic carcinoma is the most common malignant tumor of the eye. Choroid is the most common site for intraocular metastasis because of high vascular supply. Lung carcinoma metastasizes most frequently in men and breast carcinoma in women. Systemic chemotherapy is most commonly used as treatment options for choroidal metastasis. Intravitreal bevacizumab is a therapeutic option with rapid effect in the treatment of choroidal metastatic tumors unresponsive to systemic therapy. Multidisciplinary team approach should be used to manage. The purpose of treatment is to improve quality of life and prolong survival.

Conclusion: Choroid is most common site for intraocular metastasis. Ophthalmic examination and thorough systemic investigations should be done to identify primary tumor.

Keyword: Malignant tumor, choroidal metastasis, chemotherapy, intravitreal bevacizumab

Date of Submission: 27-12-2022

Date of Acceptance: 07-01-2023

I. Introduction :

The eye is a rare site for disseminated malignancy because of the absence of a lymphatic system. Metastases to the ocular structures occur by hematogenous spread and therefore the parts of the eye with the best vascular supply (choroid) are most likely to be affected. Many patients with Stage 4 carcinoma (distal metastatic spread) already have a history of a previous primary cancer. [1]

The incidence of intraocular metastases is about 8%–10%. Approximately 88% of eye metastases occur in the choroid, with the majority originating from breast cancer (47%) and lung cancer (21%). [2]

The most common site of metastasis in posterior uvea (88%) is choroid, follow by iris (9%) , and the ciliary body (2%). The distribution of posterior pole involvement of the eyeball equator is roughly temporal (35%) , upper (22%) , lower (17%) , nasal (14%), the macular (12%). [3]

Treatment are focused on improving the patients' quality of life, if visual acuity is threatened. Long term side effects of the treatment also need to be considered. Timely diagnosis and interventions are extremely important because of the poor prognosis.

The treatment of choroidal metastasis is also based on various factors like physical well being of patient, number and location of primary tumor , presence and absence of distant metastasis, and the location and number of intraocular metastasis.

Therapy is roughly divided into: systemic therapy, systemic therapy combined with local therapy (for instance ocular radiotherapy and Intravitreal bevacizumab), and local treatment alone. [3].

Systemic chemotherapy is most commonly used as treatment option for choroidal metastasis, if lesion is enlarged during the treatment, modalities such as external beam radiotherapy, plaque brachytherapy and photodynamic therapy are employed. Intravitreal bevacizumab administration represented an efficacious therapeutic option with rapid effect in the treatment of choroidal metastatic tumors unresponsive to systemic therapy. It can have a role in the management of these tumors by preventing vision loss and improving the quality of life of patients. [7]

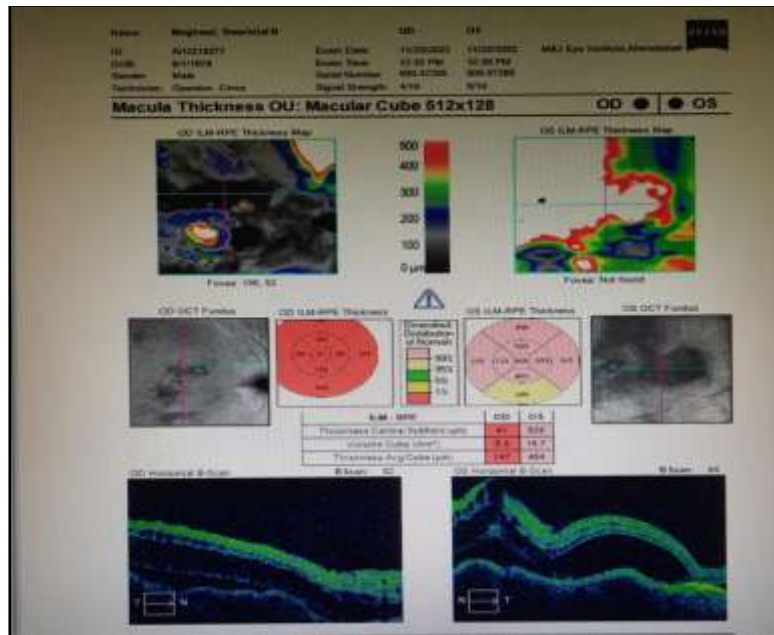
II. Case Report:

A 42 year old male patient presented with complaints of blurring of vision in both eyes. He had no other ocular history. Before 3 months patient was presented to oncologist with complaints of abdominal pain and vomiting where patient was advised Ct scan thorax , abdomen and pelvis and diagnosed with primary ascending colon carcinoma with metastasis to liver and lung. Patient was also advised MRI brain but because of poor general condition of patient MRI was not done.

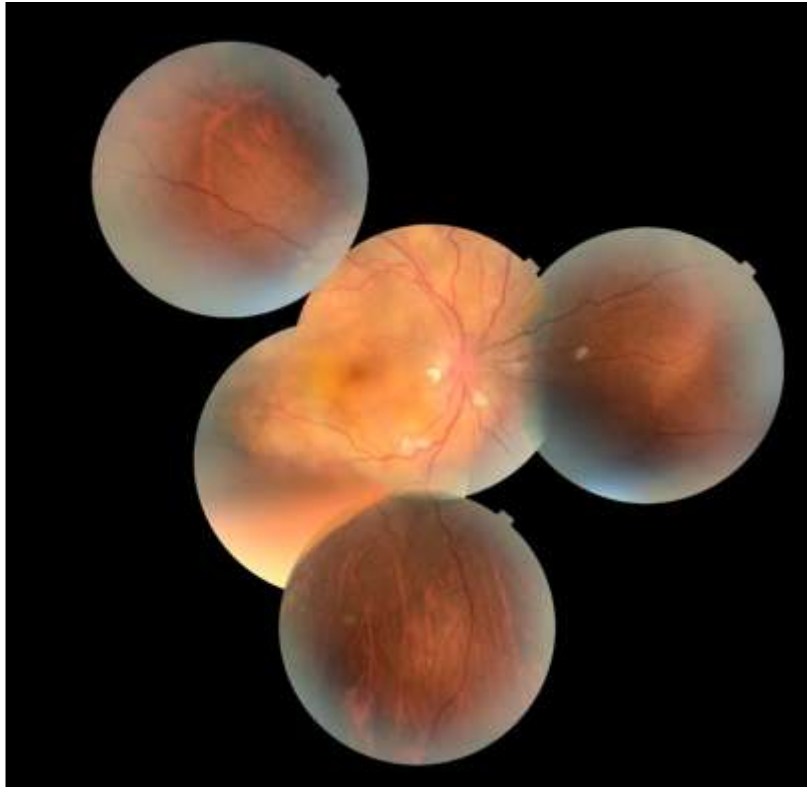
On examination, patient's unaided vision in both eyes was counting finger 1 meter , which was not improved with subjective correction. Anterior segment was within normal limits. Fundus examination of both eyes by indirect ophthalmoscope revealed blurring of all disc margins with peripapillary scattered cotton wool spots and choroidal infiltration with exudative retinal detachment over posterior pole with peripheral multiple dot blot hemorrhages present. Posterior segment optical coherence tomography (PSOCT) of both eyes shows

'lumpy' choroidal surface and thickening of retinal pigment epithelium along with overlying large pockets of sub retinal fluid. In RE PS - OCT machine wrongly estimate the central foveal thickness; it shows hypo reflective space behind the hyper reflective inner retinal layer, hence before interpreting we should always know the limitations of OCT machine. Fundus fluorescent angiography was advised for patient but fitness was not given by oncologist because of altered systemic parameters . Blood investigation (Hb :10.20 g/dl , WBC : 12000cells/cu.mm , RBS : 110mg /dl , S. Na+: 185mEq/L , S. K+: 9.9mEq/L , S. Creatinine: 4.4mg/dl ,S. Urea: 80mg/dl)

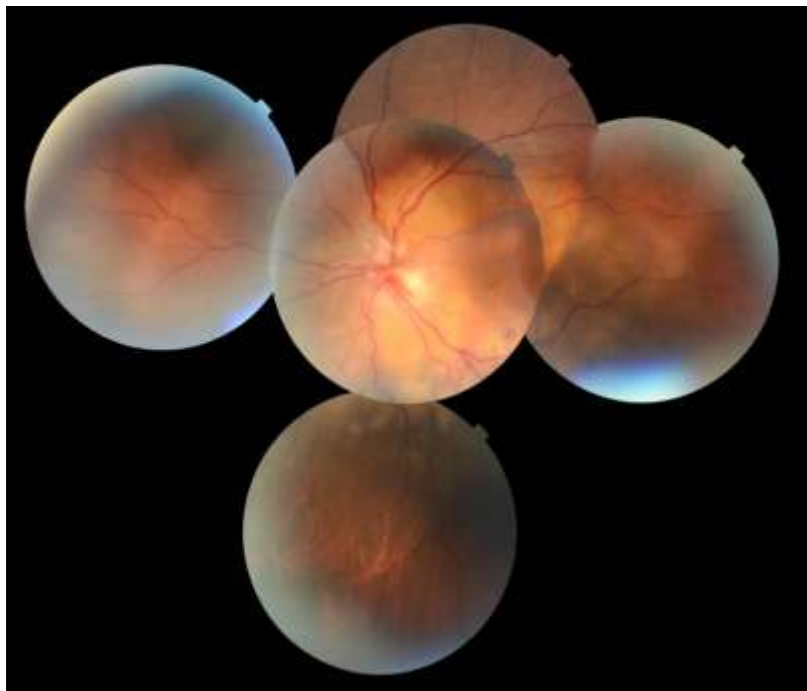So our provisional diagnosis of both eye choroidal metastasis with optic nerve infiltration was made . As patient presented with diagnosed colon carcinoma with liver and lung metastasis , patient was advised Intravitreal bevacizumab but because of poor general condition of the patient injection could not be given and systemic chemotherapy was not advised by oncologist . He was managed with palliative care. (T. Morphine , C. Pregabalin) .



BOTH EYE PS-OCT



RIGHT EYE



LEFT EYE

III. Discussion:

Our case report shows choroidal involvement with optic nerve infiltration in primary ascending colon carcinoma.

ShieldsCL et al did survey of 520 eyes with uveal metastasis and showed that choroid was involved in 88% of cases, hence supporting that choroid is most common site for ocular metastasis[2].

Singh N et al through a report of 3 cases and systemic review of literature showed most common primary site for metastasis in male is lung and for female is breast[5]. However in our case primary tumor causing choroidal metastasis is colon carcinoma which is not common.

Methis T et al studied diagnosis and management of choroidal metastasis. They showed that blurred vision occurs in 55-70% of patients, pain and floaters in 12% this making blurred vision as most common ocular symptom at presentation [6]. Similar complaint of blurring of vision was reported by our patient but in our case it was not accompanied by pain.

Fancia v et al in a case series showed that Intravitreal bevacizumab is the treatment of choice for choroidal metastases secondary to lung and breast cancer unresponsive to systemic therapy [7]

In our case also we advised for the Intravitreal anti VEGF in both eyes apart from systemic management, but because of poor general condition of patient injection could not be given and patient was kept on palliative care.

IV. Conclusion:

Choroid is the most common site for intraocular metastasis because of high vascular supply. Up to one third of the patients present with intraocular symptoms as the primary clinical manifestation. So suspicion should be very high especially in extremes of ages and/or unusual clinical presentations not correlating with systemic conditions. Extensive workup should be performed to identify primary malignancy. The purpose of treatment is to improve quality of life and prolong survival. Multidisciplinary team approach should be used to manage cancer patients who present with choroidal metastases. It might not only save the sight but also the life of the patient.

References:

- [1]. Bloch RS, Gartner S. The incidence of ocular metastatic carcinoma. Arch Ophthalmol. 1971 Jun;85(6):673-5. doi: 10.1001/archophth.1971.00990050675005. PMID: 5562786.
- [2]. Shields CL, Shields JA, Gross NE, Schwartz GP, Lally SE. Survey of 520 eyes with uveal metastases. Ophthalmology. 1997 Aug;104(8):1265-76. doi: 10.1016/s0161-6420(97)30148-1. PMID: 9261313.
- [3]. Qu Z, Liu J, Zhu L, Zhou Q. A Comprehensive Understanding of Choroidal Metastasis from Lung Cancer. Onco Targets Ther. 2021 Aug 12;14:4451-4465. doi: 10.2147/OTT.S315532. PMID: 34408441; PMCID: PMC8367201.
- [4]. Konstantinidis L, Damato B. Intraocular Metastases--A Review. Asia Pac J Ophthalmol (Phila). 2017 Mar-Apr;6(2):208-214. doi: 10.22608/APO.201712. PMID: 28399345.
- [5]. Singh N, Kulkarni P, Aggarwal AN, Mittal BR, Gupta N, Behera D, Gupta A. Choroidal metastasis as a presenting manifestation of lung cancer: a report of 3 cases and systematic review of the literature. Medicine (Baltimore). 2012 Jul;91(4):179-194. doi: 10.1097/MD.0b013e3182574a0b. PMID: 22732948.
- [6]. Mathis T, Jardel P, Loria O, Delaunay B, Nguyen AM, Lanza F, Mosci C, Caujolle JP, Kodjikian L, Thariat J. New concepts in the diagnosis and management of choroidal metastases. Prog Retin Eye Res. 2019 Jan;68:144-176. doi: 10.1016/j.preteyeres.2018.09.003. Epub 2018 Sep 19. PMID: 30240895.
- [7]. Fencia V, Abdolrahimzadeh S, Mannino G, Verrilli S, Balestrieri M, Recupero SM. Intravitreal bevacizumab in the successful management of choroidal metastases secondary to lung and breast cancer unresponsive to systemic therapy: a case series. Eye (Lond). 2014 Jul;28(7):888-91. doi: 10.1038/eye.2014.96. Epub 2014 Apr 25. PMID: 24763241; PMCID: PMC4094821.
- [8]. Camarillo Gómez C, Sánchez Ronco I, Encinas J. Metástasis coroideas [Choroidal metastases]. An Sist Sanit Navar. 2008;31 Suppl 3:127-34. Spanish. PMID: 19169300.

Dr.Monika Prajapati, et. al. "Ocular Metastasis: A Case Report." *IOSR Journal of Dental and Medical Sciences (IOSR-JDMS)*, 22(1), 2023, pp. 07-10.