

Correlation between the Clinical Degree of Cervical Spondylotic Myelopathy and the Diffusion Tensor Magnetic Resonance Imaging Parameters

Shaimaa Muhammad Ibrahim¹, Tarek Hassan Khalil², Tarek Hamed El Kamash³, Marwa Azab Mohamed⁴

1 Assistant lecturer of Radiology, Faculty of Medicine, Suez Canal University, Egypt.

2 Professor of Radiology, Faculty of Medicine, Suez Canal University, Egypt.

3 Professor of Radiology, Faculty of Medicine, Suez Canal University, Egypt.

4 Lecturer of Radiology, Faculty of Medicine, Suez Canal University, Egypt.

Abstract:

Objectives: to find the relation between the signal abnormalities on cervical spine MRI and the clinical manifestations of myelopathy in patients with cervical spondylosis.

Materials and Methods: our cross-sectional study included 50 patients with symptoms of cervical pain and radiculopathy, assessed by the JOA for the clinical degree of cervical cord myelopathy and 1.5T MRI conventional imaging & sagittal EPI-DTI.

Results: The FA value was significantly lower at cord compression/indentation level (0.44 ± 0.083) with $p < 0.001$, while ADC value was significantly higher at cervical cord indentation level (1.22 ± 0.14) with $p < 0.001$. FA value < 0.445 had a sensitivity of 94% and a specificity of 89% in diagnosing patients with myelopathy as significantly decreased FA than normal. ADC value > 1.23 had a sensitivity of 68% and a specificity of 75% in diagnosing patients with myelopathy. There is a statistically significant negative correlation between the JOA clinical score and the measured FA at the sites of spinal cord indentation ($r_s = 0.371$, $P = 0.008$). No significant correlation between the JOA score and the ADC value measured at the site of maximal spinal cord indentation/compression ($r_s = -0.254$, $P = 0.075$).

Conclusion: The clinical degree of cervical spinal cord myelopathy is significantly correlated to the decrease of the fractional anisotropy measured by diffusion tensor MRI suggesting the FA as a predictor of severity and a tool for early detection of myelopathy and cord affection.

Keywords: myelopathy, cervical, MRI, DTI, FA, ADC.

Date of Submission: 12-01-2023

Date of Acceptance: 28-01-2023

I. Introduction:

Cervical spondylotic myelopathy is a progressive disease and is the leading cause of spinal cord dysfunction worldwide & leads to major disability if left untreated (1). It represents a long-term complication of spinal cord compression by the degenerative changes in the cervical spine as discs and osteophytes. Abnormal MRI signal in the spinal cord usually suggests irreversible parenchymal changes, but their clinical significance has not been fully established, especially in cases of mild symptoms (2). The signal abnormalities are intramedullary hyperintense T2-weighted MRI signal that pathologically represent cystic degeneration of the gray matter (3). Presence of signal changes on T1WI as intramedullary hypointensity denotes cystic spinal cord degeneration and was associated with poor postoperative results (4).

More recent MRI techniques as diffusion weighted imaging (DWI) and diffusion tensor imaging (DTI) are investigated for their ability of the early detection of myelopathic cervical spinal cord changes, helping to take the right decision of either conservative and surgical management plans (5)(6)(7). The Diffusion parameters on MRI as fractional anisotropy (FA) and apparent diffusion coefficient (ADC) reflect microscopic nerve damages as demyelination or axonal damage (8)(9). The fractional anisotropy (FA) was found to decrease on diffusion tensor imaging (DTI) in the cervical spinal cord areas of myelopathy. Some studies correlated the changes in FA and ADC value with the clinical severity of myelopathy and suggested its value in detecting early myelo-

pathic changes before the appearance of T2 changes. (8)(10) This study was done to find the relation between the degree of myelopathy by imaging and the clinical degree of myelopathy in the cervical spinal cord.

II. Materials And Methods:

Study Design: a cross-sectional study

Study Location: at the MRI unit, Suez Canal University Hospital, Ismailia, Egypt.

Study Duration: patients presented to the MRI unit from 2019 to 2021.

Sample size: The study included 50 patients with cervical spondylosis and cervical radiculopathy. Patients had mean age range from 37 to 78 years old.

The inclusion criteria: presence of symptoms of cervical radiculopathy and cervical spondylotic changes on conventional MRI.

The exclusion criteria: the presence of MRI incompatible implanted devices, post-operative patients with spinal fixation.

For clinical assessment of the degree of myelopathy, we used the Japanese-orthopedic-association-score (JOA-Score) (11) as follows:

Motor function Upper extremity

Paralysis	1
Fine motor function massively decreased	2
Fine motor function decelerated	3
Discreet weakness in hands or proximal arm	4
Normal function	5

Motor function Lower extremity

Unable to walk	1
Need walking aid on flat floor	2
Need handrail on stairs	3
Able to walk without walking aid, but inadequate	4
Normal function	5

Sensory function

Upper extremity/lower extremity/trunk	
Apparent sensory loss	1
Minimal sensory loss	2
Normal function	3

Bladder function

Urinary retention	1
Severe dysfunction	2
Mild dysfunction	3
Normal function	4

Total score 0-17

The lower the score, the more severe the deficits. **Normal function:** 16 + 17, **Grade 1:** 12–15, **Grade 2:** 8–11, **Grade 3:** 0–7. Weight of each of the criteria in percentage of 17 points: upper extremity 23.5%; lower extremity 23.5%; sensory 3 · 11.8% (total: 35.4%); bladder and bowel function 17.6%

MRI examination was performed on 1.5 Tesla scanner using head and neck coil, with conventional T1WI and T2WI sagittal and axial images. Diffusion tensor imaging (DTI) of the cervical spinal cord, with specific acquisition parameters: sagittal image acquisition, echo-planar imaging (EPI), TR:2000, TE:90-100, b-value= 800 s/mm, FOV= 300, slice thickness= 3 mm, number of slices = 32 and scan time of about 2.5 min (10)(12)

Imaging analysis of conventional MRI was done by documenting spondylotic signs as disc protrusion/herniation, osteophytes, spinal canal stenosis, spinal cord indentation or compression and T2WI spinal cord hyperintensity. Diffusion tensor imaging quantitative analysis was done by measuring FA & ADC values, regions of interest (ROIs) were selected manually at sites of spinal cord indentation & comparing it with normal non-compressed cord sites above the affected levels (C2) with care to avoid ROI contamination with the surrounding CSF(7).

Statistical analysis:

In the statistical analysis of data, we used statistical package SPSS (statistical package for social sciences) IBM® SPSS® Statistics 25 for windows. The results of DTI were correlated with the clinical data and conventional MRI findings.

The validity of diffusion parameters and the cut-off points for diagnosis of myelopathy was assessed by the area under the receiver operating characteristic (ROC) curve. We performed correlation statistics using the Spearman correlation coefficient. Significant P value was considered at a level of < 0.05 and we kept the level of confidence at 95%.

III. Results:

Clinical examination of the patients found that the minimum JOA score of the studied patients was 11 (indicating Grade 2 clinical myelopathy) and the maximum JOA score was 17 (denoting no clinical myelopathy). 26 (52%) of our patients had grade 1 myelopathy and only 2 patients (4%) showed Grade 2 clinical myelopathy, but 22 (44%) of patients showed no definite clinical manifestations of myelopathy.

No cases of total motor disability exist in the studied patients. Only two patients had mild sphincteric disorders & all other patients had normal sphincteric function. All patients complained of chronic cervical pain. 42% of patients had bilateral brachialgia, 30% had left sided brachialgia and 28% of patients had right brachialgia.

Examination of conventional MRI images revealed that: disc protrusion direction was found to be left posterolateral in 12 (24%), posterior central in 27 (54%) and right posterolateral in 11 (22%). By T2WI spinal cord showed hyperintensity in 5 (10%) of patients. There were osteophytes compressing cord in 20 (40%) of patients, spinal canal stenosis in 7 (14%) of patients, and spinal cord indentation/compression in 33 (66%).

The FA value was significantly lower at cord compression/indentation level (0.44±0.083) with p<0.001, while ADC value was significantly higher at cervical cord compression/indentation level (1.22±0.14) with p<0.001.

Table 1: FA and ADC values measured on DTI

	Normal level (C2)	At cord indentation level	Below cord indentation level	P-value
FA				
Mean ±SD	0.62±0.085	0.44±0.083	0.58±0.068	<0.001*
Median (Range)	0.60 (0.45-0.75)	0.43 (0.12-0.64)	0.58 (0.43-0.70)	
ADC				
Mean ±SD	1.03±0.09	1.22±0.14	1.04±0.09	<0.001*
Median (Range)	1.0(0.9-1.23)	1.23(0.92-1.46)	1.01 (0.9-1.4)	

Quantitative data is presented as mean ±SD. Repeated measurement ANOVA test is used.

*Statistically significant as p<0.05.

About 64.5% of patients who showed no T2WI spinal cord hyperintensity opposite the affected disc levels had myelopathy by DTI (defined as significantly decreased FA value from the normal level at C2) and 35.5% had no myelopathy (no significant FA value difference from the normal level at C2).

ROC curve of the FA values showed that FA value ≤ 0.445 had a sensitivity of 94% and a specificity of 89% in diagnosing patients with myelopathy as significantly decreased FA than normal. ROC curve of the ADC values showed that ADC value ≥ 1.23 had a sensitivity of 68% and a specificity of 75% in diagnosing patients with myelopathy.

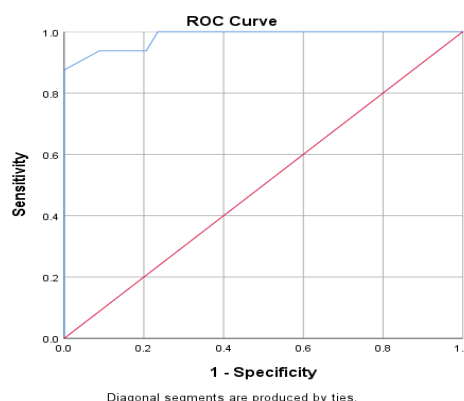


Figure 1: ROC curve of FA for detecting cases of myelopathy. FA value less than or equal 0.445 had sensitivity of 94% and specificity of 89% in diagnosing patients with myelopathy.

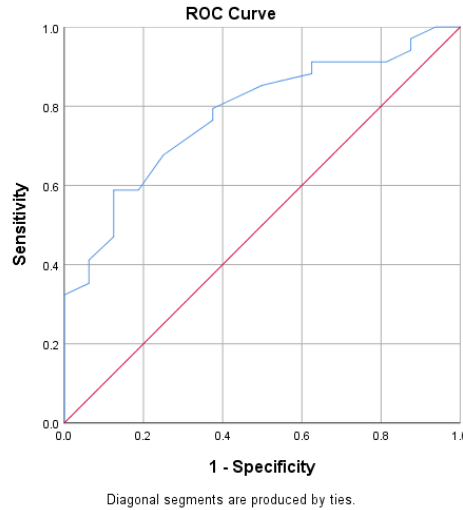


Figure 2: ROC curve of ADC for detecting cases of myelopathy. ADC value ≥ 1.23 had sensitivity of 68% and specificity of 75% in diagnosing patients with myelopathy.

We found a statistically significant linear correlation between the JOA clinical score and the measured FA at the sites of spinal cord indentation/compression ($r_s=0.371$, $P= 0.008$)(**Figure 3**). There was no statistically significant correlation between the JOA score and the ADC value measured at the site of maximal spinal cord indentation/compression ($r_s= -0.254$, $P= 0.075$). There was no statistically significant relation between the diagnosis of myelopathy by DTI (decreased FA at site of cord indentation than the FA at C2 normal cord level) and the JOA clinical score.

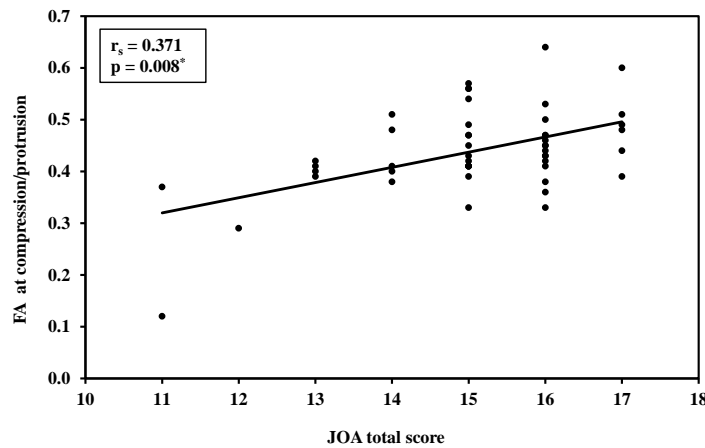


Figure 3:Correlation between JOA score and FA at the sites of cervical cord compression/disc protrusion

Table 2:Relation between the presence of myelopathy by DTI and the JOA clinical score

JOA score	Myelopathy by DTI		U	p
	No (n= 16)	Yes (n= 34)		
Mean \pm SD.	15.7 \pm 1.1	14.8 \pm 1.5	190.0	0.077
Median (Min. – Max.)	15.5 (14.0 – 17.0)	15.0 (11.0 – 17.0)		

SD: Standard deviation

U: Mann Whitney test

χ^2 : Chi square test

MC: Monte Carlo

p: p value for comparing between the two studied groups

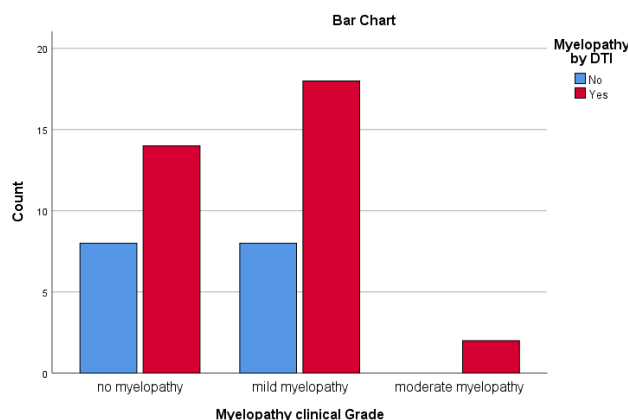


Figure4:Relation between the presence of myelopathy by DTI and the JOA clinical score

IV. Discussion:

DTI can reflect microstructural changes in the spinal cord through changes in the direction of diffusion of water molecules. The chronic course of spondylotic myelopathy is associated with demyelination and axonal damage involving both the point of myelopathy and areas of the cord below it (13). Diffusion weighted imaging (DWI) and diffusion tensor imaging (DTI) are studied as advanced MRI techniques to test their ability for early detection of myelopathic cervical spinal cord changes in cases of cervical spondylosis, to support decision making about conservative and surgical management options (5)(7).

We found a statistically significant linear correlation between the JOA clinical score and the measured FA at the sites of spinal cord indentation/compression ($r_s=0.371$, $P=0.008$). Other studies showed a significant linear correlation between FA measurements at the site of compression and JOA score (Pearson, $R^2=0.4144$, $p=.0001$; Power=93%). Also, they found that the FA at the site of compression can be significantly used for patients classification according the severity of myelopathy (ANOVA, $p=.0001$)(14).

DTI analyzes the subtle structural spinal cord changes in patients with cervical spondylotic myelopathy, and can evaluate the severity of the preoperative patient's condition(15).

In the study of Wen et al., FA values of patients with cervical spondylotic myelopathy were significantly $<$ FA at normal C2 cord level ($P=.003$), while by conventional MRI, the compression ratio of the myelopathic spinal cord ($P=.479$) was not associated with the clinical severity of myelopathy evaluated by using the JOA score(8). Similarly, in our study, we found that The FA value was significantly lower below compression level with $p<0.001$, compared to the normal cord FA values measured at C2 levels in all patients. The higher the clinical grade of cervical spondylotic myelopathy, the lower the FA values (significant negative correlation). This is shown in our study ($r_s=0.371$, $P=0.008$) and in other previous studies, which found that the FA values at the maximal compression point were significantly correlated with the sum of the JOA score ($r_2=0.327$, $P=.016$)(8).

In conventional MRI, we found that, by T2WI sagittal imaging, spinal cord showed hyperintensity in 5 (10%) of patients. Other studies measured the compression ratio of the spinal cord at the sites of myelopathy ($P=.479$) and it was not associated with the JOA score of the clinical severity of myelopathy, while the ROC curves show that FA values help to precisely predict the prognosis than the JOA score(8).

In our study, the FA value was significantly lower at the cord indentation levels in the patients who showed T2WI spinal cord hyperintensity (0.34 ± 0.12) with $p=0.003$, while ADC value was significantly higher at cord compression level in patients with high T2WI spinal cord signal (1.34 ± 0.035), $p=0.007$. We also found that fractional anisotropy is significantly abnormal in 64.5% of patients with no spinal cord T2WI signal abnormalities, suggesting that FA can detect early myelopathic changes in 58% of our study patients. Analysis of the ROC curves of the FA and ADC values showed that FA value ≤ 0.445 had 94% sensitivity and 89% specificity in the diagnosis of cervical myelopathy as significantly decreased FA than normal C2 cord level, while ADC value ≥ 1.23 showed 68% sensitivity and 75% specificity in diagnosing the same patients with myelopathy.

V. Conclusion:

The clinical degree of cervical spinal cord myelopathy is significantly correlated to the decrease of the fractional anisotropy measured by diffusion tensor MRI suggesting the FA as a predictor of severity of myelopathy and spinal cord neurological damage. Also, it can detect cord myelopathic changes earlier than conventional MRI.

References:

- [1]. Fehlings MG, Tetreault LA, Wilson JR, Skelly AC. Cervical Spondylotic Myelopathy: Current State of the Art and Future Directions. *Spine*. 2013;38(22S).
- [2]. Koyanagi I. Options of Management of the Patient with Mild Degenerative Cervical Myelopathy. *Neurosurg Clin N Am*. 2018;29(1):139-44.
- [3]. Wada E, Ohmura M, Yonenobu K. Intramedullary changes of the spinal cord in cervical spondylotic myelopathy. *Spine*. 1995;20(20):2226-32.
- [4]. Yagi M, Ninomiya K, Kihara M, Horiuchi Y. Long-term surgical outcome and risk factors in patients with cervical myelopathy and a change in signal intensity of intramedullary spinal cord on magnetic resonance imaging: Clinical article *Journal of Neurosurgery: Spine SPI*. 2010;12(1):59-65.
- [5]. Song T, Chen WJ, Yang B, Zhao HP, Huang JW, Cai MJ, et al. Diffusion tensor imaging in the cervical spinal cord. *European Spine Journal*. 2011;20(3):422-8.
- [6]. Kara B CA, Karadereler S, Ulusoy L, Ganiyusufoglu K, Onat L, Mutlu A, Ornek I, Sirvanci M, Hamzaoglu A. The role of DTI in early detection of cervical spondylotic myelopathy: a preliminary study with 3-T MRI. *Neuroradiology*. 2011 Aug;53(8):609-16.
- [7]. Lee JW, Kim JH, Park JB, Park KW, Yeom JS, Lee GY, et al. Diffusion tensor imaging and fiber tractography in cervical compressive myelopathy: preliminary results. *Skeletal Radiol*. 2011;40(12):1543-51.
- [8]. Wen CY, Cui JL, Liu HS, Mak KC, Cheung WY, Luk KDK, et al. Is Diffusion Anisotropy a Biomarker for Disease Severity and Surgical Prognosis of Cervical Spondylotic Myelopathy? 2014:197-204.
- [9]. Van Hecke W, Emsell L. Introduction to Diffusion Tensor Imaging In: Van Hecke W, Emsell L, Sunaert S, editors. *Diffusion Tensor Imaging: A Practical Handbook*. New York, NY: Springer New York; 2016. p. 7-23.
- [10]. Nukala M, Abraham J, Khandige G, Shetty BK, Rao APA. Efficacy of diffusion tensor imaging in identification of degenerative cervical spondylotic myelopathy. *Eur J Radiol Open*. 2019;6:16-23.
- [11]. Vitzthum H-E, Dalitz K. Analysis of five specific scores for cervical spondylogenic myelopathy. *European spine journal : official publication of the European Spine Society*. 2007;16(12):2096-103.
- [12]. Quantitative Evaluation of the Diffusion Tensor Imaging Matrix Parameters and the Subsequent Correlation with the Clinical Assessment of Disease Severity in Cervical Spondylotic Myelopathy [Internet]. 2020.
- [13]. d'Avanzo S, Ciavarro M, Pavone L, Pasqua G, Ricciardi F, Bartolo M, et al. The Functional Relevance of Diffusion Tensor Imaging in Patients with Degenerative Cervical Myelopathy. *Journal of Clinical Medicine* 2020;9(6):1828.
- [14]. Ellingson BM, Salamon N, Grinstead JW, Holly LT. Diffusion tensor imaging predicts functional impairment in mild-to-moderate cervical spondylotic myelopathy. *Spine J*. 2014;14(11):2589-97.
- [15]. Tian X, Zhang L, Zhang X, Meng L, Li X. Correlations between preoperative diffusion tensor imaging and surgical outcome in patients with cervical spondylotic myelopathy. *American journal of translational research*. 2021;13(10):11461-71.

Shaimaa Muhammad Ibrahim, et. al. "Correlation between the Clinical Degree of Cervical Spondylotic Myelopathy and the Diffusion Tensor Magnetic Resonance Imaging Parameters." *IOSR Journal of Dental and Medical Sciences (IOSR-JDMS)*, 22(1), 2023, pp. 29-34.