

## Non-alcoholic Wernicke's encephalopathy-a case series

Dr. Dilip Roy, Prof.Sandip Pal, Dr.Snighdendu Pal, Dr.Moukoli Pal;

Medical college & hospital, Kolkata

---

**Abstract:** Wernicke encephalopathy (WE) is a neurological emergency due to thiamine deficiency .Almost half of all WE cases occur in non-alcoholics. Prompt diagnosis and thiamine replacement influence prognosis .Here, we present three cases of non-alcoholic WE of which two are due to intestinal surgery and one is due to hyperemesis gravidarum.

---

Date of Submission: 08-09-2022

Date of Acceptance: 25-09-2022

---

### I. Background:

Wernicke's encephalopathy (WE) is an often un-recognized disease of thiamine deficiency.It's a medical emergency and it can lead to severe neurological morbidity and even death if not treated early. Although WE usually results from chronic alcoholism, non-alcoholic causes such as gastrointestinal tract surgery, hyperemesis gravidarum ,AIDS, chronic malnutrition, prolonged parenteral nutrition, and rarely in malignancy are reported in nearly 50% of cases. It is often under-diagnosed because clinicians may be less likely to recognize this condition in non-alcoholic patients; hence we present this case series.

### II. Case presentation:

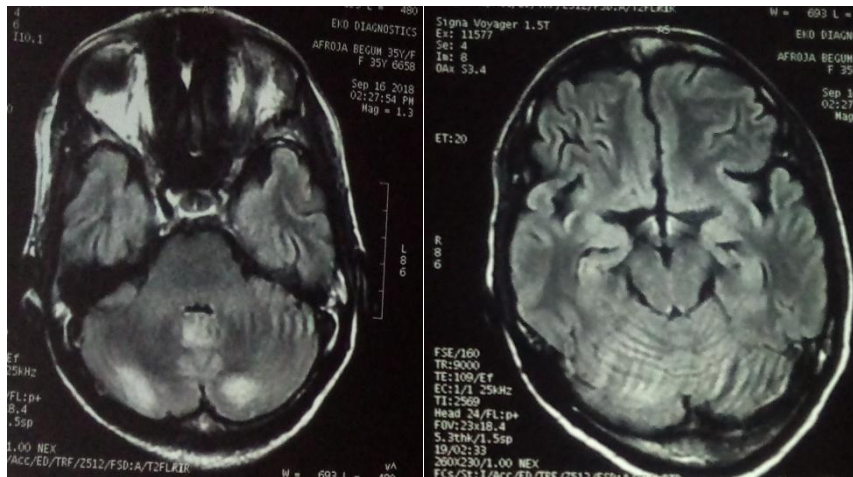
**Case 1.** A 35 years old female patient presented to us with history of ataxia and speech problem after repeated episodes of vomiting for 3-4 days. She had a history of RTA with lacerated wound in intestine 9 months ago and she undergone small intestinal surgery with ileostomy .Examination revealed pan-cerebellar involvement with high amplitude gaze changing nystagmus. Clinically thiamine deficiency was suspected which supported by MRI imaging with involvement of bilateral cerebellum, mammillary bodies and thalamus.She was treated with high dose intravenous thiamine and other supportive measures with significant improvement of ataxia on follow up.

**Case 2.** A 25 years malnourished pregnant lady with history of hyperemesis gravidarum presented with subacute onset altered sensorium for last 2 days. Examination revealed altered sensorium in the form of drowsiness with gaze evoked nystagmus and ophthalmoplegia. She was clinically suspected as WE which was supported by MRI brain with hyperintensities in bilateral medial thalamus, mammillary bodies and periaqueductal grey matter. She was treated with high dose intravenous thiamine with significant improvement in sensorium and ophthalmoplegia.

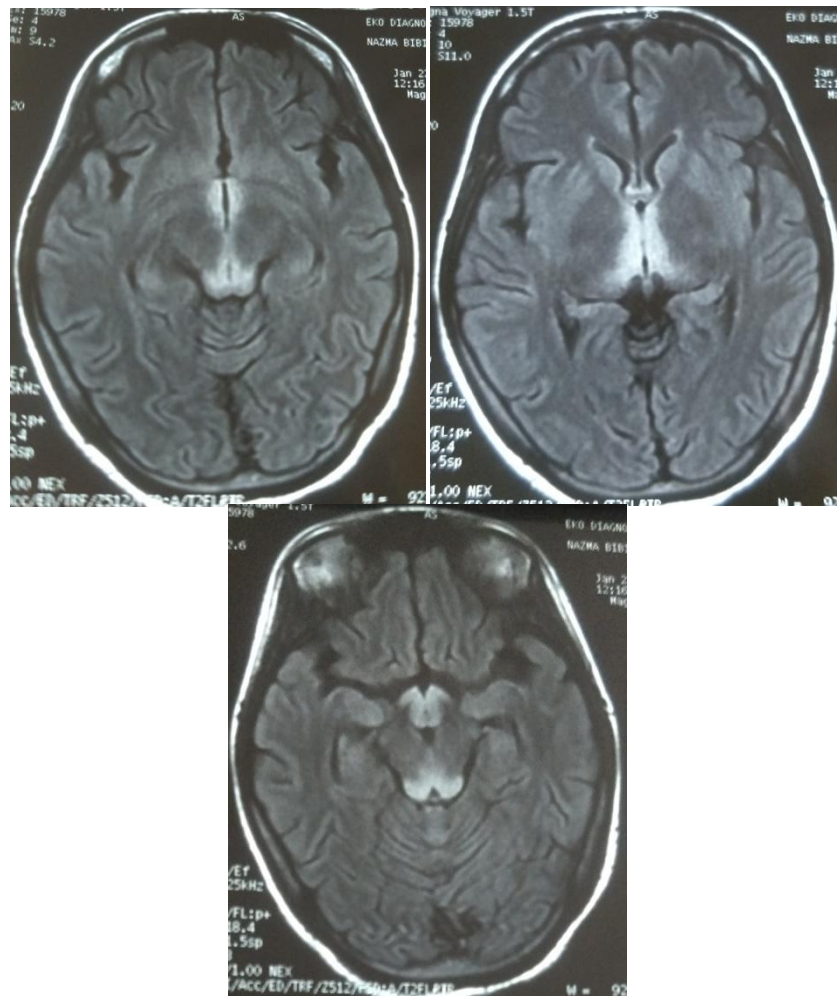
**Case 3.** This 48 years male patient admitted in surgical ward for non-healing intestinal ulcer. He was undergone proximal colectomy with ilio-colon anastomosis. Post-operatively he progressively developed ataxia and subsequently became drowsy. He also developed operative complication in the form of enterocutaneous fistula. At this juncture, he was referred to us. Examination revealed gaze evoked nystagmus with ophthalmoplegia and drowsiness with irrelevant talking. He was suspected as a case of WE and treated with high dose intravenous thiamine without delay. His brain imaging showed hyperintensities in bilateral medial thalamus and mammillary bodies. With treatment his sensorium and ophthalmological finding improved but ataxia was persistent.

**Imaging:**

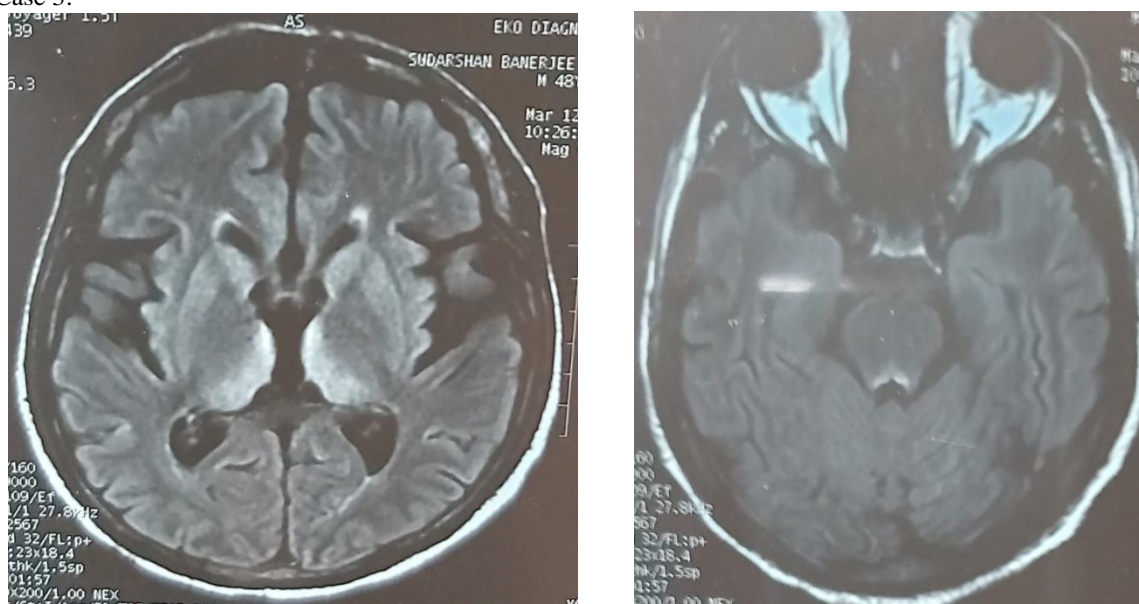
Case 1:



Case 2:



Case 3:



### III. Discussion :

Thiamine deficiency mainly seen in chronic alcoholic with malnutrition. Precipitating factors such as prolonged vomiting may leads to Wernicke's encephalopathy in this patient. But non-alcoholic individual can also developed Wernicke's encephalopathy in certain situation like hyperemesis gravidarum, chronic malnutrition and in extensive intestinal surgery which hinder thiamine absorption. In our case series, we saw two patients with extensive intestinal surgery and one patient with hyper-emesis gravidarum. Wernicke's encephalopathy is clinical diagnosis and should be suspected in patient with precipitating factors and typical ocular finding and ataxia. Early diagnosis and high dose thiamine supplementation can reverse all clinical finding as in our two cases. Delay in diagnosis and subsequent delay thiamine supplementation can leads to permanent disability as in our 3<sup>rd</sup> case where ataxia did not improve.

#### Learning point:

1. Wernicke's encephalopathy should be suspected in patient with typical ocular finding and ataxia with precipitating factors.
2. Early diagnosis and thiamine supplementation can prevent permanent disability.

#### Foot notes:

- a. competing interest-none
- b. patient consent-obtain

#### Reference:

- [1]. Fei G, Zhong C, Jin L, Wang J, Zhang Y, Zheng X, et al. Clinical characteristics and MR imaging features of nonalcoholic Wernicke encephalopathy. *Am J Neuroradiol* 2008;29:164-9
- [2]. Zuccoli G, Gallucci M, Capellades J, Regnicolo L, Tumiatì B, Giadàs TC, et al. Wernicke encephalopathy: MR findings at clinical presentation in twenty-six alcoholic and nonalcoholic patients. *Am J Neuroradiol* 2007;28:1328-31
- [3]. Foster D, Falah M, Kadom N, Mandler R. Wernicke encephalopathy after bariatric surgery: losing more than just weight. *Neurology* 2005;65:1987.
- [4]. Zuccoli G, Cruz DS, Bertolini M, Rovira A, Gallucci M, Carollo C, et al. MR imaging findings in 56 patients with Wernicke encephalopathy: nonalcoholics may differ from alcoholics. *Am J Neuroradiol* 2008:1-6
- [5]. Coe M, Carfagnini F, Tani G, Ambrosetto P. Wernicke's encephalopathy in a child: case report and MR findings. *Pediatr Radiol* 2001;31:167-8

Dr. Dilip Roy, et. al. "Non-alcoholic Wernicke's encephalopathy-a case series." *IOSR Journal of Dental and Medical Sciences (IOSR-JDMS)*, 21(09), 2022, pp. 21-23.