

Endodontic Management of Mandibular First Molar with Endodontic-Periodontal lesion: A case report

Raeesa Shafiqa¹, Widi Prasetya²

¹Postgraduate Program in Conservative Dentistry, Faculty of Dentistry, Universitas Sumatera Utara, Medan 20155

²Lecturer, Department of Conservative Dentistry, Faculty of Dentistry, Universitas Sumatera Utara, Medan 20155

Email: raeesashafiqa@gmail.com, widi.drg@gmail.com

Abstract

Introduction : Some endodontic diseases may have manifestations that affect the periodontal tissues. Communication between the pulp and the periodontal ligament may occur via the apical foramen and lateral and accessory canals in the apical and coronal parts of the root. **Case Report :** The patient presented with the complaint of slight pain, little discomfort, and swelling over the tooth #46. External examination of the face and palpation did not show any significant abnormality. There was a deep caries in the right mandibular first molar (tooth #46), no response on the pulp vitality test, and pain upon percussion. Furthermore, there was slight gingival congestion and swelling at the buccal area of tooth #46 with exudate extrusion upon the application of pressure. The periodontal examination showed a pocket of 6 mm depth in the mesiolingual (ML) aspect of tooth, with a grade I tooth mobility. The intraoral examination also reveals a fair oral hygiene status with no signs of trauma or malocclusion. Periapical radiograph revealed a deep carious lesion in the distal surface of the tooth, there is presence of a radiolucency in the furcation region, connected with the apical lesions present in mesial root. A final pupal diagnosis of pulp necrosis and chronic apical abscess of tooth #46 was made and the patient was counseled for root canal treatment. **Discussion :** The diagnosis of endodontic-periodontal lesions should be based on a combination of history taking from the patient, clinical evaluation, and radiographic examination. Difficult canal anatomy could be one of the causes of improper cleansing of the canal system, with the permanence of microorganisms. Irrigation of the root canals plays an important role in the disinfection process. From a microbiological standpoint, an irrigant should be able to demonstrate antimicrobial and antibiofilm activities and inactive endotoxins. Activation of the irrigant helps to improve root canal cleanliness and the application of intracanal medication was recommended. Then the tooth should be reviewed clinically and radiographically after 6–12 months in order to determine whether adequate periapical healing has continued. **Conclusion :** Endodontic and periodontal diseases can provide many challenges to clinicians. Establishing a correct diagnosis, is the most important phase of the management as the diagnosis will determine the type and sequence of treatment required. In general, if the root canal system is infected, endodontic treatment should be commenced prior to any periodontal therapy in order to remove the intracanal infection. Proper cleaning and the use of non-toxic intracanal therapeutic medicaments is essential to destroy bacteria and to encourage tissue healing.

Keyword: Endo-perio lesion, Primary endodontic lesion, Root canal treatment, Chronic apical abscess

Date of Submission: 18-08-2022

Date of Acceptance: 02-09-2022

I. Introduction

Some endodontic diseases may have manifestations that affect the periodontal tissues. Communication between the pulp and the periodontal ligament may occur via the apical foramen and lateral and accessory canals in the apical and coronal parts of the root. Accessory canals result due to a localized failure in the formation of Hertwig's sheath during the embryonic stages of tooth formation. This defect is probably due to the persistence of abnormally placed blood vessels reaching the pulp, which is more common in the furcation region.¹

Although there are many factors that contribute to the development and progression of endodontic and periodontal diseases, the primary cause of both diseases is the presence of bacterial infections with complex microbial flora. Many authors have reported the similarity of the bacterial flora associated with endodontic and periodontal infections.²⁻⁶ Based on the underlying pathological origin, an endodontic-periodontal lesion can be

classified as a primary endodontic lesion, a primary periodontal lesion, a primary endodontic lesion with secondary periodontal involvement, a primary periodontal lesion with secondary endodontic involvement, or combined lesions.⁷

Once both the pulp and the periodontal tissues have involved, the diagnosis and management may become more complex and will require extra considerations. It is important to achieve an optimal diagnosis based on the history, clinical and radiographic examination to ensure the treatment success of such lesions. In this case report, we described the diagnosis and treatment planning for the management of an endodontic-periodontal lesion of endodontic origin.

II. Case Report

A 14-year-old female patient with with no medical history presented to the conservative department faculty of dentistry, Universitas Sumatera Utara. The patient presented with the complaint of slight pain, little discomfort, and swelling over the tooth #46. External examination of the face and palpation for lymphadenopathy did not show any significant abnormality. However, a deep caries in the right mandibular first molar (tooth #46) was detected upon the intraoral examination. There was no response on the pulp vitality test, but the patient complained of obvious pain upon percussion. Furthermore, there was slight gingival congestion and swelling at the buccal area of tooth #46 with exudate extrusion upon the application of pressure. The periodontal examination showed a pocket of 6 mm depth in the mesiolingual (ML) aspect of tooth #46, with a grade I tooth mobility. The intraoral examination also reveals a fair oral hygiene status with no signs of trauma or malocclusion. Periapical radiograph revealed a deep carious lesion in the distal surface of the tooth, there is presence of a radiolucency in the furcation region, connected with the apical lesions present in mesial root. No endodontic treatment had been previously performed (Figure 1). The pulp chamber floor examination revealed no furcation, perforation, or fracture.

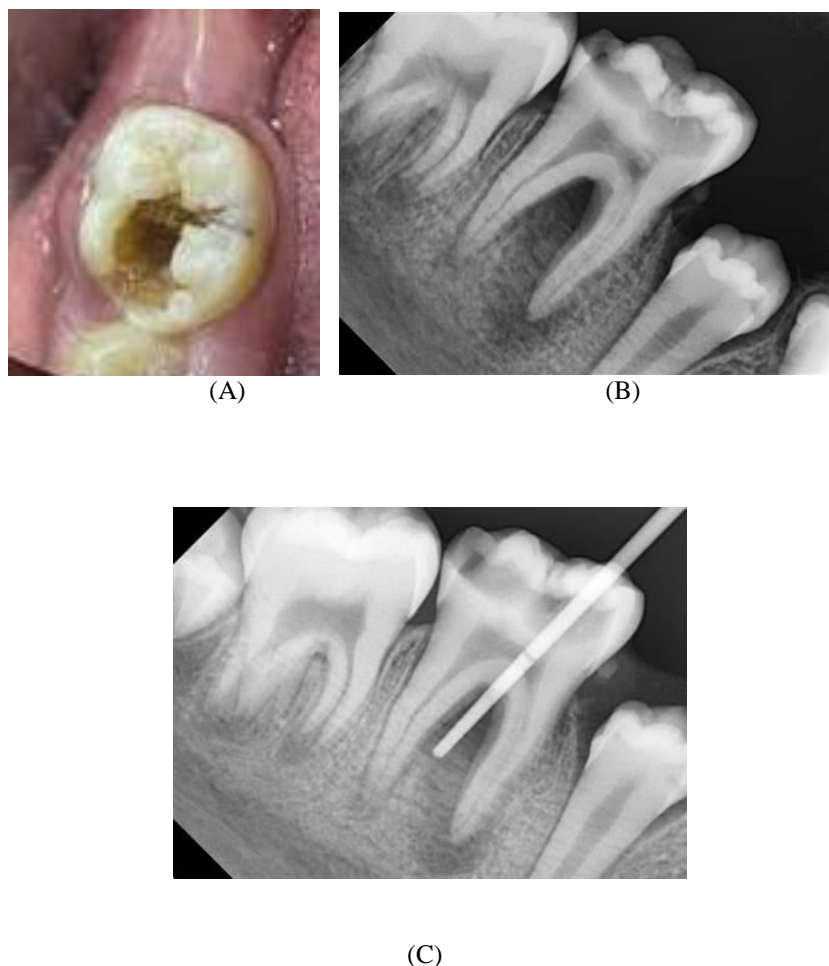


Figure 1: A. Clinical photograph of tooth #46. B. Periapical radiograph : furcation bone and apical bone destruction in mesial root. C. Sinus tract was traced with gutta percha

Based on the clinical and radiograph examination, a final pupal diagnosis of pulp necrosis and chronic apical abscess of tooth #46 was made, while the periodontal status was apical, bifurcation and lingual bone resorption at the #46 tooth area associated with 6 mm mesiolingual depth pocket. The case was classified according to endodontic-periodontal lesions classification, as a primary endodontic lesion. The patient was counseled for root canal treatment.

The following treatment strategy was applied. Root canal was instrumented with Protaper Gold (Dentsply Maillefer, Ballaigues, Switzerland), Irrigation protocol included the following: 3% NaOCl, 19% EDTA with the EndoActivator System (Dentsply Tulsa Dental Specialties, Tulsa, OK, USA). The first appointment was finished placing a calcium hydroxide-based medication on the working length (Ultra- Cal XS paste; Ultradent Products, Inc., South Jordan, UT, USA). The floor of the pulp was covered with polytetrafluoroethylene (PTFE) and retained with the thin cavit (Cavit G, 3M ESPE, Saint Paul, MN, USA) for the better sealing and retention the outer part of the cavity was restored with intermediate restorative material (IRM) according to the double seal technique.

After two weeks, the medication was removed with the instrumentation and irrigation with 3% NaOCl. As the patient was asymptomatic, the canals were dried and filled. The obturation was performed using continuous wave technique with gutta-percha and AH Plus (Dentsply International Inc., York, PA, USA) (Figure 2).

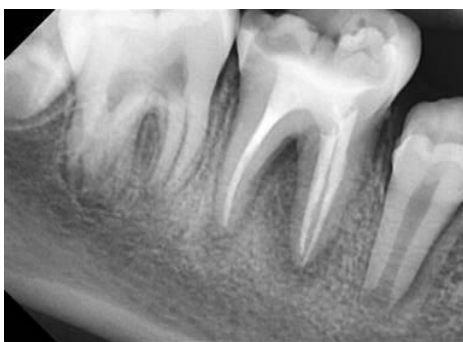

Figure 2. Apical radiograph of tooth # 46 after obturation.

After obturation, the patient was referred to the restorative treatment. The tooth was restored with a onlay composite restoration. The patient was recalled after 1 weeks, 1 and 3 months, periapical and furcation healing was observed (Figure 3).

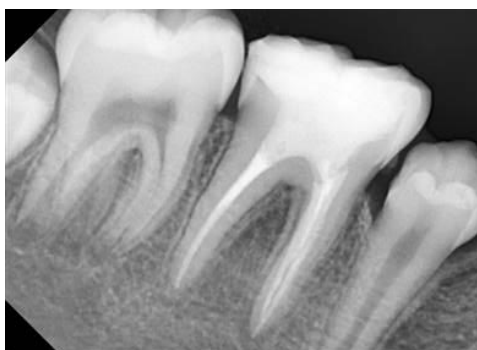

Figure 3. 3 months follow-up visit. Healing was observed in the furcation and the periapical areas of tooth # 46.

III. Discussion

The endodontic-periodontal lesion is a complicated disease entity that can be challenging for clinicians to diagnose and treat. The lesion might be difficult to diagnose. Endodontic diseases may have manifestations that affect the periodontal tissues. In particular, a chronic apical abscess may appear to be associated with a periodontal pocket. A chronic apical abscess is defined as a localized collection of pus with a draining sinus –

the abscess is located in the periapical region of a tooth and is typically a result of an infected root canal system. The draining sinus may exit the mucosa in any location, either close to or at some distance from the abscess. In some cases, the draining sinus may be located immediately adjacent to, or alongside, the gingival sulcus and this can have the appearance of a deep, narrow periodontal pocket. The furcation region of multi-rooted teeth may have a radiolucency, if there are accessory canals draining into the furcation. The root canal infection may be in one or more canals and may occur in teeth that have pulpless and infected root canal systems, if ever, will cause periodontal or osseous defects. Chronic apical abscesses have little or no discomfort unless an acute exacerbation occurs such as when the draining sinus closes but pus is still being produced and is trapped deep within the tissues. The diagnosis of these cases should be based on the status of both the root canal system and the periodontal tissues (e.g., a pulpless, infected root canal system with a chronic apical abscess as a result of caries).⁸

In the management of endodontic-periodontal disease, proper diagnosis is critical to ensure treatment success and favorable long-term prognosis. Accurate classification of the lesion is the first step in helping the clinicians to design the most appropriate treatment strategy. The diagnosis of endodontic-periodontal lesions should be based on a combination of history taking from the patient, clinical evaluation, and radiographic examination. In addition, special tests such as vitality tests, percussion, mobility, and periodontal probing. These are essential diagnostic tests aimed at differentiating between pulpal and periodontal diseases. For this patient, the presence of deep caries and the absence vitality of the affected tooth suggested an endodontic involvement. Periodontal examination of tooth #46 displayed a narrow pocket of 6 mm depth mesiolingually. This pocket acted as a sinus tract for the drainage of the pulp exudates. Otherwise, the periodontal examination did not show any other significant abnormality. There was also no premature contact of the occlusal surface with the infected tooth, thus indicating that the lesion was of an endodontic origin. Such lesions usually have a better prognosis following the root canal treatment. Furthermore, a previous study reported that the sinus tract extending through the gingival sulcus or the furcation area might disappear in the early stage after disinfection, shaping, and obturation of the root canals.⁹

Successful endodontic treatment depends on the thorough debridement of the entire root canal system. Difficult canal anatomy could be one of the causes of improper cleansing of the canal system, with the permanence of microorganisms.^{10, 11} Irrigation of the root canals plays an important role in the disinfection process. From a microbiological standpoint, an irrigant should be able to demonstrate antimicrobial and antibiofilm activities and inactive endotoxins.¹² Activation of the irrigant helps to improve root canal cleanliness.^{13,14} Al-Jadaa et al. demonstrated that ultrasonic irrigation causes a rise in the irrigant temperature in the accessory canals to $53.5 \pm 2.7^{\circ}\text{C}$ after the fifth minute, which could improve the irrigation effectiveness,¹⁵ activation of the irrigants also promotes the irrigation penetration into accessory canals, and consequently a greater cleaning of the root canals. During the treatment for a lesion with an endodontic origin, the application of intracanal non-setting calcium hydroxide medication was recommended. Calcium hydroxide has good antibacterial activity, and biocompatibility and its application after the root canal procedure could inactivate any exotoxins by hindering the increase in cytokine chemical inflammatory mediators.¹⁶ It could also inhibit any post-penetration preapical inflammation, in this patient the root canal preparation was done with irrigation of sodium hypochlorite and EDTA, followed by a non-setting calcium hydroxide temporization.

Conventional endodontic treatment of an infected root canal system with a chronic apical abscess draining alongside or through the periodontal ligament should lead to healing of the apical abscess. If the draining sinus masquerading as a periodontal pocket does not heal, then periapical surgery is usually indicated so the apical abscess can be curetted. After the root canal filling has been completed, the tooth should be restored with a suitable restoration and scheduled for review. In this patient, healing was observed in the furcation and the periapical areas of tooth after 3 months. Then every tooth that has undergone endodontic treatment should be reviewed clinically and radiographically after 6–12 months in order to determine whether adequate periapical healing has continued. If periapical healing is evident and the periodontal situation is stable, then further clinical and radiographic reviews should be conducted every 3–4 years to monitor the tooth, its periodontium and its restoration. As both endodontic and periodontal infections can recur, it is essential to review and maintain the area so that early signs of breakdown can be treated before irreversible damage occurs or before the required treatment becomes further complicated.⁸

IV. Conclusion

Endodontic and periodontal diseases can provide many challenges to clinicians. Although there may be difficulties in establishing a correct diagnosis, this is the most important phase of their management as the diagnosis will determine the type and sequence of treatment required. In general, if the root canal system is infected, endodontic treatment should be commenced prior to any periodontal therapy in order to remove the intracanal infection. Proper cleaning and the use of non-toxic intracanal therapeutic medicaments is essential to destroy bacteria and to encourage tissue healing.

References :

- [1]. P. Poornima and V. V. Subba Reddy, "Comparison of digital radiography, decalcification, and histologic sectioning in the detection of accessory canals in furcation areas of human primary molars," *Journal of the Indian Society of Pedodontics and Preventive Dentistry*, vol. 26, no. 2, pp. 49–52, 2008.
- [2]. Trope M, Tronstad L, Rosenberg ES, Listgarten M. Darkfield microscopy as a diagnostic aid in differentiating exudates from endodontic and periodontal abscesses. *J Endod* 1988;14:35–38.
- [3]. Kobayashi T, Hayashi A, Yoshikawa R, Okuda A, Hara K. The microbial flora from root canals and periodontal pockets of non-vital teeth with advanced periodontitis. *Int Endod J* 1990;23:100–106.
- [4]. Trope M, Rosenberg E, Tronstad L. Darkfield microscopic spirochaete count in the differentiation of endodontic and periodontal abscesses. *J Endod* 1992;18:82–86.
- [5]. Sundqvist G. Associations between microbial species in dental root canal infections. *Oral Microbiol Immunol* 1992;7:257–262.
- [6]. Kurihara H, Kobayashi Y, Francisco LA, Isoshima O, Nagai A, Murayama Y. A microbiological and immunological study of endodontic-periodontic lesions. *J Endod* 1995;21:617–621.
- [7]. Alshawwa H, Wang JF, Liu M, Sun SF. Successful management of a tooth with endodontic-periodontal lesion: A case report. *World J Clin Cases* 2020; 8(20): 5049-5056
- [8]. PV Abbott, J Castro. Strategies for the endodontic management of concurrent endodontic and periodontal diseases. *Australian Dental Journal* 2009; 54:(1 Suppl): S70–S85
- [9]. Rotstein I, Simon JH. The endo-perio lesion: a critical appraisal of the disease condition. *Endod Top* 2006; 13: 34-56 [DOI: 10.1111/j.1601-1546.2006.00211.x]
- [10]. S.Gautam,S.R.Galgali,H.S.Sheethal,andN.S.Priya,"Pulpal changes associated with advanced periodontal disease: a histopathological study," *Journal of Oral and Maxillofacial Pathology*, vol. 21, no. 1, pp. 58–63, 2017.
- [11]. E. M. Weinberg, A. E. Pereda, S. Khurana, P. P. Lotlikar, C. Falcon, and C. Hirschberg, "Incidence of middle mesial canals based on distance between mesial canal orifices in mandibular molars: a clinical and cone-beam computed tomographic analysis," *Journal of Endodontia*, vol. 46, no. 1, pp. 40–43, 2020.
- [12]. P. R. Sheno, E. S. Morey, C. S. Makade, M. K. Gunwal, R. T. Khode, and S. S. Wanmali, "In vitro evaluation of the antimicrobial efficacy of chitosan and other endodontic irrigants against *Enterococcus faecalis*," *General Dentistry*, vol. 64, no. 5, pp. 60–63, 2016.
- [13]. X. Guo, H. Miao, L. Li et al., "Efficacy of four different irrigation techniques combined with 60 °C 3% sodium hypochlorite and 17% EDTA in smear layer removal," *BMC Oral Health*, vol. 14, p. 114, 2014.
- [14]. C. Rico-Romano, Á. Zubizarreta-Macho, M. R. Baquero-Artigao, and J. Mena-Álvarez, "An analysis in vivo of intracanal bacterial load before and after chemo-mechanical preparation: a comparative analysis of two irrigants and two activation techniques," *Journal of Clinical and Experimental Dentistry*, vol. 8, no. 1, pp. e9–e13, 2016.
- [15]. A. Al-Jadaa, F. Paqué, T. Attin, and M. Zehnder, "Necrotic pulp tissue dissolution by passive ultrasonic irrigation in simulated accessory canals: impact of canal location and angulation," *International Endodontic Journal*, vol. 42, no. 1, pp. 59–65, 2009.
- [16]. Mohammadi Z, Dummer PM. Properties and applications of calcium hydroxide in endodontics and dental traumatology. *Int Endod J* 2011; 44: 697-730 [PMID: 21535021 DOI: 10.1111/j.1365-2591.2011.01886.x]

Raesa Shafiq, et al. "Endodontic Management of Mandibular First Molar with Endodontic-Periodontal lesion: A case report." *IOSR Journal of Dental and Medical Sciences (IOSR-JDMS)*, 21(08), 2022, pp. 39-43.