

Brown's tumor - a great mimicker.

Dr. Vaishak, Dr. Josey Verghese, Dr. Beenamol, Dr. Abin, Dr. Reshma

Corresponding author: Vaishak S, vaishak.s.140@gmail.com

Abstract

We present a case of 47 year old female patient who presented with complains of fatigue, pain in bilateral upper and lower limbs especially around right knee and difficulty in walking. Xray of right knee shows multiple lytic lesions with cortical breakdown in distal femur and proximal tibia. MRI shows presence of multiple solid cystic lesion with septations and fluid-fluid levels, enhancing soft tissue. Differential of fibrous dysplasia, metastasis, brown tumor was considered. Radiograph of hands shows osteopenia, subperiosteal bone resorption, multiple lytic bone lesions, acral osteolysis - all in favor of hyperparathyroidism. USG neck shows well defined hypoechoic lesion in inferior pole of left lobe of thyroid and sestamibi scan shows uptake suggestive of adenoma. Surgical resection was done and HPR shows parathyroid adenoma. Patient condition improved gradually post excision and supportive medications.

Keywords: case report, brown tumor, hyperparathyroidism.

Date of Submission: 18-07-2022

Date of Acceptance: 02-08-2022

I. Introduction

Hyperparathyroidism are classified into primary, secondary and tertiary. It is associated with osteopenia, bone resorption in subperiosteal, subcartilagenous, subligamentous, subarticular areas, multiple lytic bone lesions called Browns tumor. It is a great mimicker of other bone lesions along with hydatid cyst and hemophilia. It is vital to have browns tumor in top of differentials while considering multiple lytic lesions with non mineralized matrix and fluid fluid levels. Radiologist play a vital role in appropriate diagnosis of this mimicker and contribute to proper management of the patient.

Narrative

A 47yr old female presented with complains of chronic pain in right knee, fatigue, generalised myalgia, bilateral shoulder pain from one year, swelling in right knee from 3 months. She is not diabetic, hypertensive, hypothyroid, renal disease or other known co-morbidities. She is not on any medications. No significant family history. She presented to out patient department and general examination was normal. Local examination showed swelling, tenderness in right knee. Range of motion was not limited. radiograph of knee showed presence of large lytic lesion with cortex breakdown and soft tissue in epiphyses of right distal femur. Initially treating clinician provisional diagnosis was giant cell tumor. She was referred to MRI for further evaluation.

II. Discussion

Brown's tumor is a mimicker of giant cell tumor, fibrous dysplasia, multiple myeloma, metastases. Histologically brown tumor has similar picture to that of GCT. Ground glass matrix is common to both brown and fibrous dysplasia. Osteopenia and multiple lytic lesions are also seen in multiple myeloma. Multiple lytic bone lesions are common in lytic metastases and brown. However metastases are uncommon to see beyond elbow and knee. Parathyroidectomy will result in complete resolution of brown tumor.

It is quite common to misdiagnose brown tumor and any such delay can make patient prone to develop complications like pathological fracture. In our case majority were present in weight bearing bones like distal femur and tibia, neck of femur. Once fracture occurs it carries its own risk of morbidity. A population based cohort study by Khosla et al. of patients with PHPT showed that these patient exhibited increased vertebral, distal forearm fractures, rib, pelvic and marginal increase in risk for femoral fractures. Overall parathyroidectomy is viewed as definitive and curative treatment for this condition. Significant improvement in BMD is seen after surgery. But it will take many months, years till sufficient BMD is increased and risk for fracture is decreased.

Acknowledgements

-No disclosure.

-No conflict of interest

- Written and informed consent obtained from the patient for publication of case report and accompanying images.

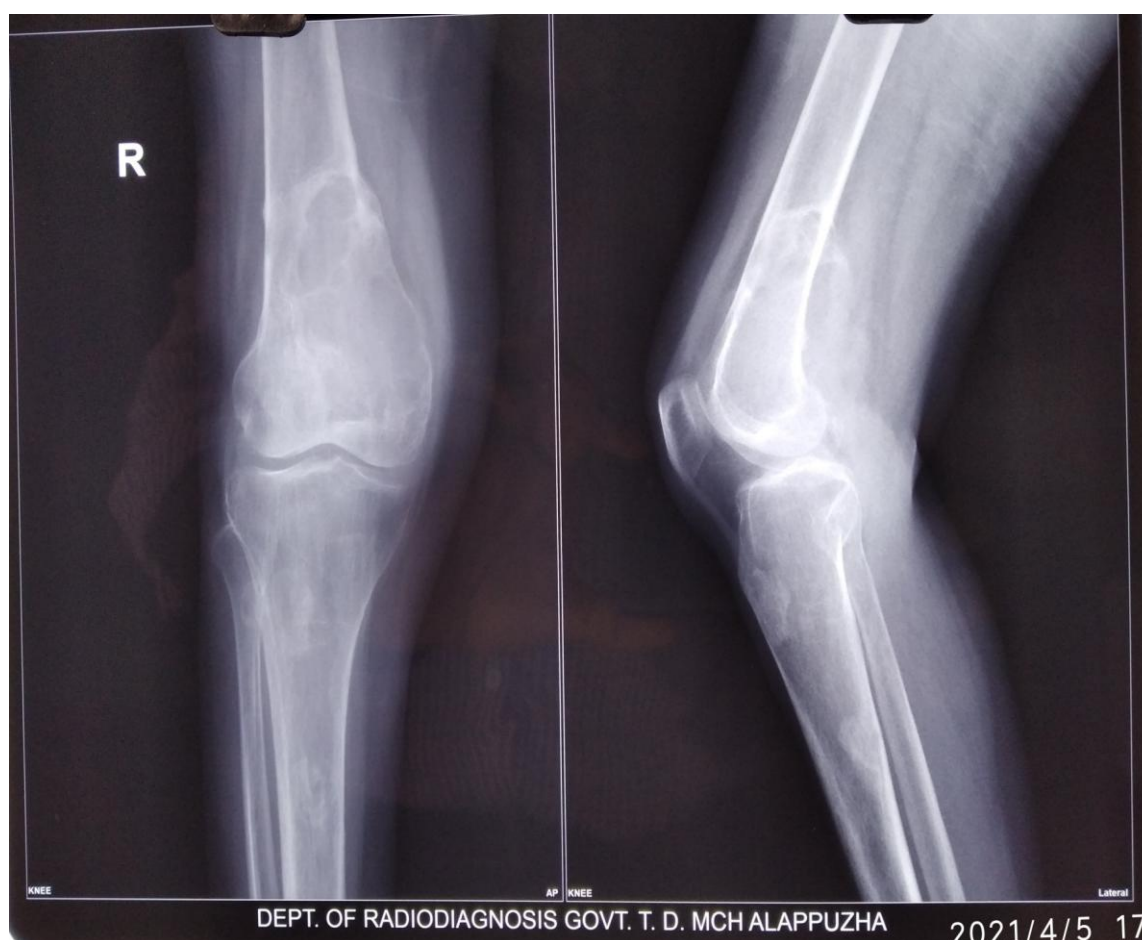References

- [1]. Brown Tumors: A Case Report and Review of the Literature - Özgür Can,a,* Başak Boynueğri,a Ali Murat Gökçe,b Ebru Özdemir,c Ferhat Ferhatoğlu,c Mustafa Canbakan,a Gülizar Manga Şahin,a Mesut İzzet Titiz,f and Süheyla Apaydine.
- [2]. Brown Tumor as a Result of Hyperparathyroidism in an End-Stage Renal Disease Patient-
- [3]. Jesse M. Jakubowski,¹ Ines Velez and Shawn A. McClure.
- [4]. A case report of brown tumor in a patient with chronic renal failure and renal cell carcinoma. Yong-Jun Liu MD, PhD, Elizabeth E. Fraunhoffer MD, Eric Walker MD, MHA, Nicole C. Williams MD. First published: 29 November 2017 <https://doi.org/10.1002/dc.23854>

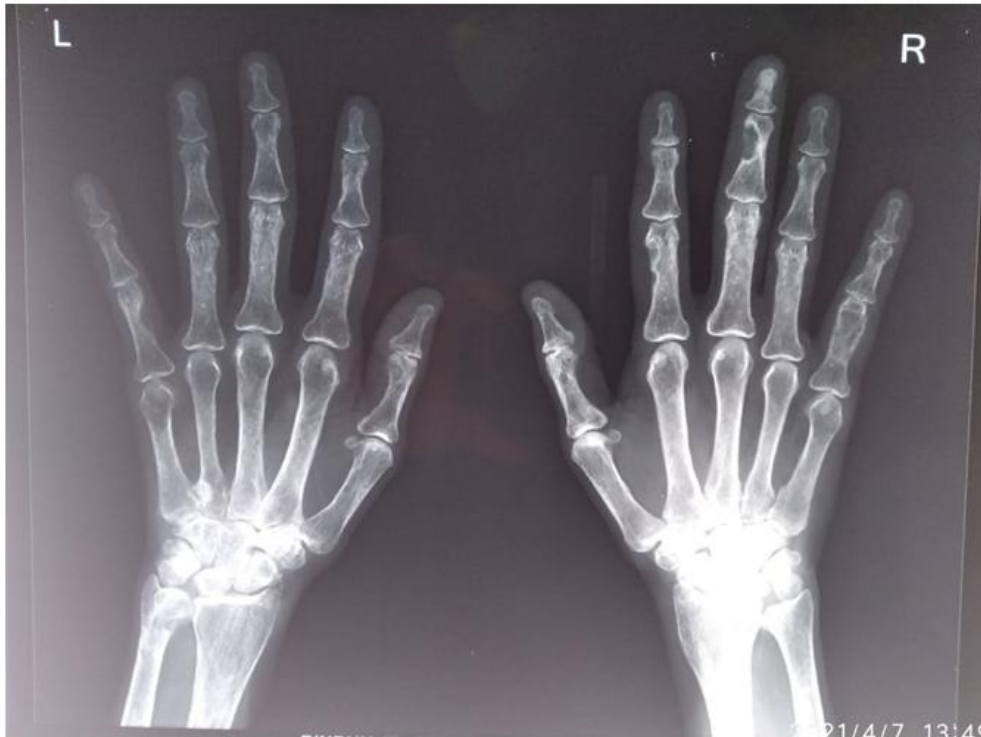Author Affiliations

Department of Radiodiagnosis, Govt TD Medical College, Alappuzha.

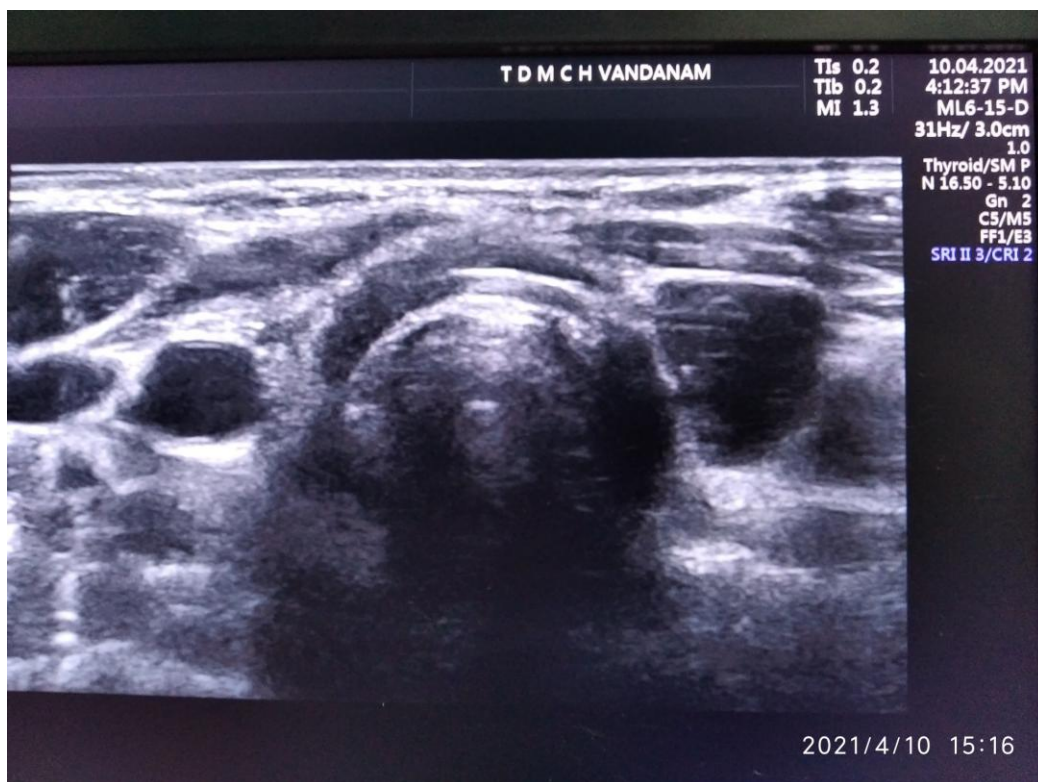Attachments



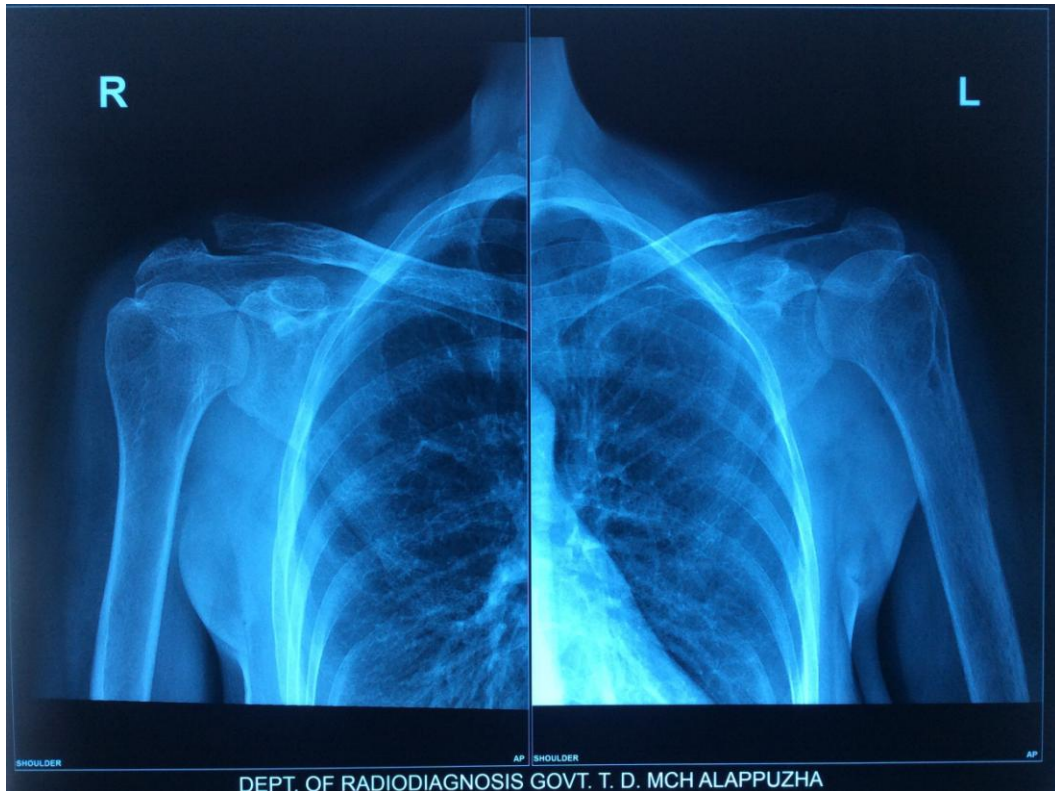
Radiograph of right knee - AP and lateral view shows - multiple bone lesions in distal aspect of femur, proximal tibia and fibula. In distal aspect of femur there is a well defined lesion with narrow zone of transition in epimetaphyseal location not reaching upto subarticular aspect. There is cortical breakdown with extra-osseous soft tissue. No aggressive periosteal reaction. No osseous or chondroid matrix. Similar lesions seen in proximal tibia and fibula without cortical breakdown.



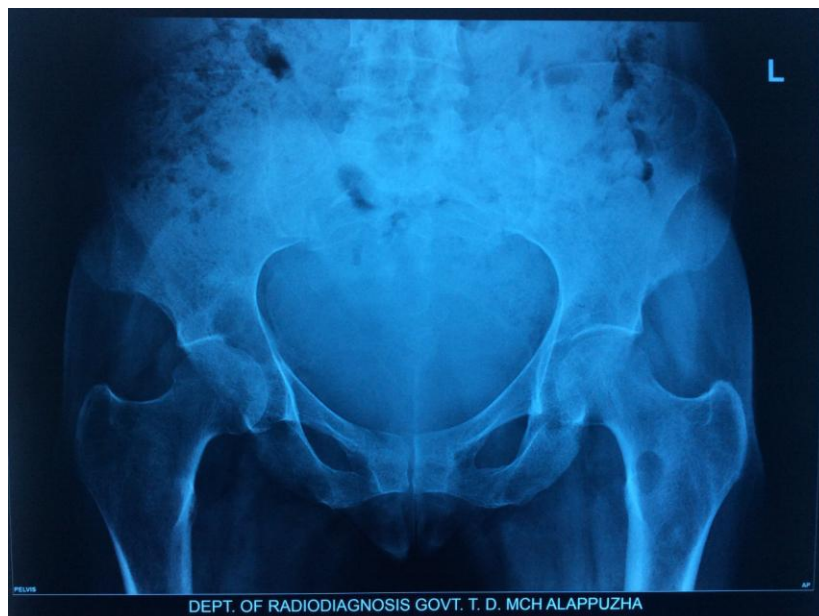Radiograph of both hands - AP view shows presence of osteopenia, subperiosteal bone resorption, multiple areas of cortical bone destruction in proximal phalanx of right index finger, middle phalanx of right middle finger, proximal phalanx of left little finger, expansile bone lesion in proximal phalanx of right little finger (possibly brown's tumor), subtle acral osteolysis.



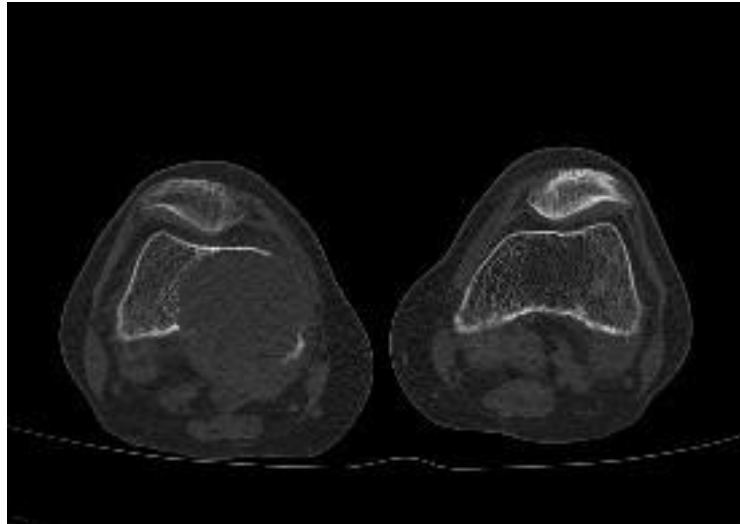
Ultrasound of neck shows a well defined hypoechoic lesion in inferior pole of left lobe of thyroid gland with mild internal vascularity possibly parathyroid lesion.



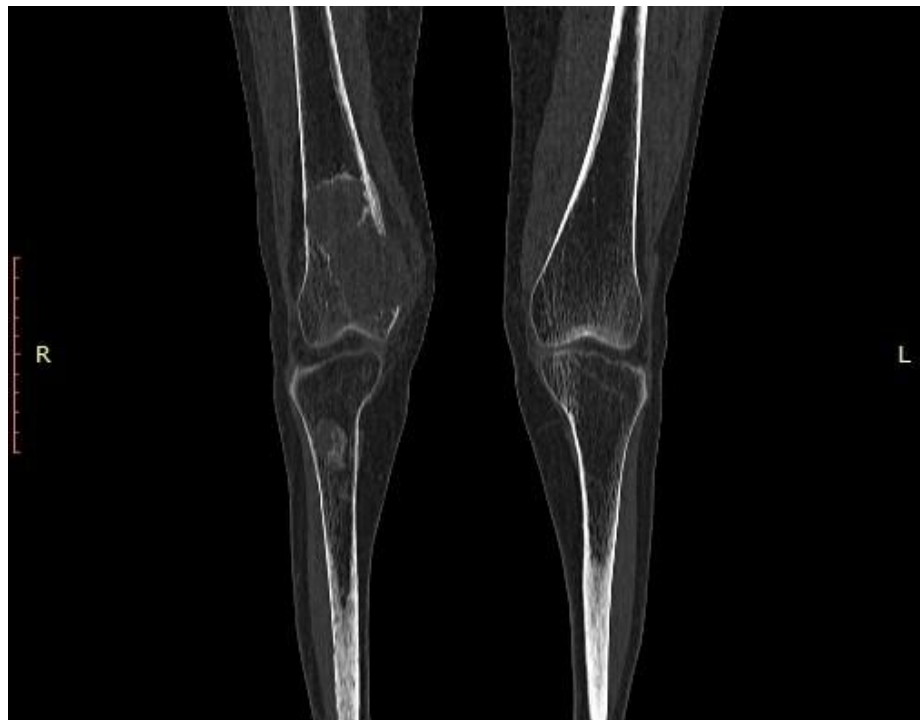Radiograph of both shoulder shows diffuse osteopenia, subarticular bone resorption and pseudo-widening in bilateral acromioclavicular joints.



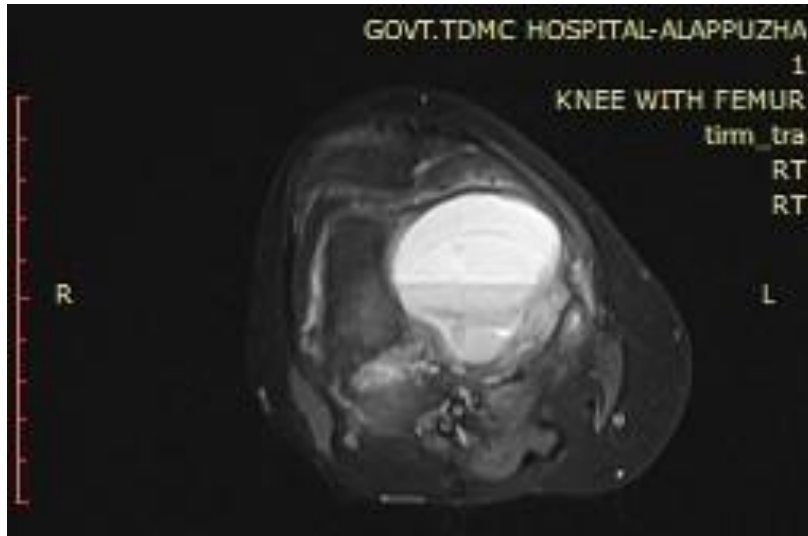Radiograph of pelvis shows presence of lytic lesions in right acetabulum and neck, lesser trochanter of left femur.



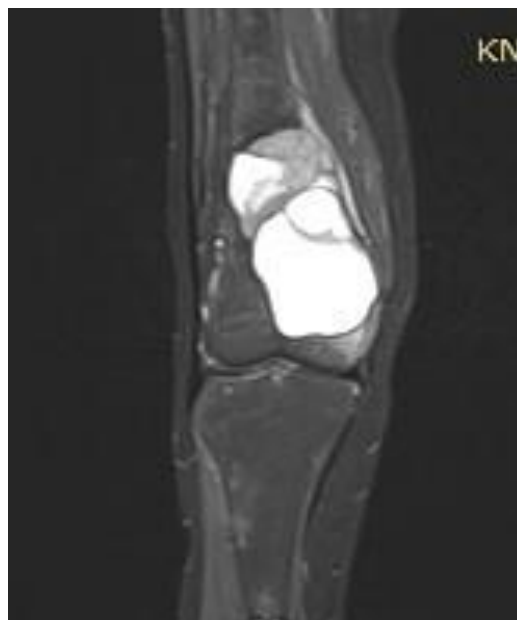
Axial CT sections shows non mineralised fibrous matrix with cortical breakdown. No periosteal reaction.



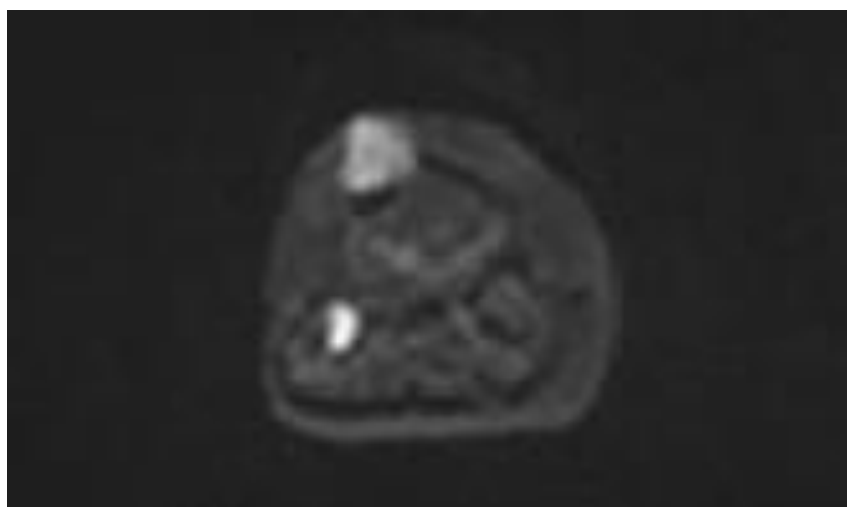
Coronal CT shows fibrous non mineralized matrix.



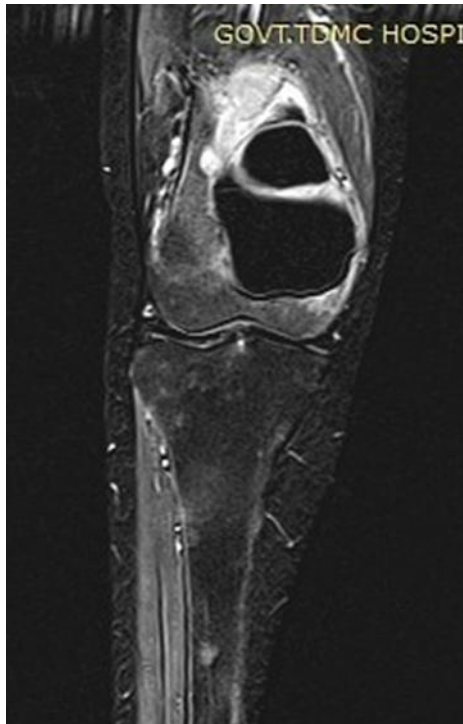
Axial tirm sequence shows T2 hyperintense lesion with fluidlevels.



Coronal PDFS sequence shows multiloculated cystic lesion with fluid fluid levels and softtissue.







DWI images shows areas ofrestriction.



Post contrast subtracted images shows enhancement of walls and soft tissue.

An ISO 9001:2015 Certified Laboratory
ISO reference : CB-035-M5

 **Chethana**
Janakeeya Lab
We are with you...

  
TDMC P.O Alappuzha-688005
PH: 0477 2282277
e-mail: chethanapalliative@gmail.com
web: chethanapalliative.org

Description of Test	Observation and Remarks	Reference range
BIOCHEMISTRY		
Calcium	: 10.9 mg/dL	8.4- 11.5

Examinee Details:
Age & Gender :
Telephone : 8129839728
Area :
IP/OP No :

Referred by:
RSBY
Sample ID :

Sample Details:
Sample Date : 08-Apr-2021 3:39 pm
Reported On :
Printed On : 08-Apr-2021 6:45 pm
Lab No : CJL-112074

Serum Biochemistry shows normal calcium levels.

H.O. Sreekanth Road (EAST), Ravipuram, Kochi - 16
Phone : 0484 4112000, 2367044, 2358066
CIN U85195 KL 1990 PTC 005887, PAN No. AABCM 6449H, ICMR Regd No for Covid19 MS DRCK

medivision
Diagnose. Treat. You Can Trust

LABORATORY TEST REPORT

Name : [REDACTED] Sample ID : 342105870 Collected : 09/04/2021 17:09
Age : [REDACTED] Reg. Date : 09/04/2021 Accepted : 10/04/2021 07:12
Reff. BY Dr. : [REDACTED] IP/ DOB No. : 112074 Reported : 10/04/2021 08:24
Client Name : Chethana Janakeiyea Lab Nationality : INDIAN Report Status : FINAL
Sample Collected At : Chethana Janakeiyea Lab Sample Processed At : MEDIVISION-COCHIN

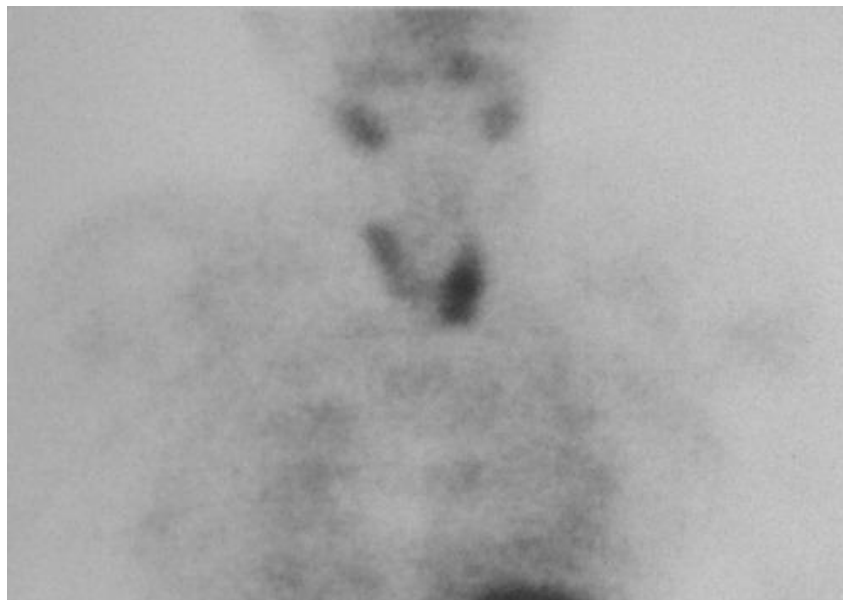
Department Of Biochemistry

PARAMETER	OBSERVED VALUE	UNITS	REFERENCE RANGE
Para Thyroid Hormone- Intact (iPTH) ECLIA	: H 630.00	pg/mL	14.9 - 56.9

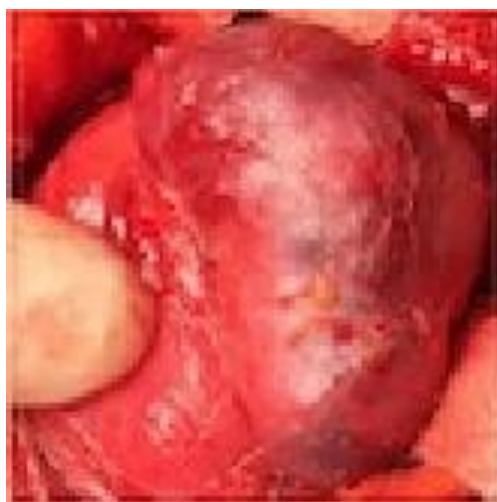Sample Type :- Serum

*** END OF REPORT ***

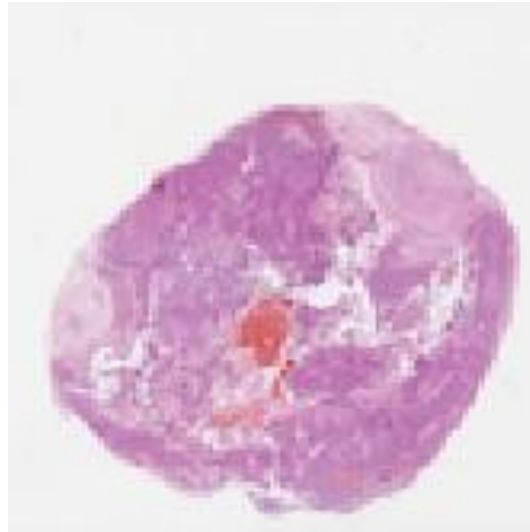
Parathyroid hormones are elevated.



⁹⁹Tc m sestamibi scan shows uptake in inferior pole of left lobe of thyroid. Possibly Parathyroid adenoma.



Surgical gross specimen showing the lesion in thyroid.



Histopathological features suggestive of parathyroidadenoma.

Dr. Vaishak, et. al. "Brown's tumor - a great mimicker." *IOSR Journal of Dental and Medical Sciences (IOSR-JDMS)*, 21(07), 2022, pp. 57-65.