

Pleomorphic adenoma with extensive oncocytic metaplasia- A rare case report reviewed.

Dr. Jinalben Patel¹, Dr. Isha Pathak², Dr. Minesh B. Gandhi³, Dr. Falguni R. Shah⁴, Dr. Cherry K. Shah⁵

¹ (Department of pathology, Smt. NHL Municipal Medical College/ Gujarat University, India)

² (Department of pathology, Smt. NHL Municipal Medical College/ Gujarat University, India)

³ (Department of pathology, Smt. NHL Municipal Medical College/ Gujarat University, India)

⁴ (Department of pathology, Smt. NHL Municipal Medical College/ Gujarat University, India)

⁵ (Department of pathology, Smt. NHL Municipal Medical College/ Gujarat University, India)

Abstract: We reported a rare case of major salivary gland pleomorphic adenoma, in which the majority of cells were oncocytic. A 49 year old male patient presented with left side infraauricular mass otherwise asymptomatic before 1 month. Mass was insidious in onset and not associated with any history of trauma, insect bite, pain and fever. A computed tomography scan of the neck revealed mixed solid cystic lesion in the deep lobe of left side parotid gland. Fine needle aspiration was performed to distinguish non-neoplastic from neoplastic causes of salivary gland lesions and help in early intervention if suspicious of malignancy revealed. Diagnosis of benign salivary gland tumor-pleomorphic adenoma with squamous metaplasia was given on the basis of cytopathological examination, then patient was operated for left side parotidectomy and biopsy was sent to histopathology department. According to gross morphology and histopathological analysis, diagnosis of pleomorphic adenoma with extensive oncocytic metaplasia was given.

Key Words: Salivary gland tumor, Pleomorphic adenoma, Oncocytes

Date of Submission: 08-06-2022

Date of Acceptance: 24-06-2022

I. Introduction

Salivary gland tumors are known for their varied histomorphological appearance, which sometimes poses a diagnostic challenge for pathologists. One of such appearances is the oncocytic change in tumor cells of benign and malignant salivary gland tumors.¹ Pleomorphic adenoma (PA) is the most common salivary gland tumor characterized by histo-morphological diversity in the form of myxoid, hyalinized, chondroid, osseous, squamous areas. One particular feature present focally in tissue sections may dominate the smear to the extent that the nature of the tumor is not recognized. However, predominantly oncocytic cells in PA are extremely rare to occur.²⁻⁴ Rarely, vascular invasion can be present, but this is not associated with adverse outcome.⁵⁻⁶

II. Case Report

A 49 year old Hindu male patient came to outpatient department with a chief complaint of left side infra auricular swelling since one month. Patient was relatively asymptomatic before one month, then he developed left side infra auricular swelling which was insidious in onset, gradually increase in size. There was no history of trauma, insect bite, drug allergy or tuberculosis. It was not associated with pain, fever and loss of appetite, difficulty in swallowing, difficulty in breathing, change of voice and throat pain. There was no complain of earache, ear discharge, decreased hearing, giddiness or ringing sensation in ear. Physical examination revealed diffuse, non tender, non warm, firm to hard, non mobile, non compressible, non fluctuant, non transilluminant, non reducible swelling over left side angle of mandible with normal overlying skin.

Ultrasonography of neck was suggestive of 30 x 25 mm sized solid hypoechoic lesion in deep part of left parotid gland with small foci of calcification with two left upper cervical lymph nodes. Computed tomography scan of neck was suggestive of mixed solid cystic lesion measuring 31 x 26 x 25 mm in deep lobe of left parotid gland with small foci of calcification within and subcutaneous tissue edema in the parotid space, overlying the masseter muscle and retroauricular region. Fine needle aspiration was planned and performed which revealed benign salivary gland tumor (pleomorphic adenoma) with squamous metaplasia. Based on radiological and cytopathological findings, patient underwent left side parotidectomy. The lesion was biopsied and sent for the histopathological examination. Gross examination revealed two separate whitish brown tissue portions, superficial and deep lobe. Superficial lobe weighed 9 gm and 45 x 30 x 20 mm in size and deep lobe

weighed 12 gm and 55 x 25 x 15 mm in size. On cut section superficial lobe showed normal cut surface and deep lobe showed one well circumscribed brownish growth measuring 15 x 10 mm.(Figure1)

Microscopic examination revealed sheets and multiple foci of tightly packed large cells with granular eosinophilic to pale cytoplasm, large vesicular nuclei with prominent nucleoli.(Figure 4) Scattered bizarre cells are also seen with areas of infarction. At the periphery of the tumor there was presence of conventional pleomorphic adenoma morphology in form of ducts, tubules with fibromyxoid stroma. No evidence of significant mitotic activity, perineural invasion or necrosis was seen. Tumor was surrounded by the rim of normal salivary gland tissue. Resected surgical margins were free from tumor. After treatment with diastase Periodic acid-Schiff stain was negative. Based on above findings and histopathological examination diagnosis of Pleomorphic adenoma of major salivary gland with extensive oncocytic metaplasia was made.

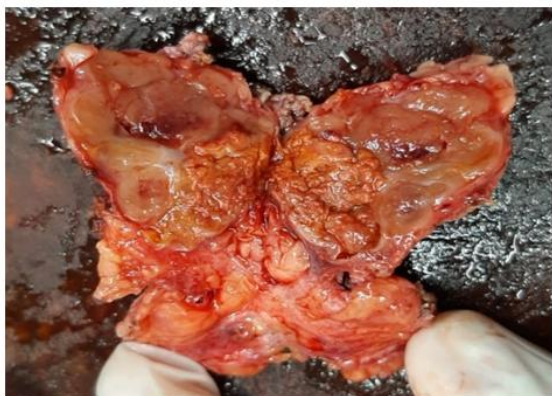

Figure 1: Deep lobe of Parotid gland with well circumscribed brownish growth

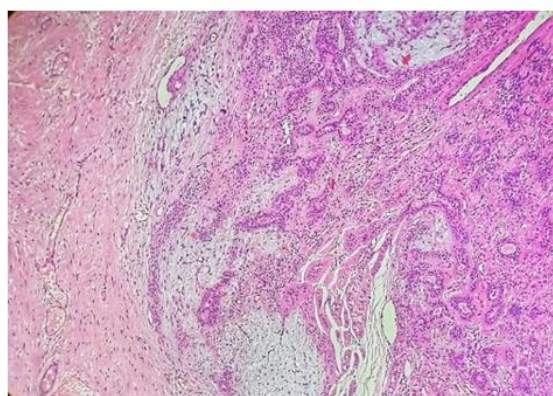


Figure 2: Conventional pleomorphic adenoma at the periphery of tumor

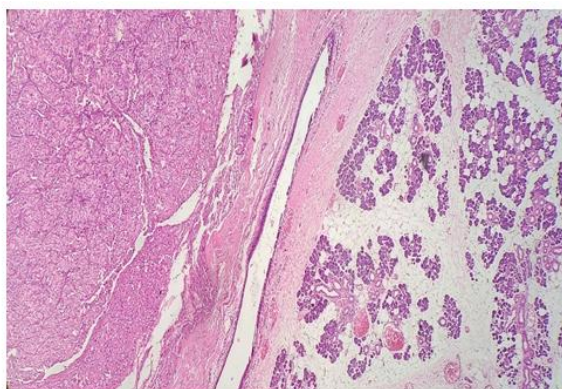


Figure 3: Pleomorphic adenoma with fibromyxoid Stroma and oncocytic metaplasia

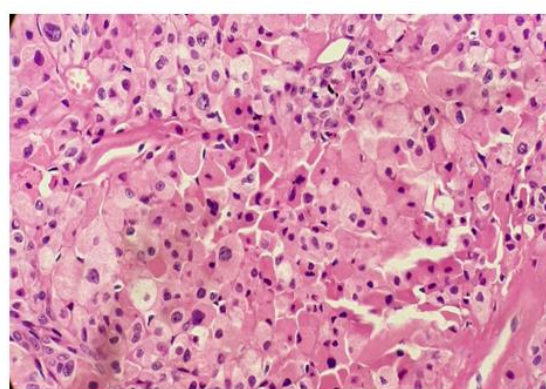


Figure 4: PA with oncocytes having granular eosinophilic to pale cytoplasm

III. Discussion

Pleomorphic adenoma typically presents as a painless, persistent swelling and they occur at any age. They are most common in adults and during the third fifth decades of life, but they may be found during childhood. Approximately 75% of pleomorphic adenoma arise in the parotid gland. The rest occur in the submandibular gland (approximately 5% to 10%) and the minor salivary glands (approximately 10%). The vast majority (>90%) of pleomorphic adenoma arise in the superficial portion of the parotid gland, whereas the rest present in the deep lobe occupying the parapharyngeal space.^{7,11} In general women are most commonly affected than men, except for warthin tumors and high grade carcinomas. Epithelial tumors constitute 80-90% of all salivary gland tumors, with majority of being benign (75%) and pleomorphic adenoma being the most common among 65% of all tumors. Pleomorphic adenomas are generally slow growing tumor, solitary often present for years although may be synchronous or metachronous with other tumors, usually Warthin tumor but also mucoepidermoid carcinoma, acinic cell carcinoma and adenoid cystic carcinoma.⁸ Pleomorphic adenoma consists of a mixture of myoepithelial cells and ductal cells within a mesenchymal background with frequent metaplastic changes.. The capsule of pleomorphic adenoma consists of fibrous tissue of varying thickness. Pleomorphic adenomas show a vast number of different microscopic patterns depending on the arrangement of the epithelial cells and how much and what type of stroma is present.⁹ In warthin's tumor an oncocytic epithelial

component and a prominent lymphoid stroma with well-developed follicles blend together. Oncocytomas may occur in the setting of multifocal oncocytic metaplasia. These should not be misinterpreted as infiltrative growth.

Squamous metaplasia is a common feature in a number of salivary gland lesions and most commonly seen in necrotising sialadenitis and pleomorphic adenomas. It is usually seen in larger ducts but also as free-lying sheets of epidermoid tissue. Squamous metaplasia may be a finding in almost any salivary gland tumor that has been exposed to preoperative fine needle aspiration. Oncocytic metaplasia is not as common as squamous metaplasia and is usually present as focal changes. On rare occasions almost the entire adenoma can be affected, and the lesion can then be misdiagnosed as oncocytoma.⁹ In tumors with extensive oncocytic metaplasia and clear cell change, such a pleomorphic adenoma may be confused with acinic cell carcinoma. Even some non-oncocytic tumors like myoepithelioma, acinic cell carcinoma, mucoepidermoid carcinoma, basal cell adenoma, polymorphous low grade adenocarcinoma, and sebaceous adenoma can show predominantly oncocytic histomorphologic feature. However, their presence in PA is regarded as an extremely rare phenomenon and can cause diagnostic pitfall in the differential diagnosis.¹⁰ Histomorphological appearance of oncocytes describes the cells with abundant eosinophilic granular cytoplasm and central hyperchromatic nuclei attributed to abundant mitochondria present in cytoplasm of cell. Presence of oncocytes in salivary gland tumors is not a rare phenomenon as they are considered as a prominent feature of Warthin's tumor, oncocytoma, and oncocytic carcinoma. The cytoplasmic granules in an oncocytic acinic cell carcinoma stain with PAS and are resistant to diastase digestion, while oncocytic cells in non-acinic tumors are not resistant to diastase. Infarction of pleomorphic adenoma can occur following fine-needle aspiration. Spontaneous infarction is not uncommon in Warthin tumour, but only a few cases have been reported in pleomorphic adenoma.

IV. Conclusion

The most common benign salivary gland tumor is the Pleomorphic adenoma (PA). Pleomorphic adenoma is a circumscribed and encapsulated, often lobulated tumor with a fibrous capsule of varying thickness. It is characterized by highly variable growth patterns in different areas of the same tumor. We have reported a case of Pleomorphic adenoma in deep lobe of parotid gland with histopathological evidence of extensive oncocytic metaplasia which is a rare event, hence reported.

References

- [1]. Brandwein MS, Huvos AG. Oncocytic tumors of major salivary glands. A study of 68 cases with follow-up of 44 patients. *The American journal of surgical pathology*. 1991 Jun 1;15(6):514-28.
- [2]. Skalova A, Michal M, Ryška A, Simpson RH, Kinkor Z, Walter J, Leivo I. Oncocytic myoepithelioma and pleomorphic adenoma of the salivary glands. *Virchows Archiv*. 1999 Jun;434(6):537-46.
- [3]. Mariano FV, Vidaurre EC, Bologna-Molina RE, Carlos-Bregni R, de Almeida OP. Histopathological and immunohistochemical analysis of oncocytic pleomorphic adenoma. *Indian Journal of Pathology and Microbiology*. 2011 Jan 1;54(1):193.
- [4]. Pulitzer DR, Reitmeyer WJ. Oncocytic pleomorphic adenoma of the parotid gland. *Journal of surgical oncology*. 1987 Mar;34(3):198-201.
- [5]. Ethunandan M, Witton R, Hoffman G, Spedding A, Brennan PA. Atypical features in pleomorphic adenoma—a clinicopathologic study and implications for management. *International journal of oral and maxillofacial surgery*. 2006 Jul 1;35(7):608-12.
- [6]. Skalova A, Altemani A, Di Palma S, Simpson RH, Hosticka L, Andrlé P, Laco J, Toner M, Vozmitsel MA, Szakacs S, Kazakov DV. Pleomorphic adenoma of the salivary glands with intravascular tumor deposits: a diagnostic pitfall. *The American Journal of Surgical Pathology*. 2012 Nov 1;36(11):1674-82.
- [7]. Batsakis JG. Heterotopic and accessory salivary tissues. *Annals of Otolaryngology, Rhinology & Laryngology*. 1986 Jul;95(4):434-5.
- [8]. Papadogeorgakis N, Kalfarentzos EF, Vourlakou C, Malta F, Exarhos D. Simultaneous pleomorphic adenoma of the left parotid gland and adenoid cystic carcinoma of the contralateral sublingual salivary gland: a case report. *Oral and maxillofacial surgery*. 2009 Dec;13(4):221-4.
- [9]. Hellquist H, Skalova A. *Histopathology of the salivary glands*. Springer; 2014 Sep 9.
- [10]. Ferreira JA, Stylopoulos N. Oncocytic differentiation in salivary gland tumours. *The Journal of Laryngology & Otolaryngology*. 1995 Jun;109(6):569-71.
- [11]. Sternberg, Stephen S., Stacey E. Mills, and Darryl Carter. *Sternberg's Diagnostic Surgical Pathology*. 6th ed. Philadelphia: Wolters Kluwer Health/Lippincott Williams & Wilkins, 2015.

Dr. Jinalben Patel, et. al. "Pleomorphic adenoma with extensive oncocytic metaplasia- A rare case report reviewed." *IOSR Journal of Dental and Medical Sciences (IOSR-JDMS)*, 21(06), 2022, pp. 59-61.