

Neurosurgical Perspective in Covid-19 associated Rhino Orbital Cerebral Mucormycosis (ROCM): A Case series study in government general hospital, Guntur.

Dheeraj¹, Seshadri Shekhar^{2*}, G Penchalaiah³, B Chandra Shekhar³, Ch Praveen³, Hanuma Srinivas³, G Satya Navamani³, K.V.V. Satyanarayana Murthy⁴

1. Postgraduate student, Department of Neurosurgery, Guntur Medical College, Guntur, Andhra Pradesh, India.
2. Associate Professor, Department of Neurosurgery, Guntur Medical College, Guntur, Andhra Pradesh, India.
3. Assistant Professor, Department of Neurosurgery, Guntur Medical College, Guntur, Andhra Pradesh, India.
4. Professor & HOD, Department of Neurosurgery, Guntur Medical College, Guntur, Andhra Pradesh, India

*Corresponding Author: Prof. Dr. K.V.V. Satyanarayana Murthy
Professor & HOD, Department of Neurosurgery, Guntur Medical College, Guntur, Andhra Pradesh, India.

Abstract:

Introduction: Mucormycosis is caused by the mucorale group of fungi. These fungi are ubiquitous. Inhalation of fungal spores is harmless in immunocompetent individuals but can cause life-threatening disease in those who are immunocompromised¹. Overlapping with the rise in COVID-19 cases, there was a surge of ROCM in those with active or recent COVID-19 infections. **Objectives:** The study was aimed to understand the risk factors, the areas of intracranial involvement and the role of neurosurgical interventions in COVID 19 associated ROCM. **Materials And Methods:** This a retrospective case series analysis conducted in Guntur government hospital, Guntur, Andhra Pradesh from June 2021 to September 2021 in patients presenting to the department of neurosurgery with rhino orbital cerebral mucormycosis. All patients with confirmed ROCM with intracranial extension were analyzed for risk factors, orbital and sinus involvement, use of antifungals, site of intracranial involvement and if neurosurgical intervention required or conservative management. **Results:** A total of 40 cases with ROCM were studied. 36 patients (90%) had diabetes mellitus, and 36 patients (90%) were given steroids. 28 patients (70%) had both orbital involvement and maxillary involvement. 4 patients (10%) had only maxillary involvement and 8 patients (20%) had only orbital involvement. 20 patients (50%) had both frontal and temporal lobes involved. 6 patients (15%) had only temporal lobes involved. 10 patients (25%) had only frontal lobe involvement, 4 (10%) patients had cerebellar involvement and 6 patients (60%) had cavernous sinus involvement. Of the 40 patients 30 (75%) patients were treated conservatively whereas 10 patients (25%), with abscess size more than 2.5 cms required neurosurgical intervention. **Conclusion:** In the context of covid-19 pandemic, there is a surge of ROCM especially in patients with prolonged steroid usage and immune compromised conditions like DM. Most Patients with orbital and maxillary sinus involvement had intracranial extension in the form of frontal or temporal abscess or both. Some patients were managed conservatively while some required neurosurgical intervention along with antifungals.

Abbreviations: Rhino Orbital Cerebral Mucormycosis (ROCM), Coronavirus, Acute respiratory syndrome

Date of Submission: 29-05-2022

Date of Acceptance: 10-06-2022

I. Introduction:

Coronavirus disease 2019 (COVID-19) caused by severe acute respiratory syndrome coronavirus 2 (SARS-CoV-2) has been associated with a wide range of opportunistic bacterial and fungal infections [1]. Mucorales is a fungal order in the subphylum mucormycotina that can cause mucormycosis, a fulminant, opportunistic infection in immunocompromised human hosts [2]. These fungi are ubiquitous and present in any environment including hospitals. Inhalation of fungal spores is harmless in immunocompetent individuals but can cause life-threatening disease in those who are immunocompromised [1]. The immune system is weak in those with uncontrolled diabetes mellitus, prolonged intake of steroids or immunosuppressant medications,

malignancies and other debilitating conditions like chronic liver disease and chronic malnutrition state [3]. It is notable that these conditions can also indicate risk of severe COVID-19 infection [4]. COVID-19 pandemic left the world reeling over the past year. The second wave has been particularly devastating in India. During the months of April and early May 2021, millions were affected and thousands were seeking hospital care [5]. Unprecedented numbers needed oxygen therapy and admission putting tremendous pressure on health infrastructure [6]. Overlapping with the rise in COVID-19 cases, there was a surge of rhino-orbito-cerebral mucormycosis in those with active or recent COVID-19. We designed a retrospective observational study in our department with an objective to document the possible risk factors, orbital and sinus involvement, intracranial extension, effect of antifungals and role of neurosurgical intervention in ROCM in the context of the COVID-19 pandemic.

II. Materials And Methods:

This a retrospective case series analysis conducted in Govenament General Hospital, Guntur from June 2021 to September 2021 in patients presenting to the department of neurosurgery with rhino orbital cerebral mucor mycosis. All patients with confirmed ROCM with intracranial extension were analysed for demographics , steroid use and duration of steroid use during covid-19 infection , orbital and sinus involvement , use of antifungals preop and post operatively, site of intracranial involvement and surgical intervention performed, residual lesions, need for re-exploration and post-op meningitis. Patients with ROCM with no history of COVID-19 infection and patients with ROCM with no intracranial extension were excluded from the study.

III. Results:

A total of 40 cases with ROCM were studied. 24 patients were males and 16 patients were female, giving a ratio of 1.5:1 as shown in figure 1. The patient’s age ranged from 24 to 70 years, with the mean age of 47.385 as shown in table 1.

Figure 1: Gender-wise distribution of study subjects

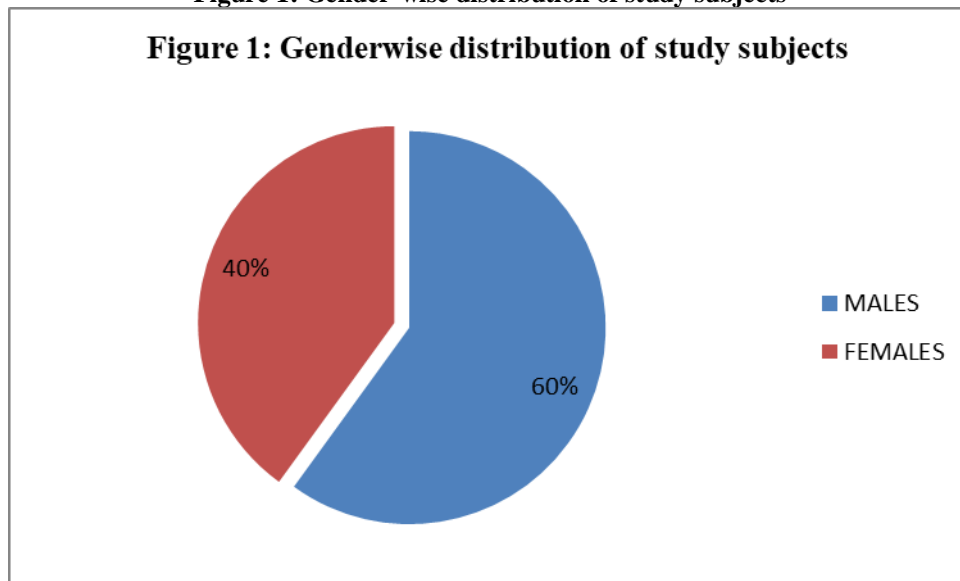


Table 1: Age wise distribution of study subjects

Age in years	Number of study subjects	Percentage
24- 50 yrs	10	25%
51-70 yrs	30	75%
Total	40	100%
Mean age	47.385	

Most of the patients with ROCM were diabetic and required steroid usage oral or intravenous during the acute phase of covid-19 infection. 36 patients (90%) had diabetes mellitus, and 36 patients (90%) were given steroids. 32(80%) patients were both diabetic and required steroids also. 28 patients(70%) had both orbital involvement and maxillary involvement. 4 patients (10%) had only maxillary involvement and 8 patients (20%) had only orbital involvement. 20 patients (50%) had both frontal and temporal lobes involved . 6 patients(15%) had only temporal lobe involved 10 patients(25%) had only frontal lobe involvement , 4(10%) patients had cerebellar involvement and 16 patients (40%) had cavernous sinus involvement. Of the 40 patients

30(75%) patients, who had intra cranial lesions measuring less than 2.5 cms were treated conservatively whereas 10 patients (25%), with abscess size more than 2.5 cms required neurosurgical intervention of which 6 patients had residual lesions on post-operative imaging, but were able to be managed conservatively. 2 out of the 10 patients who underwent surgery expired in the postoperative period.

IV. Discussion:

Mucormycosis is an invasive infection caused by fungi of the order *Mucorales*, which includes *Rhizopus*, *Mucor*, *Rhizomucor*, *Cunninghamella*, and *Absidia*[8] and *Rhizopus oryzae*, the latter being the most commonly implicated organism in this illness.[7] Epidemiologically, this disease is 70 times more common in India than rest of the world.[9] Although, there are no population-based studies to give an exact incidence of the disease, according to computational assessment by Chakrabarti *et al.*, the prevalence in India is 14 cases/100000 population.[10] DM is the most significant risk factor in developing countries like India[11.] A review study done by Singh *et al.* in May 2021 reported a total of 101 cases of mucormycosis with COVID-19 globally. As per the review, 22 patients had CNS involvement. Diabetes and steroid administration were associated with mucormycosis in 80% and 76.3% cases, respectively. [12] These predisposing factors weaken the immunity, thereby making the patient susceptible.[11] Angioinvasion is the hallmark of mucormycosis[13] and the most common pattern in patients with DM is ROCM. Other manifestations include pulmonary, cutaneous, gastrointestinal, disseminated, and localized infections.[14,15] It is noteworthy, that ROCM is an entity that includes a confined sino-nasal infection, exclusive rhino orbital involvement and can present with rhino orbital cerebral manifestation. In a review of 929 cases of mucormycosis done by Roden *et al.*, 30% of the patients had cerebral involvement.

Involvement of the CNS occurs most frequently (70%) due to contiguous spread from the paranasal sinuses and orbits [16]. Mucormycosis of the ethmoid sinus carries a particularly high risk of cavernous sinus thrombosis, because the valveless emissary veins draining this sinus traverse the lamina papyracea and facilitate fungal invasion of periorbital tissue, the orbital apex and the cavernous sinus [17,18]. Maxillary sinus infection often spreads to the hard palate and ethmoid sinuses. Infection of the sphenoid sinus can extend into the cavernous sinus, or invade the carotid artery, and from there embolize to the frontal and parietal lobes. Uncommon manifestations of cranial invasion include sagittal sinus thrombosis and epidural and subdural abscess [19]. Meningitis is rare, but when present, it may manifest as obstructive hydrocephalus due to infiltration of the ventricular lining. Neurological involvement in C-ROCM can manifest in several forms such as nerve palsies (optic, oculomotor complex, trigeminal, facial, eighth), cavernous sinus involvement, local meningeal reactions (basal regions), extra-axial collections, cerebritis, cerebral abscess, large artery stroke or multiple diffusion restricted lesions (infarcts or infarct-like), or hydrocephalus. Any patient, either in the acute phase of COVID-19 or in the post-COVID-19 phase, presenting with visual deterioration, periorbital swelling, proptosis, facial pain or numbness, headache, nasal obstruction or nasal bleed must be dealt with a high index of suspicion; neurological manifestations in the form of encephalopathy, focal neurological deficit or seizures may also be seen.[20,21,22]

The first step in diagnosing C-ROCM is to conduct a diagnostic nasal endoscopy (DNE) and obtain nasal tissue or nasal scrapings from the affected area.[23,24] Tissue biopsies constitute the best specimen for the diagnosis of mucormycosis .

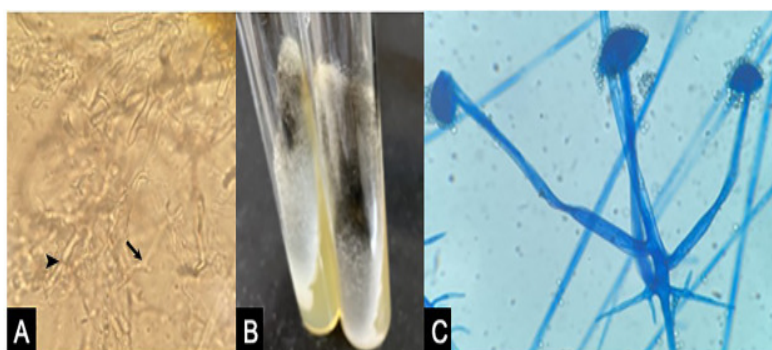


Figure 2 : KOH mount (A) shows broad aseptate fungal hyphae with right angle branching (arrow) and ribbon like folding (arrowhead). White cotton candy growth on SDA media can be seen with older cultures showing greyish patches (B). LCB mount (C) of the culture of *Rhizopus spp*²⁰.

In case of sinusitis, sinus biopsies must be taken. Imaging of the face and cranium plays an important role in the early diagnosis, staging and follow up of patients with ROCM mucormycosis. Magnetic Resonance Imaging (MRI) with gadolinium (GAD) contrast is the overall modality of choice to assess such

patients. Computed Tomography (CT), in addition or singularly, may be required to look specifically at bony involvement, surgical planning and three-dimensional reconstruction of the involved segments for rehabilitation purposes. MRI provides a better visualization of the involved orbital soft tissue, infratemporal fossa, intracranial structures, perineural invasion and vascular compression or obstruction. MRI is also better than CT because iodinated contrast used in CT adds to kidney damage in these patients who are likely to be on nephrotoxic drugs such as amphotericin, etc.[25] T2- weighted images figures 3&4 show an show an isointense to mildly hypointense, heterogenous, or hyperintense sinonasal soft tissue lesions. [26]. Common sites of extra-sinus involvement are orbit and face, followed by orbital apex, masticator space, pterygopalatine fossa, skull base, cavernous sinus and brain parenchyma (with or without vascular involvement). These changes are more evident on T2 fat-suppressed images. On GAD-contrast, as per figure 4c patterns of enhancement may include either an intense homogenous, or heterogeneous, or complete central non-enhancement, with or without a thin irregular rim of peripheral enhancement. Enhancing nerves are a sign of perineural invasion. Restriction on DWI and corresponding hypointensity on ADC maps is noted in the involved areas, presumably a result of fungal angioinvasion, similar to that seen in other ischemic & necrotic lesions.[27] For appropriate evaluation of infarcts or infarct-like lesions, MR angiography is advisable.

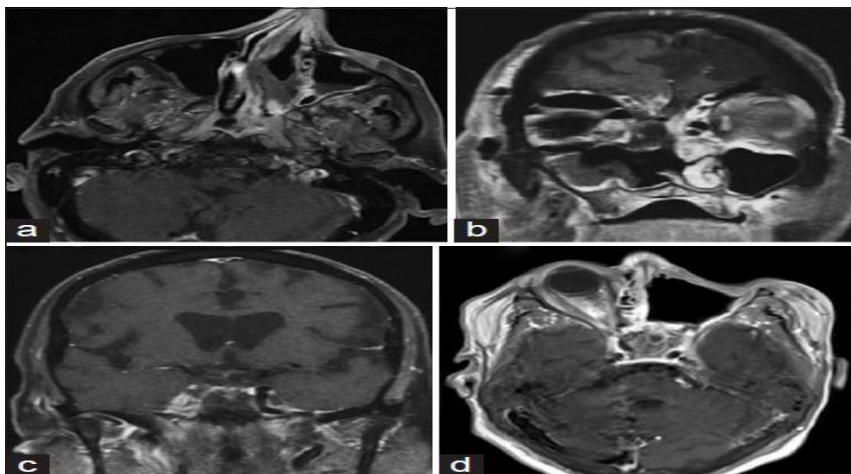


Figure 3: Axial and coronal T1-weighted, gadolinium enhanced, magnetic resonance imaging showing (a and b) sinonasal and (c and d) cavernous sinus invasive fungal infiltration

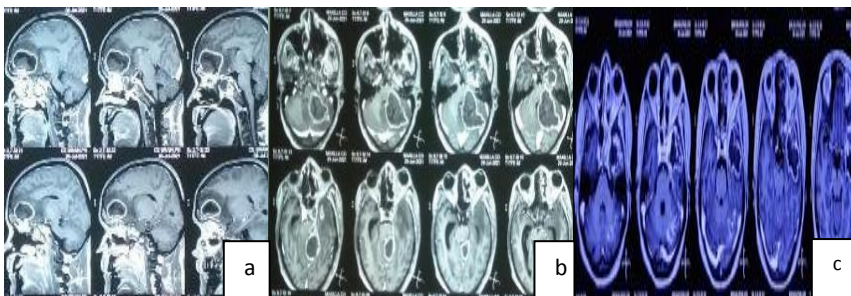


Figure 4: a. MRI contrast sagittal view showing frontal lobe abscess b. axial mri brain contrast showing left cerebellar abscess c. left basi temporal fungal granuloma in axial mri brain contrast

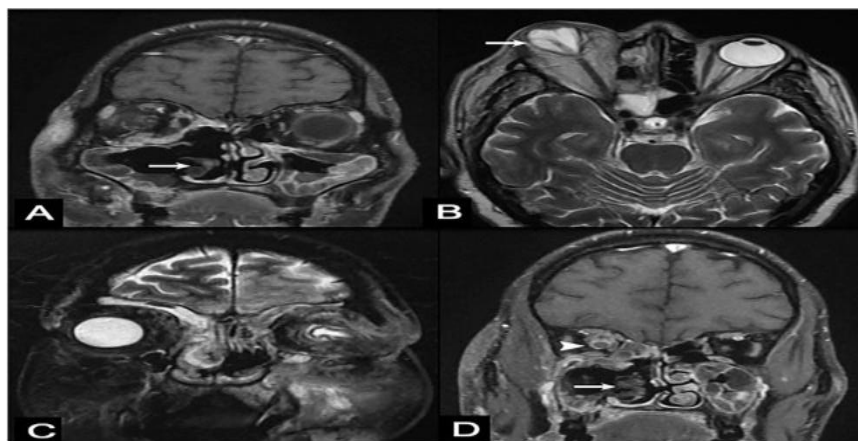


Figure 5: MRI of the brain showing mottled and non-enhancing right inferior turbinate, (A, coronal post-contrast T1-weighted image); tenting of posterior surface of right globe (B, axial T2-weighted image); contiguous intracranial extension of infection into left frontal lobe via cribriform plate, fovea ethmoidalis and orbital plate (C, coronal T2 fat-saturated image); peripheral enhancement of right optic nerve suggestive of perineural spread of the disease (D, coronal post-contrast T1-weighted image).

Early commencement of treatment in patients with ROCM is very important; it has been shown that the survival doubles (61%) if the treatment is initiated within the first 12 days of symptoms. [28] The first-line drug of choice for the treatment of Mucormycosis is Liposomal-Amphotericin B (L-AmB).[22]L-AmB is preferred due to a lower incidence of nephrotoxicity, higher tissue penetrability and higher tissue concentration.[30] In the event that AmB preparations cannot be given as the first line of therapy due to contraindications or non-availability, either parenteral or oral forms of Posaconazole are recommended as an alternative. posaconazole is an option for the oral step-down therapy for patients who have responded to amphotericin B The single most important issue in managing a patient with mucormycosis is appropriate blood glucose control. [28 30 31]Diabetic ketoacidosis is an independent risk factor and Insulin therapy is recommended for proper glycaemic control.[31,32,34] Prophylactic use of anti-epileptic medication is not recommended. Either of Levetiracetam or Lacosamide may be used as they have minimal drug interactions and are available in intravenous as well as per-oral forms.Neurosurgical interventions may be needed in case of raised ICP due to hemispheric stroke, hydrocephalus, abscess/granulomas, and invasive elements in brain parenchyma.[22]

The survival rate is 82% for patients with isolated rhinomaxillary mucormycosis, whereas the prognosis is markedly poor in cases of cerebral involvement, with a survival rate of 38-50%, despite aggressive surgery, antifungal therapy and reversal of underlying predisposing factors[20,33,21]. Importantly, angioinvasion, thrombosis and tissue necrosis of the disease might result in the poor penetration of antifungal agents to the site of the infection. In addition, amphotericin B penetrates poorly into the blood-brain barrier, making it difficult to achieve effective fungicidal levels in cerebral lesions. Therefore, surgical intervention should be considered in the treatment of mucormycosis with necrotic tissues and cerebral lesions. Although the extent and timing of surgical debridement necessary to maximize the outcomes of mucormycosis has never been defined, a recent study supports the concept of an "aggressive-conservative" approach, that uninvolved tissues spared from debridement when possible. [35]

V. Conclusion:

In the context of covid-19 pandemic, there is a surge of ROCM especially in patients with prolonged steroid usage and immunocompromised conditions like DM. Most Patients with orbital involvement,maxillary or ethmoidal sinus involvement had intracranial extension in the form of cavernous sinus thrombosis, frontal or temporal abscess or both, required neurosurgical intervention along with antifungals. Given the high morbidity and mortality of invasive rhino-orbito-cerebral fungal infections, a comprehensive and efficient multidisciplinary approach must be executed. This includes early and aggressive surgical debridement of disease in the paranasal sinuses, foramina of the skull base, and intracranial components, as well as initiation of a robust anti-fungal medical regimen and effective glycaemic control with close follow-up.

References:

- [1]. Lennon NJ, Bhattacharyya RP, Mina MJ, Rehm HL, Hung DT, Smole S, Woolley A, Lander ES, Gabriel SB. Comparison of viral levels in individuals with or without symptoms at time of COVID-19 testing among 32,480 residents and staff of nursing homes and assisted living facilities in Massachusetts. *MedRxiv*. 2020 Jan 1.
- [2]. Hibbett DS, Binder M, Bischoff JF, Blackwell M, Cannon PF, Eriksson OE, Huhndorf S, James T, Kirk PM, Lücking R, Lumbsch HT. A higher-level phylogenetic classification of the Fungi. *Mycological research*. 2007 May 1;111(5):509-47.
- [3]. McNulty JS. Rhinocerebral mucormycosis: predisposing factors. *The Laryngoscope*. 1982 Oct;92(10):1140-3.
- [4]. Centers for Disease Control and Prevention. Underlying medical conditions associated with high risk for severe COVID-19: information for healthcare providers. May 13. 2021 May 13.
- [5]. Ranjan R, Sharma A, Verma MK. Characterization of the Second Wave of COVID-19 in India. *medRxiv*. 2021 Jan 1.
- [6]. Lancet T. India's COVID-19 emergency. *Lancet (London, England)*. 2021 May 8;397(10286):1683.
- [7]. Bennett JE, Dolin R, Blaser MJ. Mandell, Douglas, and Bennett's Principles and Practice of Infectious Diseases E-Book. Elsevier health sciences; 2019 Aug 8.
- [8]. Neofytos D, Horn D, Anaissie E, Steinbach W, Olyaei A, Fishman J, Pfaller M, Chang C, Webster K, Marr K. Epidemiology and outcome of invasive fungal infection in adult hematopoietic stem cell transplant recipients: analysis of Multicenter Prospective Antifungal Therapy (PATH) Alliance registry. *Clinical Infectious Diseases*. 2009 Feb 1;48(3):265-73.
- [9]. Prakash H, Chakrabarti A. Global epidemiology of mucormycosis. *Journal of Fungi*. 2019 Mar;5(1):26.
- [10]. McNulty JS. Rhinocerebral mucormycosis: predisposing factors. *The Laryngoscope*. 1982 Oct;92(10):1140-3.
- [11]. Singh AK, Singh R, Joshi SR, Misra A. Mucormycosis in COVID-19: a systematic review of cases reported worldwide and in India. *Diabetes & Metabolic Syndrome: Clinical Research & Reviews*. 2021 May 21.
- [12]. Ben-Ami R, Luna M, Lewis RE, Walsh TJ, Kontoyiannis DP. A clinicopathological study of pulmonary mucormycosis in cancer patients: extensive angioinvasion but limited inflammatory response. *Journal of Infection*. 2009 Aug 1;59(2):134-8.
- [13]. Gupta RK, Lufkin RB, editors. MR imaging and spectroscopy of central nervous system infection.
- [14]. Kontoyiannis DP, Wessel VC, Bodey GP, Rolston KV. Zygomycosis in the 1990s in a tertiary-care cancer center. *Clinical Infectious Diseases*. 2000 Jun 1;30(6):851-6.
- [15]. Roden MM, Zaoutis TE, Buchanan WL, Knudsen TA, Sarkisova TA, Schaufele RL, Sein M, Sein T, Chiou CC, Chu JH, Kontoyiannis DP. Epidemiology and outcome of zygomycosis: a review of 929 reported cases. *Clinical infectious diseases*. 2005 Sep 1;41(5):634-53.
- [16]. McCarthy M, Rosengart A, Schuetz AN, Kontoyiannis DP, Walsh TJ. Mold infections of the central nervous system. *New England Journal of Medicine*. 2014 Jul 10;371(2):150-60.
- [17]. OCHIAI H, ISEDA T, MIYAHARA S, GOYA T, WAKISAKA S. Rhinocerebral Mucormycosis—Case Report—. *Neurologia medico-chirurgica*. 1993;33(6):373-6.
- [18]. Mantadakis E, Samonis G. Clinical presentation of zygomycosis. *Clinical Microbiology and Infection*. 2009 Oct;15:15-20.
- [19]. Honavar SG. Code mucor: guidelines for the diagnosis, staging and management of rhino-orbito-cerebral mucormycosis in the setting of COVID-19.
- [20]. Rupa V, Maheswaran S, Ebenezer J, Mathews SS. Current therapeutic protocols for chronic granulomatous fungal sinusitis. *Rhinology*. 2015 Jun 1;53(2):181-6.
- [21]. Chikley A, Ben-Ami R, Kontoyiannis DP. Mucormycosis of the central nervous system. *Journal of Fungi*. 2019 Sep;5(3):59.
- [22]. Cornely OA, Alastruey-Izquierdo A, Arenz D, Chen SC, Dannaoui E, Hochhegger B, Hoenigl M, Jensen HE, Lagrou K, Lewis RE, Mellinghoff SC. Global guideline for the diagnosis and management of mucormycosis: an initiative of the European Confederation of Medical Mycology in cooperation with the Mycoses Study Group Education and Research Consortium. *The Lancet infectious diseases*. 2019 Dec 1;19(12):e405-21.
- [23]. Cornely OA, Alastruey-Izquierdo A, Arenz D, Chen SC, Dannaoui E, Hochhegger B, Hoenigl M, Jensen HE, Lagrou K, Lewis RE, Mellinghoff SC. Global guideline for the diagnosis and management of mucormycosis: an initiative of the European Confederation of Medical Mycology in cooperation with the Mycoses Study Group Education and Research Consortium. *The Lancet infectious diseases*. 2019 Dec 1;19(12):e405-21.
- [24]. Lone PA, Wani NA, Jehangir M. Rhino-orbito-cerebral mucormycosis: Magnetic resonance imaging. *Indian Journal of Otolaryngology*. 2015 Jul 1;21(3):215.
- [25]. Parsi K, Itgampalli RK, Vittal R, Kumar A. Perineural spread of rhino-orbitocerebral mucormycosis caused by *Apophysomyces elegans*. *Annals of Indian Academy of Neurology*. 2013 Jul;16(3):414.
- [26]. Gaviani P, Schwartz RB, Hedley-Whyte ET, Ligon KL, Robicsek A, Schaefer P, Henson JW. Diffusion-weighted imaging of fungal cerebral infection. *American journal of Neuroradiology*. 2005 May 1;26(5):1115-21.
- [27]. Vaughan C, Bartolo A, Vallabh N, Leong SC. A meta-analysis of survival factors in rhino-orbital-cerebral mucormycosis—has anything changed in the past 20 years?. *Clinical Otolaryngology*. 2018 Dec;43(6):1454-64.
- [28]. Hamill RJ. Amphotericin B formulations: a comparative review of efficacy and toxicity. *Drugs*. 2013 Jun;73(9):919-34.
- [29]. Skiada A, Lass-Floerl C, Klimko N, Ibrahim A, Roilides E, Petrikos G. Challenges in the diagnosis and treatment of mucormycosis. *Medical mycology*. 2018 Apr 1;56(suppl_1):S93-101.
- [30]. Corzo-León DE, Chora-Hernández LD, Rodríguez-Zulueta AP, Walsh TJ. Diabetes mellitus as the major risk factor for mucormycosis in Mexico: Epidemiology, diagnosis, and outcomes of reported cases. *Medical mycology*. 2018 Jan 1;56(1):29-43.
- [31]. Gebremariam T, Lin L, Liu M, Kontoyiannis DP, French S, Edwards JE, Filler SG, Ibrahim AS. Bicarbonate correction of ketoacidosis alters host-pathogen interactions and alleviates mucormycosis. *The Journal of clinical investigation*. 2016 Jun 1;126(6):2280-94.
- [32]. Ceriello A. Hyperglycemia and COVID-19: What was known and what is really new?. *Diabetes research and clinical practice*. 2020 Sep 1;167.
- [33]. Sipsas NV, Gamaletsou MN, Anastasopoulou A, Kontoyiannis DP. Therapy of mucormycosis. *Journal of Fungi*. 2018 Sep;4(3):90.
- [34]. Reed C, Bryant R, Ibrahim AS, Edwards Jr J, Filler SG, Goldberg R, Spellberg B. Combination polyene-caspofungin treatment of rhino-orbital-cerebral mucormycosis. *Clinical Infectious Diseases*. 2008 Aug 1;47(3):364

Prof. Dr. K.V.V. Satyanarayana Murthy, et. al. "Neurosurgical Perspective in Covid-19 associated Rhino Orbital Cerebral Mucormycosis (ROCM): A Case series study in government general hospital, Guntur." *IOSR Journal of Dental and Medical Sciences (IOSR-JDMS)*, 21(06), 2022, pp. 34-39.