

## Diagnosis and Management of Ectopic Maxillary Canine

Salman Anjum, Arbab Anjum, Aiswareya G

1. Salman Anjum , Junior Resident, Department of Orthodontics and Dentofacial Orthopaedics, Dr.Z.A.Dental College, Aligarh Muslim University, Aligarh, India. E-mail address: salmananjum29@gmail.com
2. Arbab Anjum , Assistant professor , Department of Orthodontics and Dentofacial Orthopaedics, Dr.Z.A.Dental College, Aligarh Muslim University, Aligarh, India. E-mail address: arbab.anjum@gmail.com
3. Aiswareya G, Junior Resident, Department of Orthodontics and Dentofacial orthopaedics, Dr.Z.A.Dental College, Aligarh Muslim University, Aligarh, India. E-mail address: gaiswareya@gmail.com

### Abstract

Permanent maxillary canine are the most frequently impacted teeth next to third molar. Palatal impaction are more common than the buccal impaction. Early detection of these ectopically placed canine is crucial, so as to prevent several consequences such as adjacent root resorption particularly lateral incisors. With the advent of 3D CBCT the localization of impacted canine has become easier and accurate. Based on the radiographic evaluation, the severity of ectopically placed canine is assessed and appropriate treatment option is selected. The management alternatives are described in depth, as well as the indications for each treatment options based on scientific data. Finally, the unfavourable consequences of canine ectopia are discussed.

**Key words:** Ectopic canine, Impacted canine

Date of Submission: 20-05-2022

Date of Acceptance: 03-06-2022

### I. Introduction

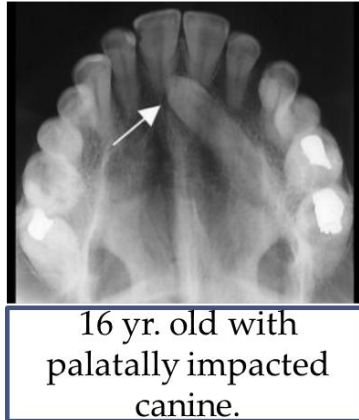
The quality of treatment outcomes relies on the proper diagnosis and selection of appropriate treatment plan. The maxillary permanent canines, after the third molars, are the teeth that are most commonly impacted. The prevalence has been estimated to be between 1.0 and 2.2 percent. Early diagnosis of ectopically placed canine in maxilla is critical because it permits the canine to be radiographically monitored, allowing for root resorption on surrounding incisors to be avoided. Rendering alternative treatment options entails an interactive process in which the clinician's knowledge and experience are backed up by scientific data. The aim of this paper is to look at the different methods of diagnosis and treatment plans against the available scientific data.

### ERUPTION SEQUENCE

At around 5 months of age, first evidence of calcification of the permanent maxillary cuspid is observed between the roots of the deciduous first molar, and is completed by 6-7 years of age. The deciduous first molar, the tooth germ of first premolar, and the canine lies in a row at around four years of age. Later growth on the maxilla's facial surface makes space for the canine to move forward, causing its cusp to come to rest mesial to the root of primary canine . According to Moss (1972), the canine lies above the root of lateral incisor until the crown is calcified. It subsequently erupts along the distal side, closing any physiological diastema that may exist and correcting the 'Ugly Duckling' dentition (1). It is particularly vulnerable to crowding (buccally placed or palatally placed or rotated) as it is the last tooth to erupt in the maxillary arch .

### II. Causes Of Ectopic Canine

The cause of an impacted maxillary canine is unknown, however it is most likely complex. In the permanent dentition, it has the longest path of eruption, which could be considered as a etiology for its ectopic position (2,3). Crowding is considered as a factor in labially impacted canine but not for palatal impaction (4). Other causes include Pathological lesions, Odontomes, Ankylosis, Supernumerary teeth and cleft lip and palate. In his study, Jacoby (1983) discovered that sufficient space was available in the arch in 85 percent of cases with palatally erupted canine. Excessive space in the canine area was suggested to be the cause of canine impaction (Fig:1).



**Fig:1**

Trauma in the anterior segment of maxilla at a young age has also been postulated as a cause of palatal impaction (5). Studies have demonstrated that patients with missing or peg-shaped lateral incisors had a higher incidence of palatally impacted canines (6). This can be explained on the basis of 'Guidance Theory'. According to this theory, the canine erupts safely into its position along the distal aspect of lateral incisors root as it act as a guide for canine eruption. This guidance is lost if the lateral incisor is abnormal or missing, causing the canine to be palatally displaced. It was speculated that the lateral incisor's root was not fully grown at the period when it was most crucial for canine guidance. In a study of 31 Causacian participants, it was observed that lateral incisors were rudimentary in size on the side of canine impaction when compared with the contralateral side with no canine impaction (7). Study by Mossey et al, Brenchley et al contradicts the above observation stating that there is no relation between abnormal lateral incisors and ectopic canine (8,9). Prolonged retention of the deciduous canine may result in the permanent successor's palatal movement. On the other hand, the delayed exfoliation of a deciduous canine was considered to be a result rather than a cause (4).

#### **LOCALIZATION OF THE MAXILLARY CUSPID**

The position of the crown of the lateral incisor can reveal the position of the unerupted canine; for example, the crown of the lateral incisors may be proclined if the canine is placed on the labial aspect of the root of the lateral incisors (10). If the canine is not palpable in the buccal sulcus by the age of 10–11 years, clinicians should be concerned of canine ectopia. From the age of eight years, annual examination of the canine region is recommended (11). If there is a deviated path of eruption as confirmed by palpation, delay in the eruption of lateral incisors or its crown tipped labially, peg shaped or missing lateral incisors, if there is a family history of ectopic canines, then in all above mentioned conditions, radiographic investigation are recommended before 11 years of age.

All persons with unerupted and non-palpable canines beyond the age of 11-12 years should be evaluated with radiographs. A combination of radiographs are taken for the diagnosis of ectopic maxillary canine. A method for localizing canines using computed tomography (CT) has been described (12,13). An orthopantomogram or lateral cephalogram can also be used to determine the canine's vertical position. These radiographs will aid in determining the location of canine in the maxillary arch, and also its angulation, height, and mesiodistal position (14,15). The use of MRI and scanoratomography in the diagnosis of the canine impaction is another advancement (16). The use of CBCT imaging to determine ectopic maxillary canines is the most modern and accurate procedure. Pamela et al concluded that there is no correlation between various clinical variables and canine impaction. Therefore other parameters such as genetics and molecular factors need further investigation (17).

#### **TREATMENT CONSIDERATIONS**

The ectopic maxillary canine generally necessitates a multidisciplinary approach comprising oral surgery, restorative dentistry, periodontics, and orthodontics (18). Management of ectopic maxillary canine includes a thorough examination in order to locate the canine and determine its prognosis followed by assessment of canine's position in three dimensions. When used appropriately, interceptive methods are more cost-effective than other, more invasive procedures. To avoid medicolegal issues, all the treatment alternatives must be well explained to the patient and informed permission is required (19).

### **INTERCEPTIVE TREATMENT**

Ericson and Kuroi (1988) conducted a research on a sample of children with mean age of 11.4 yrs with palatally placed canines in uncrowded arches. After the extraction of deciduous canine, they discovered that 78% of the permanent canines restored to a normal eruption path. Study on the impact of removing deciduous canines on the emergence of the permanent canine showed 19% good results (20). The findings revealed that crowding prevents the permanent canine from erupting. The most important component was determined to be the horizontal placement of the canine over the adjacent incisor. Based on the findings of these research, it seems reasonable to advocate primary canine extraction as a preventive strategy in the patients of 10–13 years of age with non-palpable maxillary canine and with the radiographic diagnosis of palatal canine ectopia. (1,12,16) and also in cases where alternative treatment is recommended if the canine position does not improve after 12 months on the OPG. Clinical review and follow-up radiographs has to be done for every six months (1). Naoumova et al in his study stated that alpha angle and sector position as the good prognostic determinants for the interceptive extraction of primary canine. He also mentioned that interceptive primary canine extraction is advantageous if the alpha angle is between 20 to 30 degrees and located in sector 2-3.(21)

### **EXPOSURE WITH OR WITHOUT ORTHODONTIC TRACTION**

Surgical exposure and orthodontic traction are the most common treatments for impacted canines. The patient age, amount of discrepancy and the exact three dimensional location of the canine crown and root all have a role in the prognosis for alignment. The prognosis for alignment diminishes if the canine's inclination is more than 45 degrees with respect to the midline. If the canine lies close to the midline, the prognosis of the same gets worse. Also the tooth should be evaluated for ankylosis and the root dilaceration for proper alignment. The longer distance the canine must be relocated, the lower the chance of a favourable outcome. It is critical to have a good buccal overlap and proper root positioning in order to achieve a stable outcome (Zachrisson and Thilander). Because the treatment duration in these circumstances is often prolonged, the patient's cooperation and motivation are essential, as they are with any orthodontic treatments (22,23).

### **PALATAL ECTOPIC CANINES**

There are three basic strategies for exposing and aligning the canine.

1. Spontaneous eruption after open surgical exposure.
2. An auxiliary is bonded after an open surgical exposure and packing.
3. Intraoperative attachment bonding and closed surgical exposure.

When the canine has the proper inclination, the first approach is likely to be the most effective, as the canine will erupt spontaneously. Kinan et al concluded from his study that the palatal canine impaction is severe when the apex is in more distal position and the cusp tip is more mesially positioned (24).The canine can be exposed with packing as the second alternative. A week after surgery, an attachment is bonded to the canine crown followed by orthodontic traction. There are some indication that your periodontal health is in jeopardy (25). This evidence is inconclusive, and a randomised controlled clinical trial is currently being conducted .The closed technique is the third choice. A palatal mucoperiosteal flap is reflected in this procedure. An eyelet wire or gold chain from an attachment that is bonded to the crown of the tooth to the fixed appliance for quick traction (Becker et al). This technique, however, has the drawback of requiring re-exposure if bond failure occurs. Becker et al. recommend using an eyelet bonded to the crown of the impacted canine at the middle third of its buccal surface during surgery because it increases the success rate. Autotransplantation is one of the treatment alternative that can be done as a last resort of ectopically placed canine with complete root formation. In this procedure, the space for canine was created orthodontically then tooth socket was prepared using implant drills. After autotransplantation the bony defects were corrected using guided tissue regeneration. In a four year follow up study by Zufia et al, the transplanted maxillary canine had stable soft tissue level with no incidence of root resorption.(26)

### **BIOMECHANICAL CONSIDERATIONS**

To align the canine, lighter forces in the range of 20–60 g has to be used (27). Various procedures for aligning the canine have been documented, and Hunter, Kokich, and Matthews describe them in detail. To provide vertical anchorage transpalatal bar and/or headgear is used . It is critical to provide and maintain appropriate space in the canine area. Force can be applied through elastic or wire traction.According to Usiskin , the gold chain can be used to apply traction of impacted canine. The canine is pulled away from the lateral incisor using a palatal arch with soldered hooks to apply traction (28). Jacoby (1979) describes the use of Ballista spring for canine traction (29). Sectional approach can also be employed with a transpalatal arch for anchorage. From the first molar to the canine, they utilise a 0017- by 0025-inch TMA sectional archwire that provides a low force over a long range. Bennett described the use of a wound on auxiliary to attain vertical

movement first followed by lateral movement. The use of magnetic forces have been suggested by some authors for the management of ectopic canine (30,31).

#### **CONSIDERATIONS TO PREVENT RELAPSE FOLLOWING TREATMENT (BY MCLAUGHLIN AND BENNET)**

1. Complete torque correction.
2. Correction of rotations at early stages followed by supracrestal fibrotomy to prevent relapse.
3. Bonded retainer following orthodontic treatment.

Surgical exposure and orthodontic alignment of maxillary canine is done when:

1. The patient is co-operative and are well motivated.
2. Preventive measures are ineffective.
3. The degree of malposition is not severe for orthodontic treatment. The ectopic canine's long axis should not be too horizontal or oblique. The worse the prognosis for alignment if the crown of tooth lies close to the midline and the root to the median-palatal suture (Kuroi et al., 1997)

#### **BUCCALLY ECTOPIC CANINES**

Buccal/labial impaction is much less frequent than palatal impaction occurring in only 15 per cent of cases. When a buccally ectopic canine is exposed it is essential that an apically repositioned flap be used to preserve the attached gingiva. Vermette et al. examined the use of the apically repositioned flap versus the closed technique, and found that the former technique resulted in unaesthetic sequelae than the closed technique (32).

#### **NO ACTIVE TREATMENT**

In rare circumstances, it may be desirable to avoid active treatment, opting instead for routine radiographic monitoring. No active treatment can be indicated if the patient refuses active treatment, lack of resorption of adjacent teeth, there is good contact between the lateral incisor and 1st premolar, or the deciduous canine has a good prognosis.

#### **SURGICAL REMOVAL OF ECTOPIC MAXILLARY CANINE**

The surgical intervention of ectopic canines is preferred under following circumstances :

- i. Patient refuses active treatment and/or is satisfied with his or her appearance.
- ii. Neighbouring teeth resorption is noticed at an early stage.
- iii. Interception is not possible since the patient is too elderly.
- iv. The lateral incisor and first premolar make good contact, or the patient is eager to undergo orthodontic treatment to replace the canine with the first premolar.
- v. Surgical repositioning/transplantation is not an option because to the severity of the malposition..

#### **COMPLICATIONS OF CANINE ECTOPIA**

The most prevalent complication of canine ectopia is neighbouring teeth internal/external root resorption. Root resorption of adjacent lateral incisor typically occurs at the mid root level, than at the cervical or apical root level. As a result of canine ectopia, it is found that 7% of children have their incisors resorbed. In roughly 12.5% of the incisors close to ectopic maxillary canines, root resorption is expected. Finally, the unerupted canine itself may undergo late resorption. Follicular cystic degeneration also appears to be the common consequence, while its prevalence is unknown. Ericson et al in his study stated that , the follicular size of ectopic canine was found to be 2.7 to 3.2 mm which is greater than that of normally erupting canine (2.3 to 2.7 mm) (33).

### **III. Conclusion**

Proper diagnosis, treatment planning and timely intervention of impacted or ectopic maxillary canine is essential to avoid the sequelae of canine ectopia such as adjacent tooth resorption, unpleasant smile due to retained deciduous canine and follicular cystic degeneration.

#### **References**

- [1]. Ericson S, Kuroi J. Early treatment of palatally erupting maxillary canines by extraction of the primary canines. *Eur J Orthod.* 1988 Nov;10(4):283-95. PMID: 3208843.
- [2]. Coulter J, Richardson A. Normal eruption of the maxillary canine quantified in three dimensions. *Eur J Orthod.* 1997 Apr;19(2):171-83.
- [3]. Jacoby H. The etiology of maxillary canine impactions. *Am J Orthod.* 1983 Aug;84(2):125-32. doi: 10.1016/0002-9416(83)90176-8. PMID: 6576636.
- [4]. Thilander, B. and Jacobsson, S.O. Local factors in impaction of maxillary canines, *Acta Odontologica Scandinavica*,1968. 26,145–168.

- [5]. Brin I, Becker A, Zilberman Y. Resorbed lateral incisors adjacent to impacted canines have normal crown size. *Am J Orthod Dentofacial Orthop.* 1993 Jul;104(1):60-6. doi: 10.1016/0889-5406(93)70028-M. PMID: 8322724
- [6]. Becker et al. Root Length of Lateral Incisors adjacent to Palatally-displaced Maxillary cuspids. *Angle Orthod* (1984) 54 (3): 218–225.
- [7]. Oliver RG, Mannion JE, Robinson JM. Morphology of the Maxillary Lateral Incisor in Cases of Unilateral Impaction of the Maxillary Canine. *British Journal of Orthodontics.* 1989;16(1):9-16. doi:10.1179/bjo.16.1.9
- [8]. Mossey PA, Campbell HM, Luffingham JK. The Palatal Canine and the Adjacent Lateral Incisor: A Study of a West of Scotland Population. *British Journal of Orthodontics.* 1994;21(2):169-174.
- [9]. Brenchley Z, Oliver RG. Morphology of Anterior Teeth Associated with Displaced Canines. *British Journal of Orthodontics.* 1997;24(1):41-45.
- [10]. Bishara SE, Kommer DD, McNeil MH, Montagano LN, Oesterle LJ, Youngquist HW. Management of impacted canines. *Am J Orthod.* 1976 Apr;69(4):371-87. doi: 10.1016/0002-9416(76)90207-4. PMID: 1062935.
- [11]. Ericson S, Kuroi J. Radiographic assessment of maxillary canine eruption in children with clinical signs of eruption disturbance. *Eur J Orthod.* 1986 Aug;8(3):133-40. doi: 10.1093/ejo/8.3.133. PMID: 3464436.
- [12]. Ericson, S. and Kuroi, J. (1988b) CT diagnosis of ectopically erupting maxillary canines-a case report, *European Journal of Orthodontics*, **10**, 115–120.
- [13]. Schmuth, G. P., Freisfeil, M., Koster, O. and Schuller, H. (1992) The application of computerized tomography (CT) in cases of impacted maxillary canines, *European Journal of Orthodontics*, **14**, 296–301.
- [14]. Southall, P. and Gravely, J. (1987) Radiographic localization of unerupted teeth in the anterior part of the maxilla: a survey of the methods currently employed, *British Journal of Orthodontics*, **14**, 235–242.
- [15]. Fox, N. A., Fletcher, G. A. and Horner, K. (1995) Localizing maxillary canines using dental panoramic radiography, *British Dental Journal*, **179**, 416–420.
- [16]. Kuroi, J., Ericson, S. and Andreasen, J. O. (1997) The impacted maxillary canine, In: *Textbook and Color Atlas of Tooth Impactions*, (ed. Andreasen, J. O.) Munksgaard, Copenhagen, pp. 124-164
- [17]. Uribe P, Ransjö M, Westerlund A. Clinical predictors of maxillary canine impaction: a novel approach using multivariate analysis. *Eur J Orthod.* 2017 Apr 1;39(2):153-160. doi: 10.1093/ejo/cjw042. PMID: 27179354.
- [18]. Bishara, S. (1994) Impacted maxillary canines: a review, *American Journal of Orthodontics and Dentofacial Orthopedics*, **101**, 159–171.
- [19]. Machen, D. E. (1989) Legal aspects of orthodontic practice: risk management concepts. The impacted canine, *American Journal of Orthodontics and Dentofacial Orthopedics*, **96**, 270–271.
- [20]. Power, S. M. and Short, M. B. E. (1993) An investigation into the response of palatally displaced canines to the removal of deciduous canines and an assessment of factors contributing to favourable eruption, *British Journal of Orthodontics*, **20**, 215–223.
- [21]. Naoumova J, Kjellberg H. The use of panoramic radiographs to decide when interceptive extraction is beneficial in children with palatally displaced canines based on a randomized clinical trial. *Eur J Orthod.* 2018 Nov 30;40(6):565-574. PMID: 29462471.
- [22]. Altonen, M. and Myllarniemi, S. (1976) Results of surgical exposure of impacted cuspids and bicuspid in relation to patients' somatic and dental maturation, *International Journal of Oral Surgery*, **5**, 180–186.
- [23]. Galloway, I. and Stirrups, D. R. (1989) The effect of age at diagnosis on complexity and outcome of treatment of palatally ectopic canines, *British Journal of Orthodontics*, **16**, 87–92.
- [24]. Zeno KG, Ghafari JG. Palatally impacted canines: A new 3-dimensional assessment of severity based on treatment objective. *Am J Orthod Dentofacial Orthop.* 2018 Mar;153(3):387-395. PMID: 29501114.
- [25]. Kohavi, D., Becker, A. and Zilbermann, Y. (1984) Surgical exposure, orthodontic movement and final tooth position as factors in periodontal breakdown of treated palatally impacted canines, *American Journal of Orthodontics*, **85**, 72–77.
- [26]. Zuffa J, Abella F, Gómez-Meda R, Blanco H, Roig M. Autotransplantation of impacted maxillary canines into surgically modified sockets and orthodontic treatment: a 4-year follow-up case report. *Int J Esthet Dent.* 2020;15(2):196-210. PMID: 32467948.
- [27]. Kuftinec, M. M., Stom, D. and Shapira, Y. (1995) The impacted maxillary canine. II. Clinical approaches and solutions, *Journal of Dentistry for Children*, **52**, 325–340.
- [28]. Usiskin, L. A. (1991) Management of the palatal ectopic and unerupted maxillary canine, *British Journal of Orthodontics*, **18**, 339–346.
- [29]. Jacoby, H. (1979) The 'Ballista Spring' system for impacted teeth, *American Journal of Orthodontics*, **75**, 143–151.
- [30]. Sandler, P. J., Meghji, S., Murray, A. M., Springate, S. D., Sandy, J. R., Crow, V. and Reed, R. T. (1989) Magnets and orthodontics, *British Journal of Orthodontics*, **16**, 243–249.
- [31]. Darendeliler, M. A. and Friedli, J. M. (1994) Case report. Treatment of an impacted canine with magnets, *Journal of Clinical Orthodontics*, **28**, 639–643.
- [32]. Vermette, M. E., Kokich, V. G. and Kennedy, D. B. (1995) Uncovering labially impacted teeth: apically positioned flap and closed eruption techniques, *Angle Orthodontist*, **65**, 23–32.
- [33]. Ericson S, Bjerklín K. The dental follicle in normally and ectopically erupting maxillary canines: a computed tomography study. *Angle Orthod.* 2001 Oct;71(5):333-42. PMID: 11605866.

Salman Anjum, et. al. “Diagnosis and Management of Ectopic Maxillary Canine”. *IOSR Journal of Dental and Medical Sciences (IOSR-JDMS)*, 21(06), 2022, pp. 06-10.