

Pectoral nerve block (Pecs block) with monitored anesthesia care for breast surgeries without general anesthesia

Dr. Ankit Godara, Dr. Swati Singh

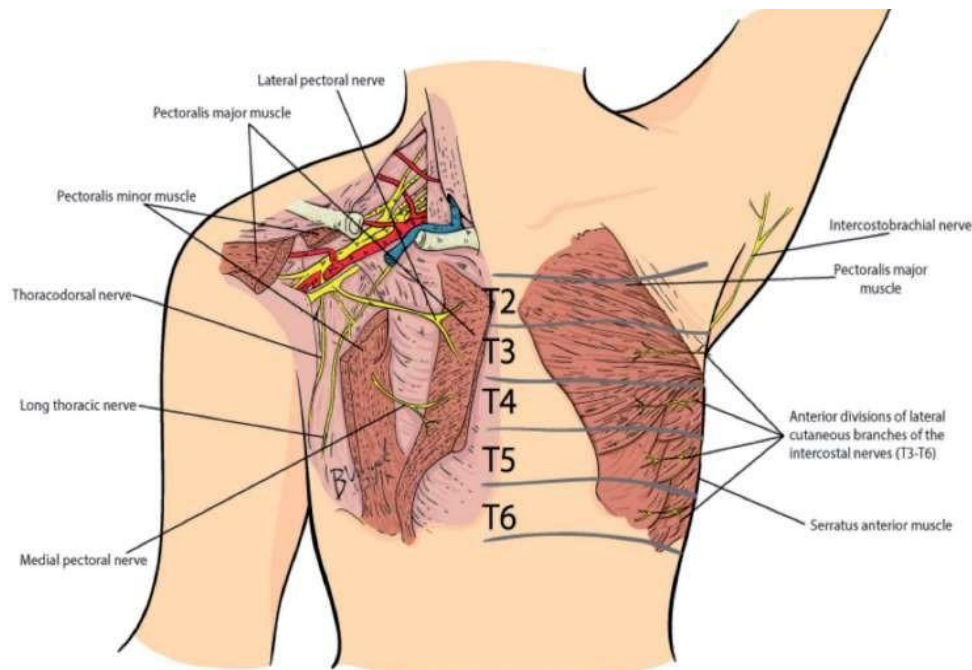
MAHATMA GANDHI UNIVERSITY OF MEDICAL SCIENCES AND TECHNOLOGY, JAIPUR

Date of Submission: 15-05-2022

Date of Acceptance: 30-05-2022

I. Introduction

- The growing increase in the number of breast surgeries has resulted in an increased need for anesthetic techniques with improved pain reduction, safety, and fewer complications.
- The regional anesthesia technique like Pecs block is employed for postoperative pain management in breast surgeries under general anesthesia, and not as the primary anesthesia ^[1].
- Since 2011, Blanco and his colleagues, described two new ultrasound-guided thoracic wall blocks ^[2,3].
- First, they described a technique to inject local anesthetic agents in between the pectoralis major and minor muscles, which they successfully performed in 50 patients requiring analgesia after breast surgery ^[2].
- One year later, Blanco et al. described a modified version of this technique where they additionally injected local anesthetic agents between the pectoralis minor and serratus muscle ^[3].
- Upon introduction of the second block, Blanco et al labeled the first block the Pecs I (pectoral nerve block type I) and the second technique Pecs II.
- The Pecs I block aims at providing analgesia for breast surgery by blocking the medial and lateral pectoral nerves ^[3,4]. Pecs II additionally blocks the axilla by targeting at least the intercosto brachial, III to VI intercostals, and the long thoracic nerves ^[3,4].



- Regional anesthesia techniques, such as thoracic epidural block, thoracic paravertebral block (TPVB), and intercostal nerve block, have been used in anesthesia and/or analgesia in breast surgery ^[1].

- Pectoral nerve block is a relatively new technique and is less invasive and has less complications, as compared to the other procedures. It is a novel superficial nerve block, alternative to neuraxial and paravertebral blocks, which provides good analgesia during and after ambulatory breast surgery^[5].
- In Previous studies, Pecs block were performed under GA for postoperative pain management and not as a primary anesthesia in breast surgeries^[1].
- In this study, we have given Pecs block along with (MAC) in a patients who underwent breast surgery, to assess the quality of block, surgeon and patient compliance, better outcomes in terms of reduced postoperative pain and avoiding complications related to G.A.

Aim & Objective

Aim -

- To assess the quality of PECS block as primary anesthesia (without G.A) in patients who underwent breast surgeries with monitored anesthesia care. Objectives -
- Average duration to perform block.
- Average duration to achieve surgical analgesia.
- Total number of cases which were converted to G.A.
- Patient and surgeon compliance.
- Average time duration to give first postoperative analgesic.

Type of Study - Descriptive Case Series

Place of Study - It was performed in Anaesthesiology Department MGMCH, Jaipur from December 2017 to 15th March 2018 after the approval of ethical committee.

Inclusion Criteria - 10 female patients of age 20-50 years planned for unilateral breast surgeries were included in this study.

Exclusion criteria -

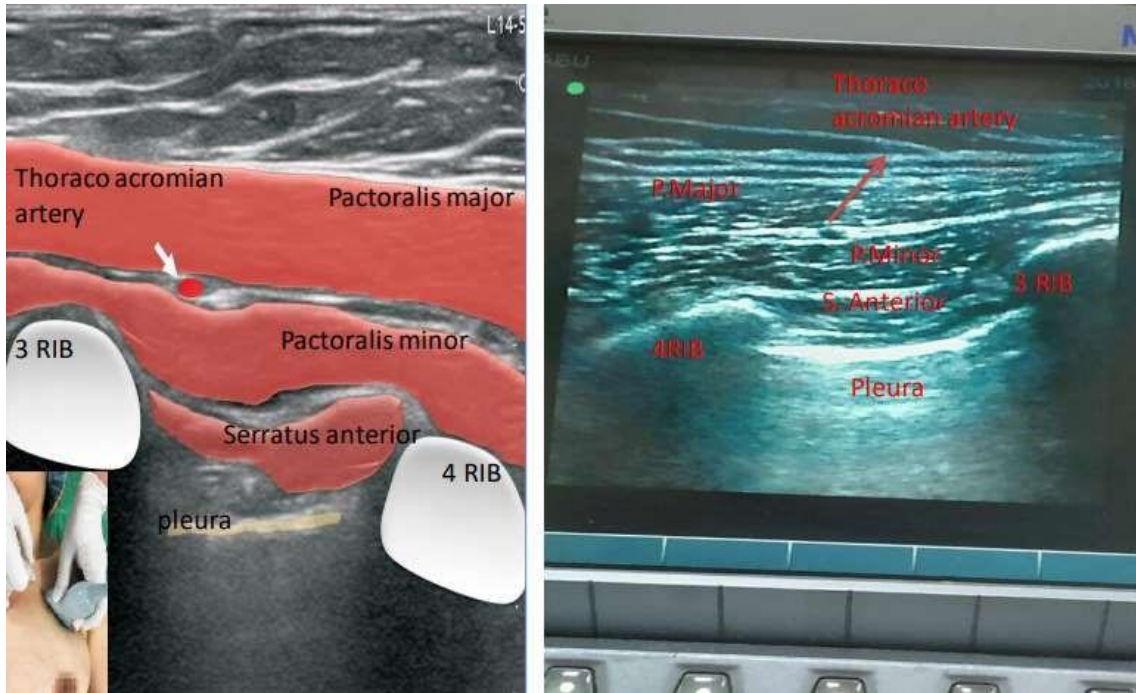
- Patient not giving consent
- allergy to local anesthetic
- deranged coagulation profile
- infection at injection site
- Patients > ASA grade 2
- Weight less than 50 kg

Methods

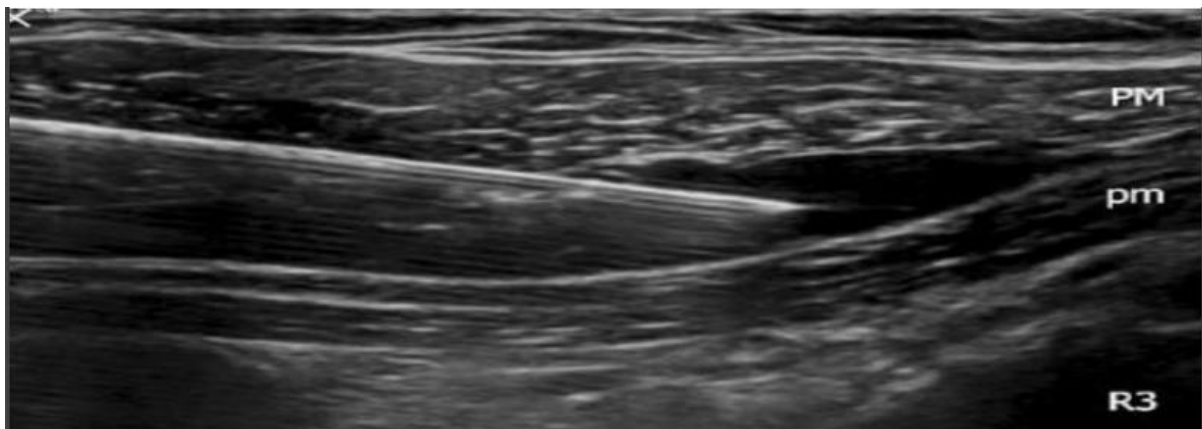
- All routine preoperative investigations were done.
- 18 G intracath was taken on nondominant hand.
- ECG, NIBP, SPO2 was monitored.
- Patients were given 1mg midazolam i.v as premedication.

Technique

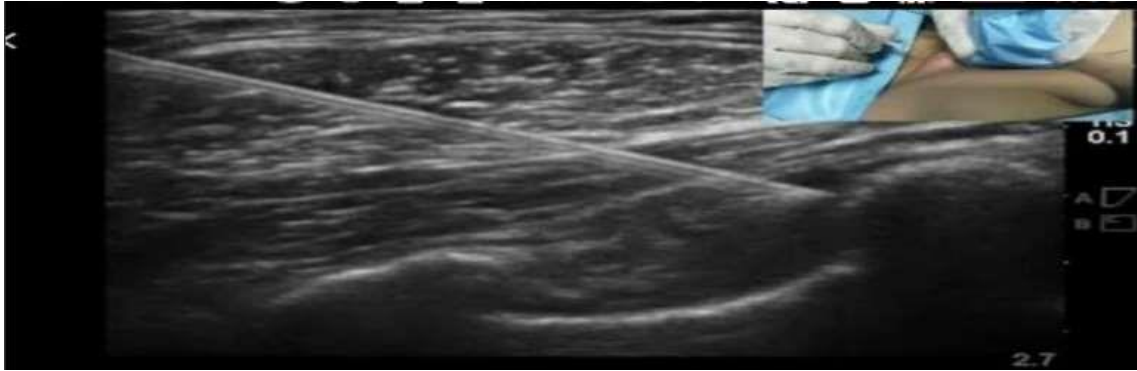
- After recognition of the appropriate anatomical structures, the skin puncture point was infiltrated with 2ml of 2% lidocaine. The block was performed using a medial in-plane approach with a 25-G spinal needle.
- After recognition of the appropriate anatomical structures, the skin puncture point was infiltrated with 2ml of 2% lidocaine. The block was performed using a medial in-plane approach with a 25-G spinal needle.



- Local anesthetic mixture of 30 ml was prepared by adding 10ml of 2% lignocaine with 20 ml of 0.5% Ropivacaine.
- For Pecs I block, the needle was advanced to the tissue plane between the pectoralis major muscle and pectoralis minor muscle at the vicinity of the pectoral branch of the acromiothoracic artery and 10 mL of local anesthetic solution.



- For Pecs II block, 20 mL was deposited at the level of the third rib above the serratus anterior muscle with intent to spread the local anesthetics over the axilla. We confirmed the anesthetic area over T2–T6 of dermatomes by a pinprick test.



- Subsequently, dexmedetomidine was infused with a loading dose of 1 mcg/kg for 10 minutes, followed by a maintenance dose of 0.2–0.7 mcg/kg/h with titration, for targeting Ramsay sedation score of 3, responding to verbal commands.

II. Results

Average time to perform block –

CASE 1 giant fibroadenoma excision	11 mins
CASE 2 multiple fibroadenoma excision	16 mins
CASE 3 intraductal carcinoma(MRM)	13 mins
CASE 4 breast implant	14 mins
CASE 5 breast conserving surgery	18 mins
CASE 6 fibroadenoma excision	10 mins
CASE 7 microdoectomy	16 mins
CASE 8 abscess (I and D)	18 mins
CASE 9 multiple fibroadenoma excision	14 mins
CASE 10 secondary suturing post MRM	12 mins
AVERAGE DURATION	14.2 mins

Average duration to achieve surgical analgesia –

CASE 1 giant fibroadenoma excision	18 mins
CASE 2 multiple fibroadenoma excision	16 mins
CASE 3 intraductal carcinoma(MRM)	20 mins
CASE 4 breast implant	14 mins
CASE 5 breast conserving surgery	18 mins
CASE 6 fibroadenoma excision	13 mins
CASE 7 microdoectomy	16 mins
CASE 8 abscess (I and D)	18 mins
CASE 9 multiple fibroadenoma excision	14 mins
CASE 10 secondary suturing post MRM	22 mins
AVERAGE DURATION	16.9 mins

Total number of cases which were converted to G.A. –

Out of 10 cases two were converted into G.A because they became apprehensive.

Patient and surgeon compliance

- Out of 10 patients except two, rest eight reported as a pleasant experience.
- The intensity of the block was adequate to permit surgical excision and exploration and the surgeon was completely satisfied with the effect of block.
- No complication was seen related to block in any patient

Average time duration to give first postoperative analgesia

CASE 1 giant fibroadenoma excision	6 hrs
CASE 2 multiple fibroadenoma excision	9 hrs
CASE 3 intraductal carcinoma(MRM)	4 hrs
CASE 4 breast implant	10 hrs
CASE 5 breast conserving surgery	5 hrs
CASE 6 fibroadenoma excision	8 hrs
CASE 7 microdochectomy	9 hrs
CASE 8 abscess (I and D)	14 hrs
CASE 9 multiple fibroadenoma excision	7 hrs
CASE 10 secondary suturing post MRM	8 hrs
AVERAGE DURATION	8 hrs

III. Discussion

- Three studies assessed the impact of Pecs II when added with G.A to a control group which did not receive a regional anesthesia technique^[1,6,7]. They reported significantly lower postoperative pain scores during the first 24 hours in pecs group, results are comparable with our study.
- Eldeen and Kulhari et al identified a significantly longer sensory block duration of the Pecs II block as compared the thoracic spinal block (994 vs. 382 min), results are comparable to our study^[9,10].
- Wabha et al. showed, that the time for first request of morphine was longer in their Pecs block group than their paravertebral block (175 vs. 137.5 min) where as in our study it was 480 minutes^[11,12].
- Four studies reported not to have encountered any Pecs block related complications^[9,10,11,12]. Results are comparable to our study.

IV. Conclusion

- In previous studies, Pecs block has been performed for postoperative pain management under general anesthesia (GA) and not as a primary anesthesia in breast surgeries.
- However, in present study Pecs block, when conducted in combination with monitored anesthesia care (MAC), it could suffice as primary anesthesia with better outcomes in terms of reducing postoperative pain and avoiding complications related to G.A.

References

- [1]. Bashandy GM, Abbas DN. Pectoral nerves I and II blocks in multimodal analgesia for breast cancer surgery: a randomized clinical trial. *Reg Anesth Pain Med* 2015; 40:68-74.
- [2]. Blanco R. The “pecs block”: a novel technique for providing analgesia after breast surgery. *Anaesthesia*, 66: 847-848, 2011.
- [3]. Blanco R, Fajardo M, Parras Maldonado T. Ultrasound description of Pecs II (modified
- [4]. Pecs I): a novel approach to breast surgery. *Rev Esp Anesthesiol Reanim*, 59 : 470-475, 2012.4 Bolin ED, Harvey NR, Wilson Bolin ED, Harvey NR, Wilson SH. Regional Anesthesia for Breast Surgery: Techniques and Benefits. *CurrAnesthesiol Rep*, 5: 217-224, 2015.
- [6]. Blanco R, Parras T, McDonnell JG, Prats-Galino A. Serratus plane block: A novel ultrasound-guided thoracic wall nerve block. *Anaesthesia* 2013; 68:1107-13.
- [7]. Morioka H, Kamiya Y, Yoshida T, Baba H. Pectoral nerve block combined with general anesthesia for breast cancer surgery: a retrospective comparison. *JA Clin Rep*, 1: 1-5, 2015.
- [8]. Ali Hassn A, Zanfaly H, Biomy T. Pre-emptive analgesia of ultrasound-guided pectoral nerve block II with dexmedetomidine-bupivacaine for controlling chronic pain after modified radical mastectomy. *Res Opin Anesth Intensive Care*, 3:6-13, 2016.

- [9]. Wu CL, Raja SN. Treatment of acute postoperative pain. *The Lancet*, 377: 2215-2225, 2011.
- [10]. Eldeen HM. Ultrasound guided pectoral nerve block adersusthoracic spinal blockade for conservative breast surgery in cancer breast: A randomized controlled trial *Egypt J Anaesth* 2015.
- [11]. Kulhari S Bharti N, Bala I, Arora S, Singh G. Efficacy of pectoral nerve block versus thoracic paravertebral block for postoperative analgesia after radical mastectomy: a randomized controlled trial. *Br J Anaesth*, 117 : 382-386
- [12]. Wahba SS, Kamal SM. Thoracic paravertebral block versus pectoral nerve block for analgesia after breast surgery. *Egypt J Anaesth*, 30: 129-135, 2014.
- [13]. Ali Hassn A, ZanfalyH, Biomy T. Pre-emptive analgesia of ultrasound-guided pectoral nerve block II with dexmedetomidine-bupivacaine for controlling chronic pain after modified radical mastectomy. *Res Opin Anesth Intensive Care*, 3:6-13, 2016.

Dr. Ankit Godara, et. al. "Pectoral nerve block (Pecs block) with monitored anesthesia care for breast surgeries without general anesthesia". *IOSR Journal of Dental and Medical Sciences (IOSR-JDMS)*, 21(05), 2022, pp. 12-17.